

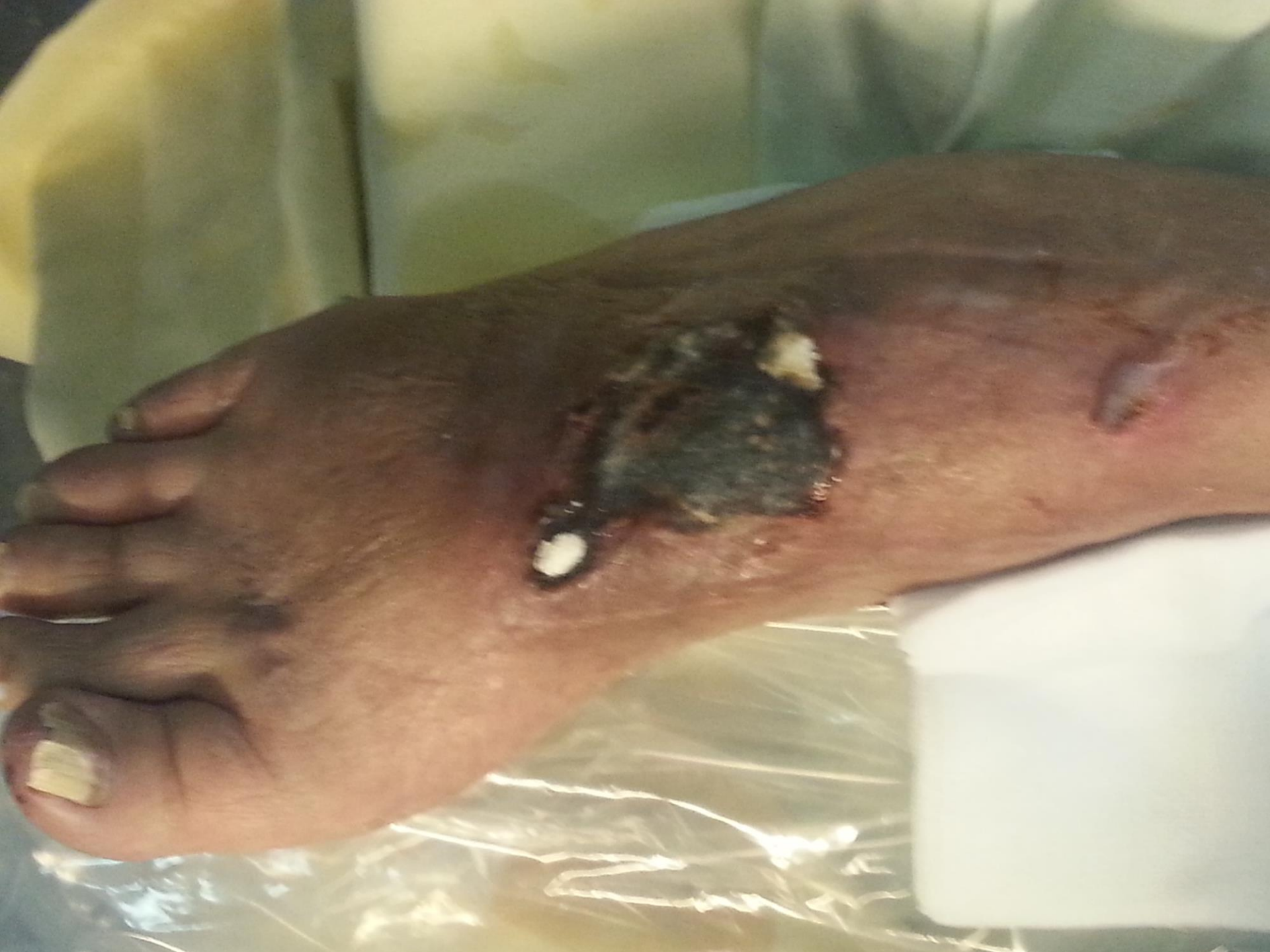
# 68-year-old woman presented CLI of the right limb

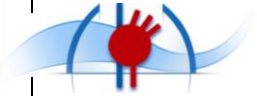**Y. Gouëffic, MD, PhD**

Department of vascular surgery  
Institut du Thorax, Nantes, France

**l'institut du thorax**







## **Clinical history:**

- Peripheral arterial disease
- Coronary artery disease and myocardial infarction
- Renal failure and hemodialysis (30 years)
- Left hand amputation (arteriopathy)

## **Cardiovascular risk factors:**

- Hypertension

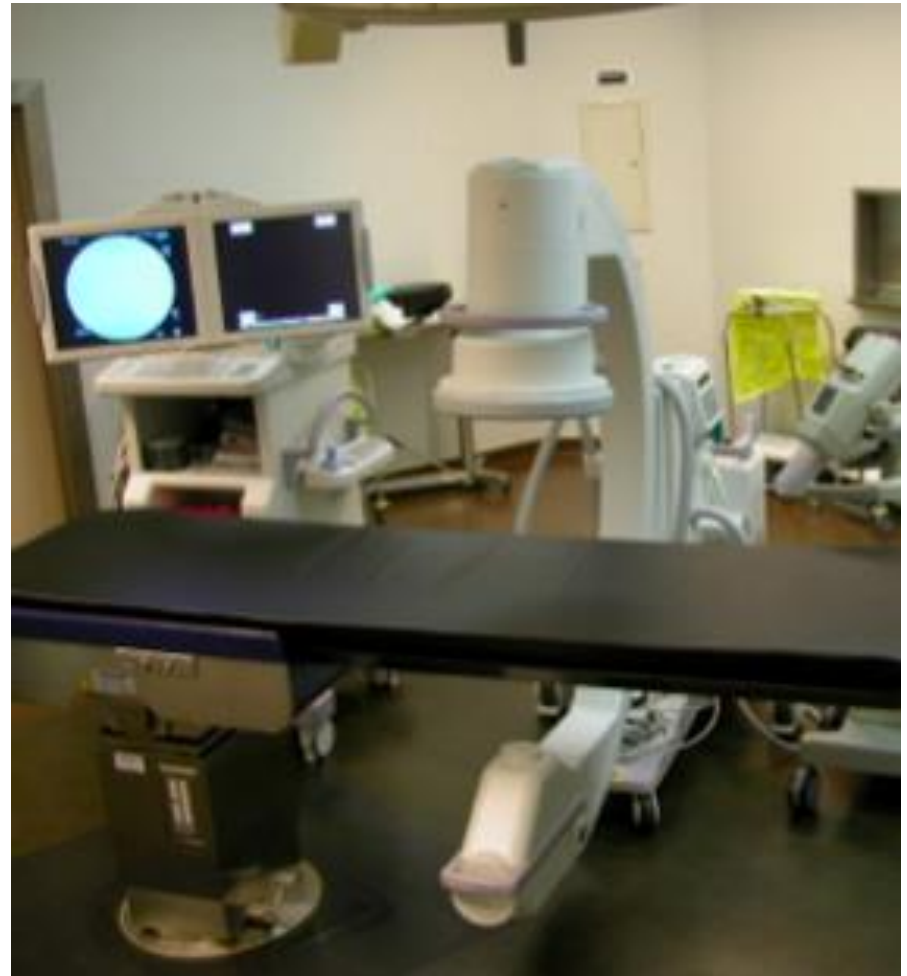## **Duplex scan**

Non-contributory



- Ischemic rest pain of the right foot
- Symptomatology had started 3 weeks ago

Arteriography

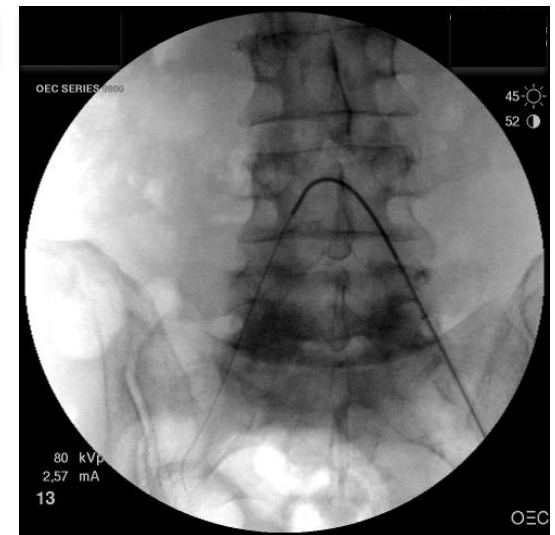
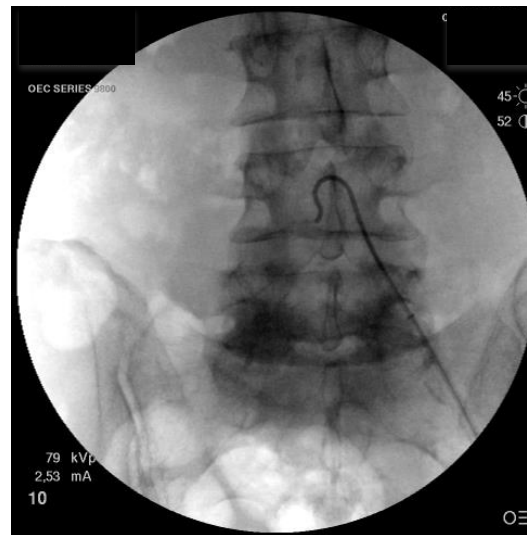
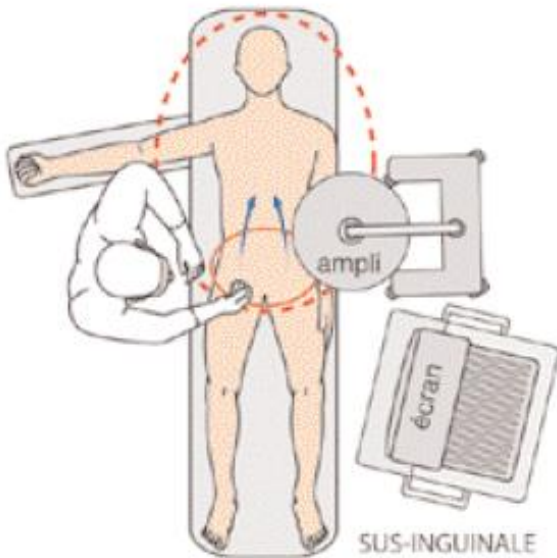


# Retrograde approche

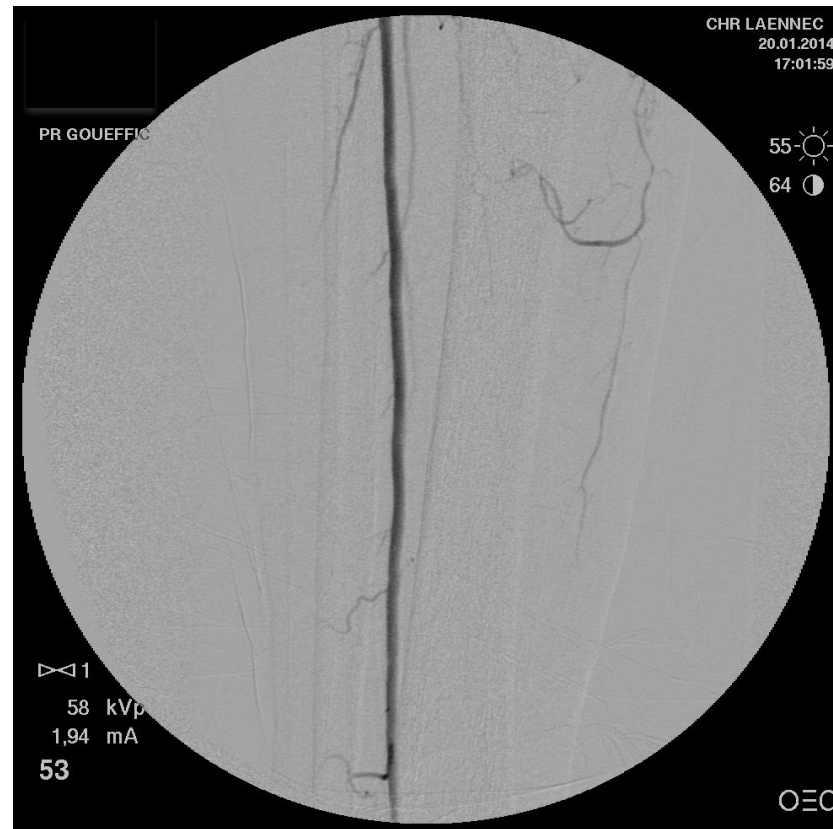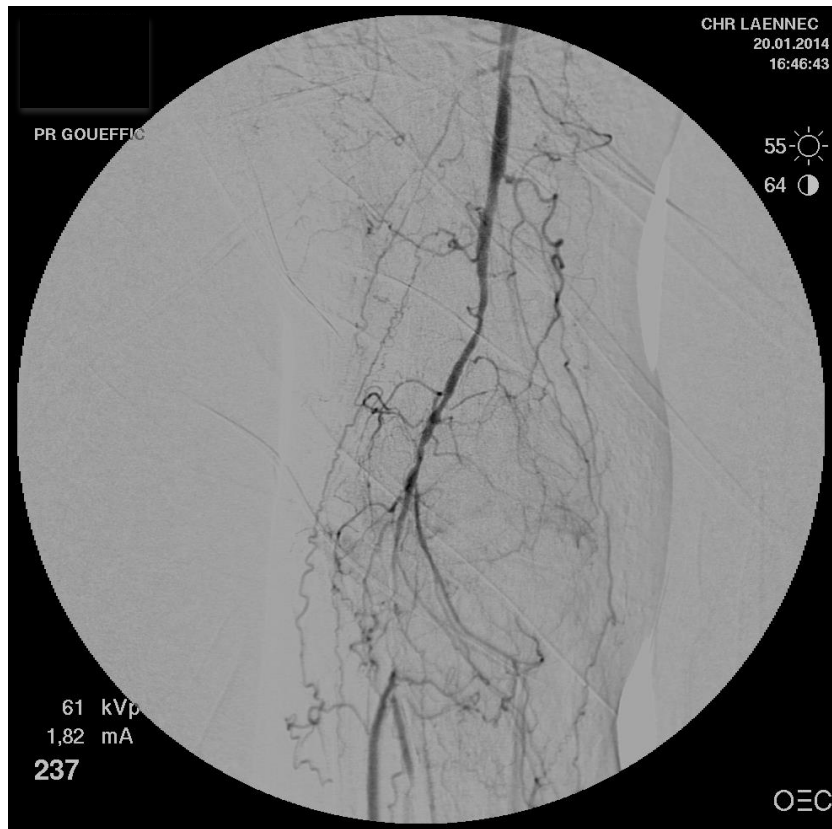
Ponction of the left common artery

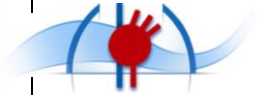Under local anesthesia and conscious sedation

Using duplex scan









# CLI of the right limb

**Endovascular treatment first  
to recanalise the anterior tibial  
artery**



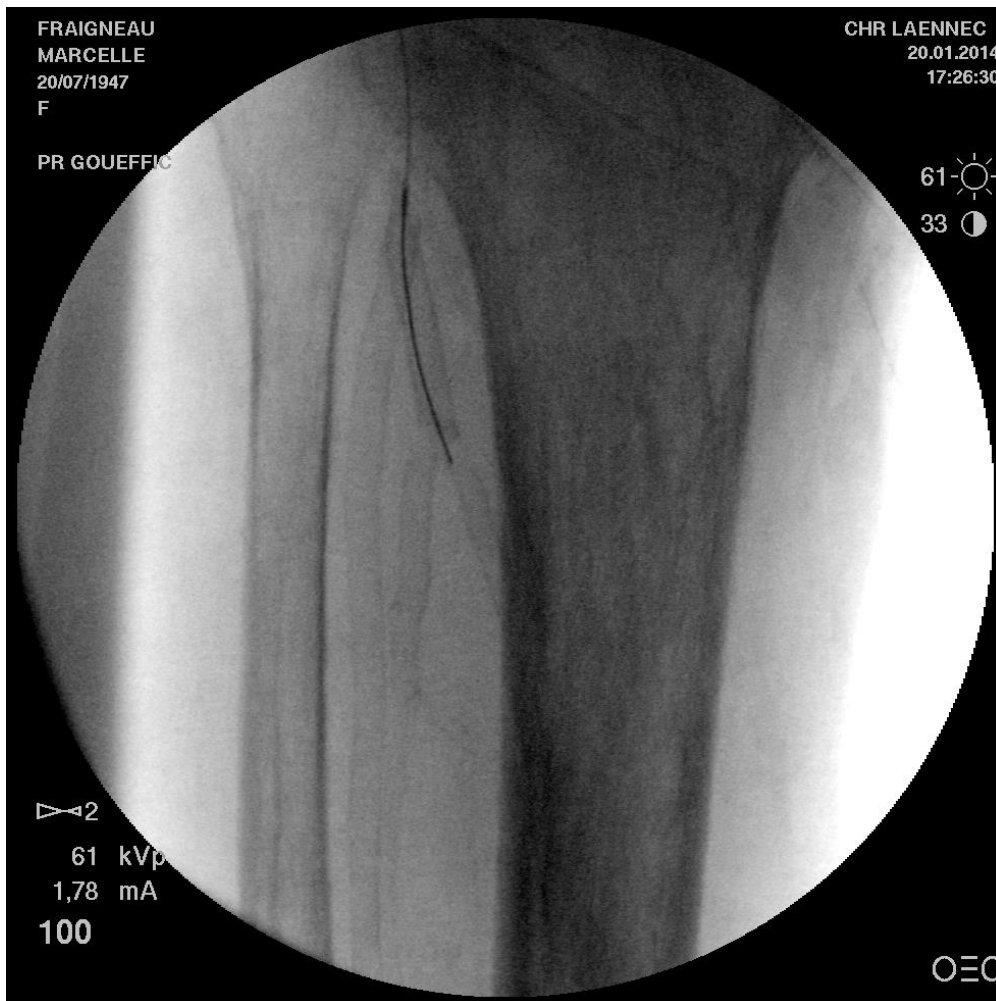# Procedure

- Over the bifurcation approach
- Long introducer (6F-90cm) (Destination, Terumo)
- 0.014 crossing and CTO guidewires (Command and Win 200, Abbott)
- Support catheter (Rubicon, Boston Sc)





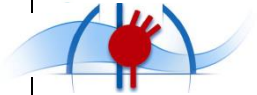# Antegrade failure





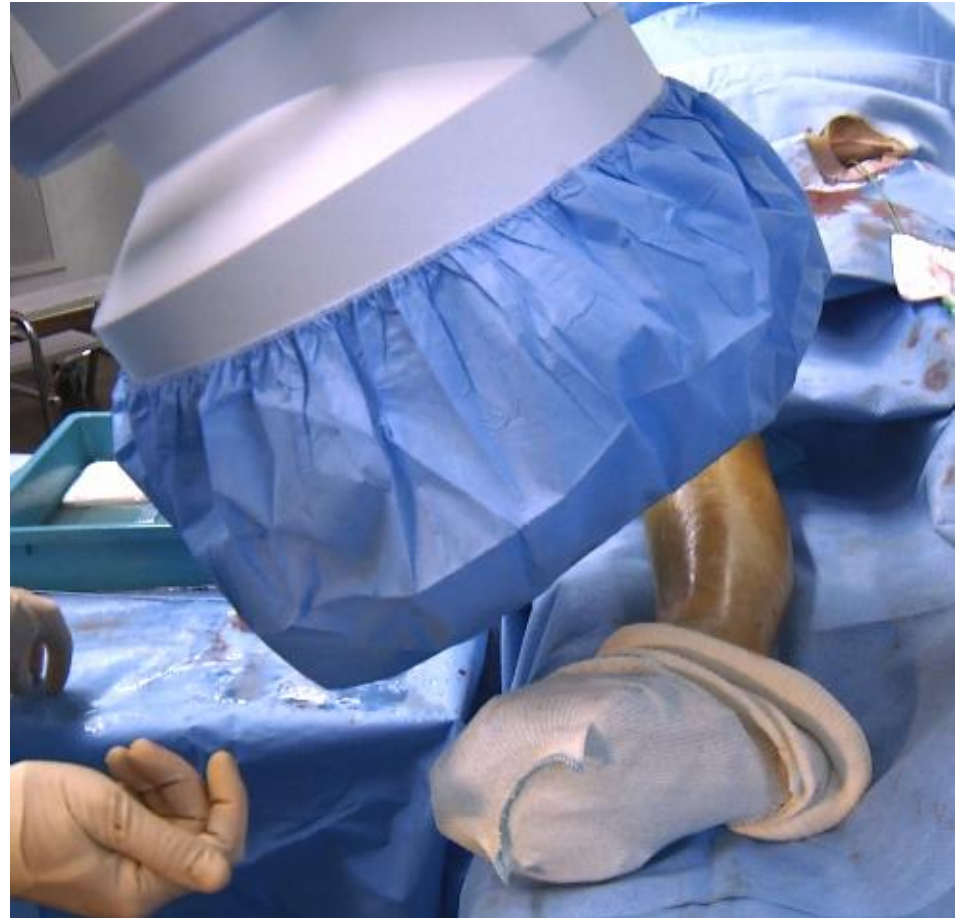
# Retrograde procedure

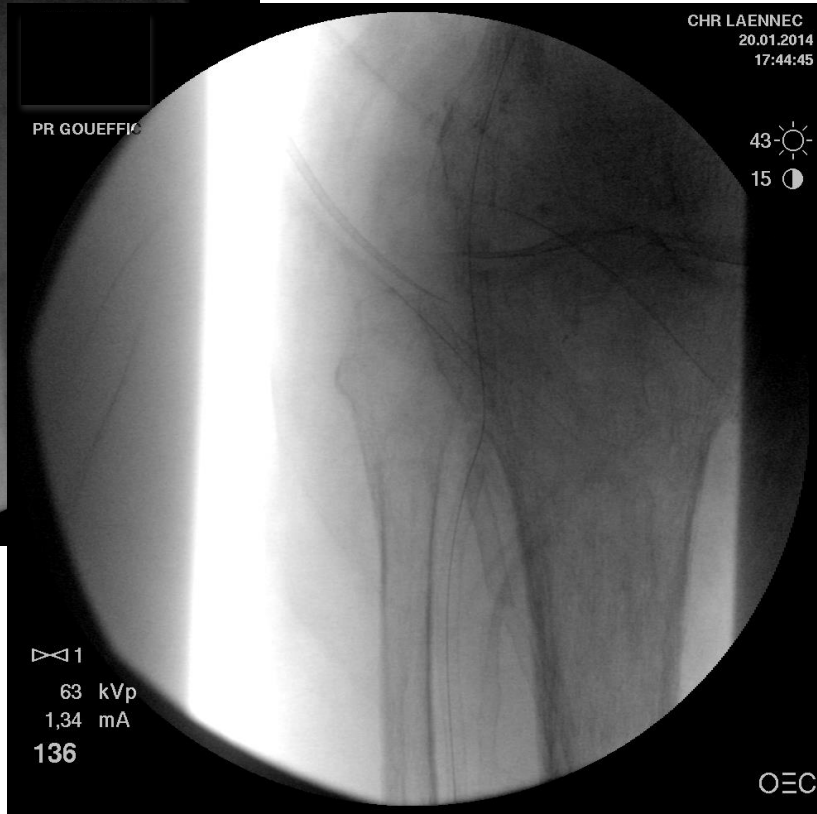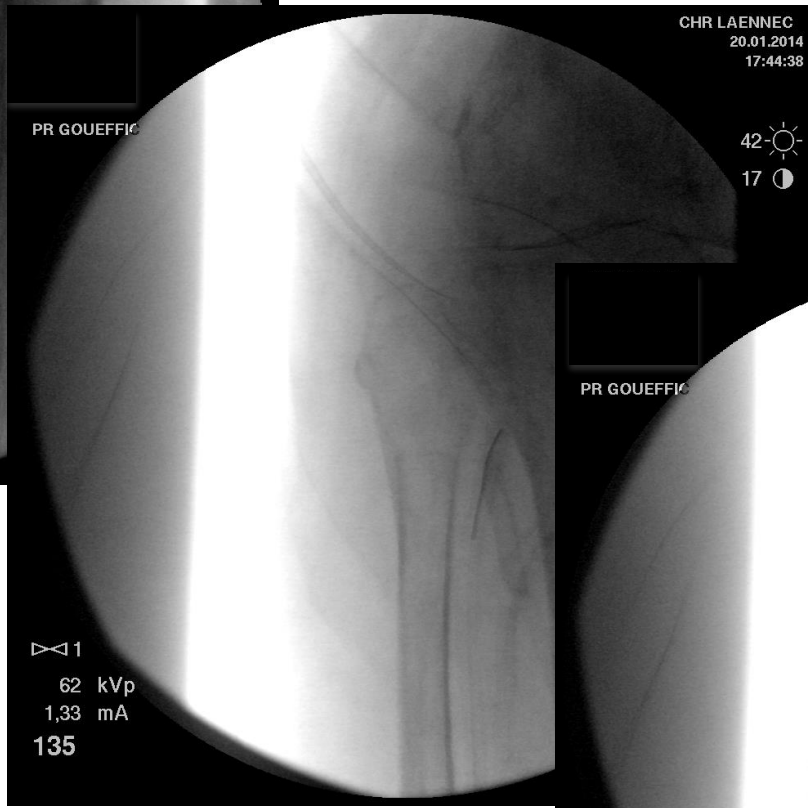
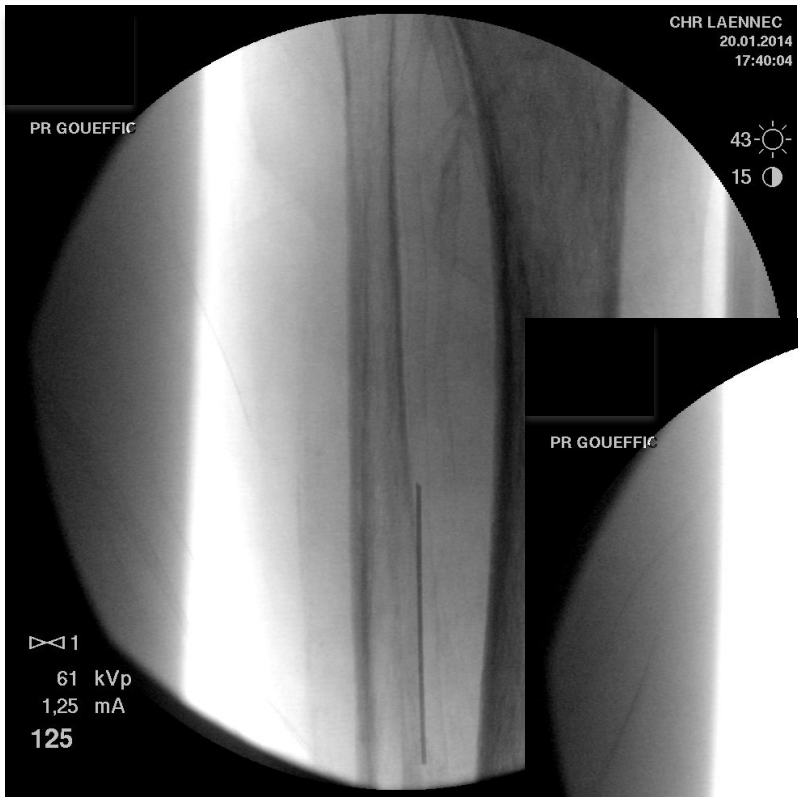
- Antegrade puncture of the anterior tibial artery
  - No introducer
  - 0.014 crossing guidewires (Command, Abbott)
    - Support catheter (Rubicon, Boston Sc)

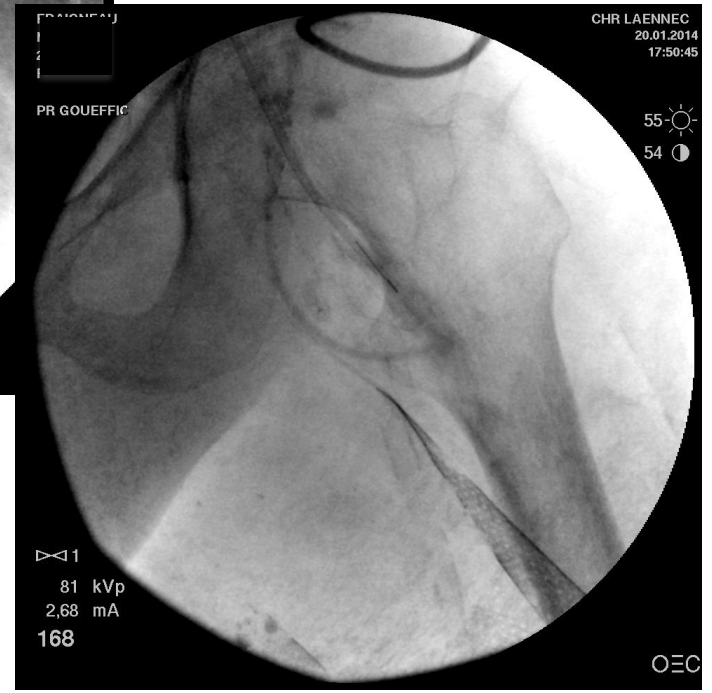
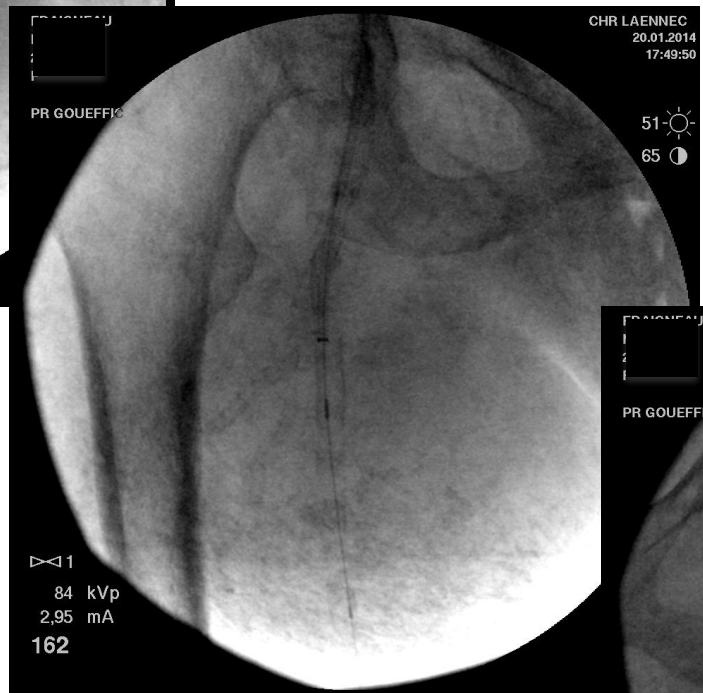
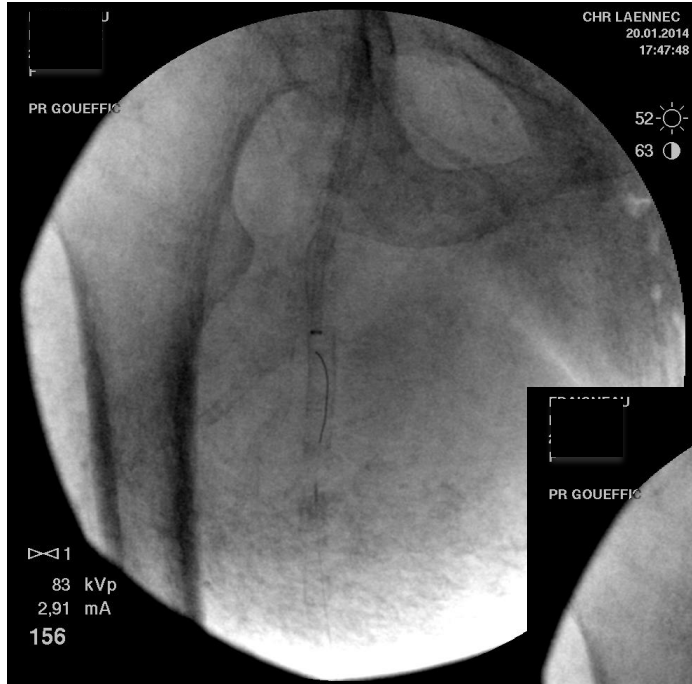


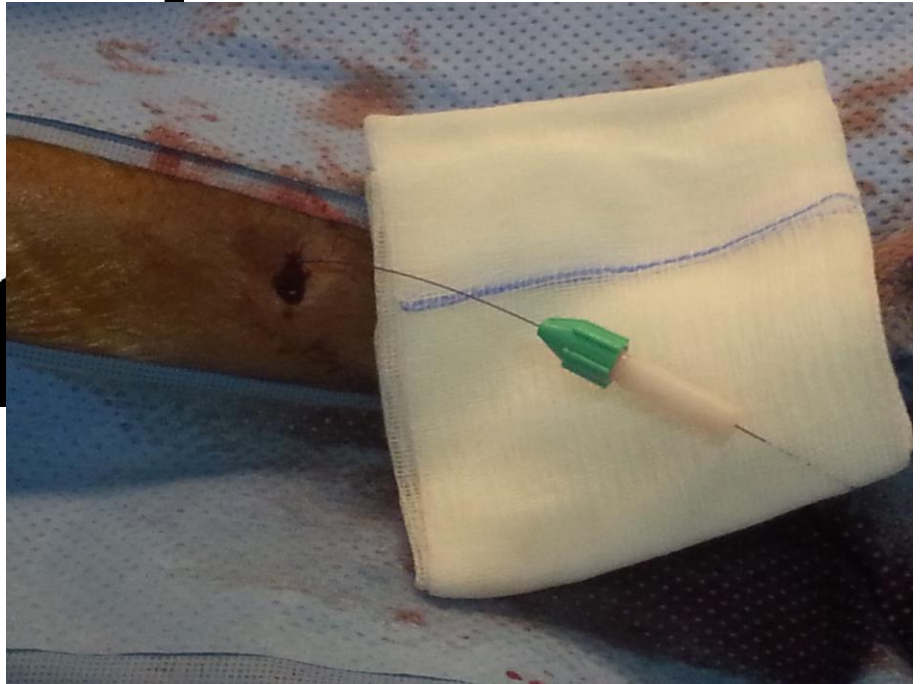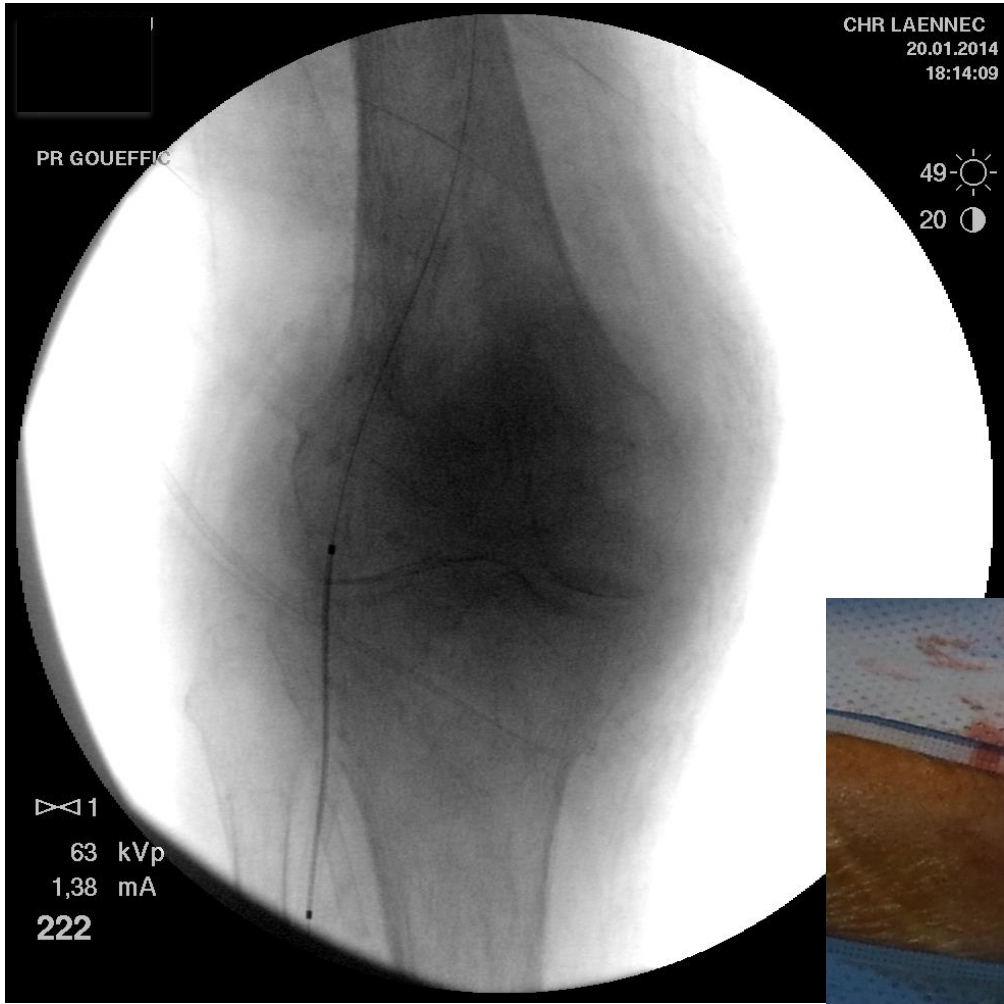
# Retrograde approach by anterior tibial artery

**NO**











# Final assessment by DSA

