CONTROVERSY: ACCESS & NECK ISSUES "PAVING AND CRACKING"

THIS IS NOT NECESSARY ANY MORE:
WE HAVE LOW PROFILE GRAFTS
S.RONCHEY

WE STILL NEED THIS TECHNIQUE
A. MILLON

SORRY BUT..

I'LL EAT YOU IN ONE BITE!!!!!

NO DISCOSURE

EVAR & ILIAC ACCESS

- SIZE MISMATCH
- OCCLUSIVE DISEASE

- TORTUOUS
- NARROWED
- STENOSED
- SEVERELY CALCIFIED

SMALL ACCESS VESSEL (7 mm)
6-23%

YANO 2001; ABU-GHAIDA 2002; GABRIELLI 2004; SLATER 2008;
EARLY 2012; KVINLAUG 2012, CHIESA 2014

SECOND CAUSE OF EVAR UNSUITABILITY

LAST 250 AAA CT

- ILIAC 5-6MM 14
- ILIAC ≤ 5MM 6

20/250 → 8%

EVAR → UNMODIFIED CHALLENGING ILIAC ANATOMY

1-15%

DISSECTION & RUPTURE

YANO 2001 - GABRIELLI 2004 – IGARI 2014

RISK FACTORS FOR COMPLICATIONS

- ENDOGRAFT DESIGN
- DELIVERY DEVICE
  - FLEXIBILITY
  - SIZE

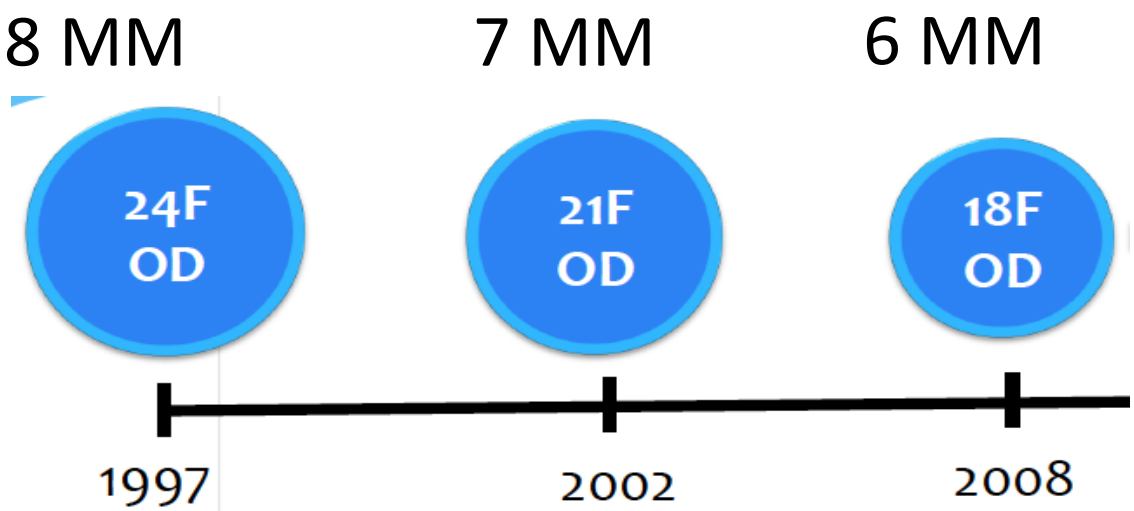

	FR
GORE C3	16-18 ID
ZENITH FLEX	18-22 ID
LP	16 ID
ENDURANT	18-20 OD
TREOVANCE	18-19 0D
ANACONDA	20-23 OD
AORFIX	22 OD
AFX	17 ID

≥ 6 MM OD

	FR
NELLIX	17 OD

MALE - 72YRS
HTA
CAD: IMA - CABG
COPD: O2TH
PMK

DIRTY NECK
L/HYPOG
SUBOCCL
L/EIA SUBOCCL
BIL SFA OCCL

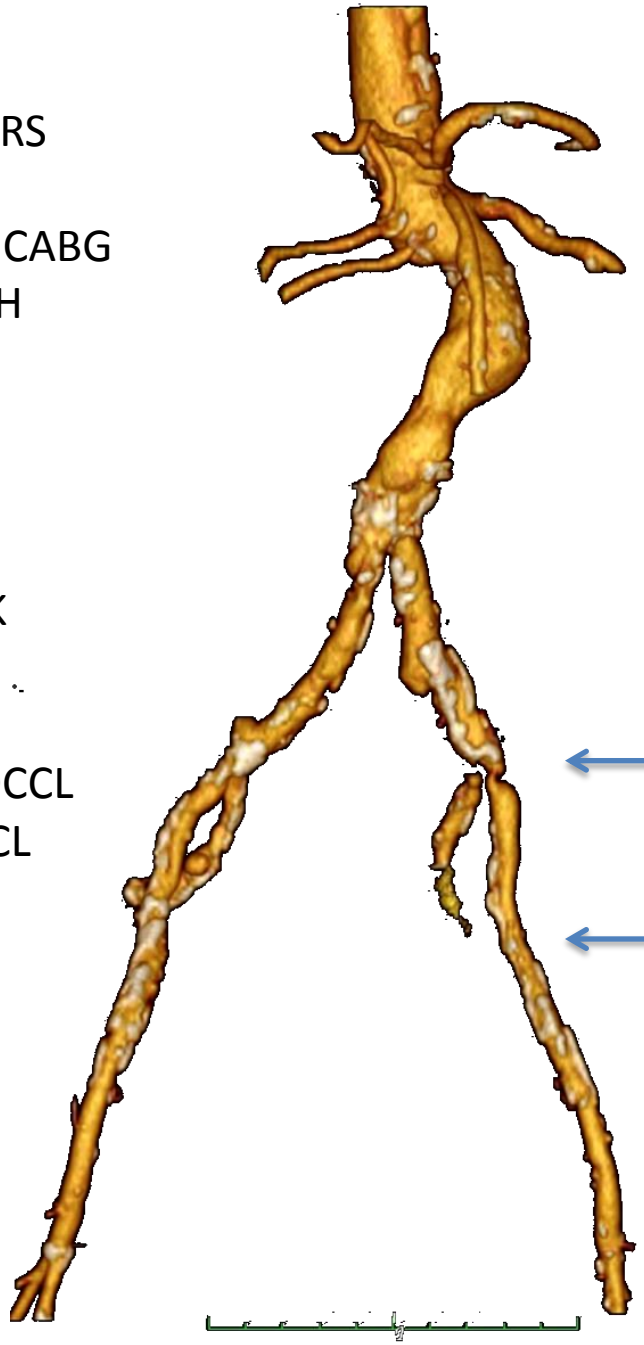

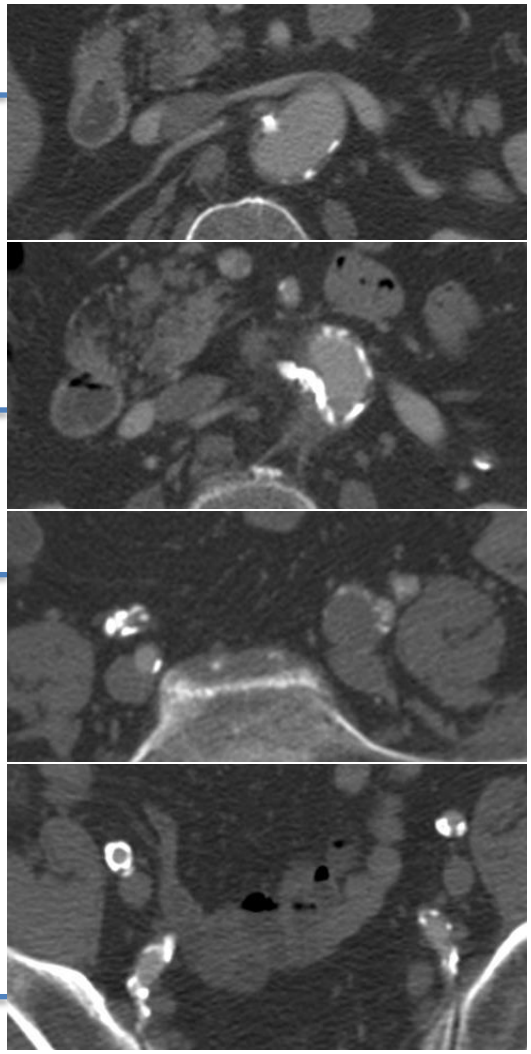

COOK LP

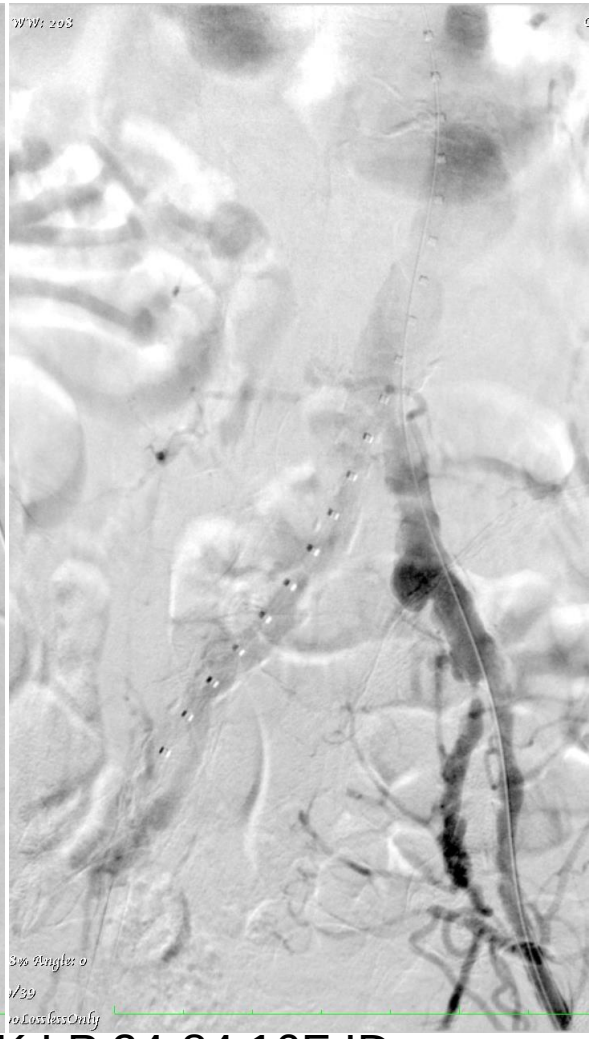

COOK LP 24-84 16F ID

RIGHT ILIAC PREDILATATION

INSUFFICIENT TO INSERT THE GRAFT

PAVING AND CRACKING ON THE LEFT
(PREOP IPOGASTRIC OCCLUSION)
VIABAHN 8-100

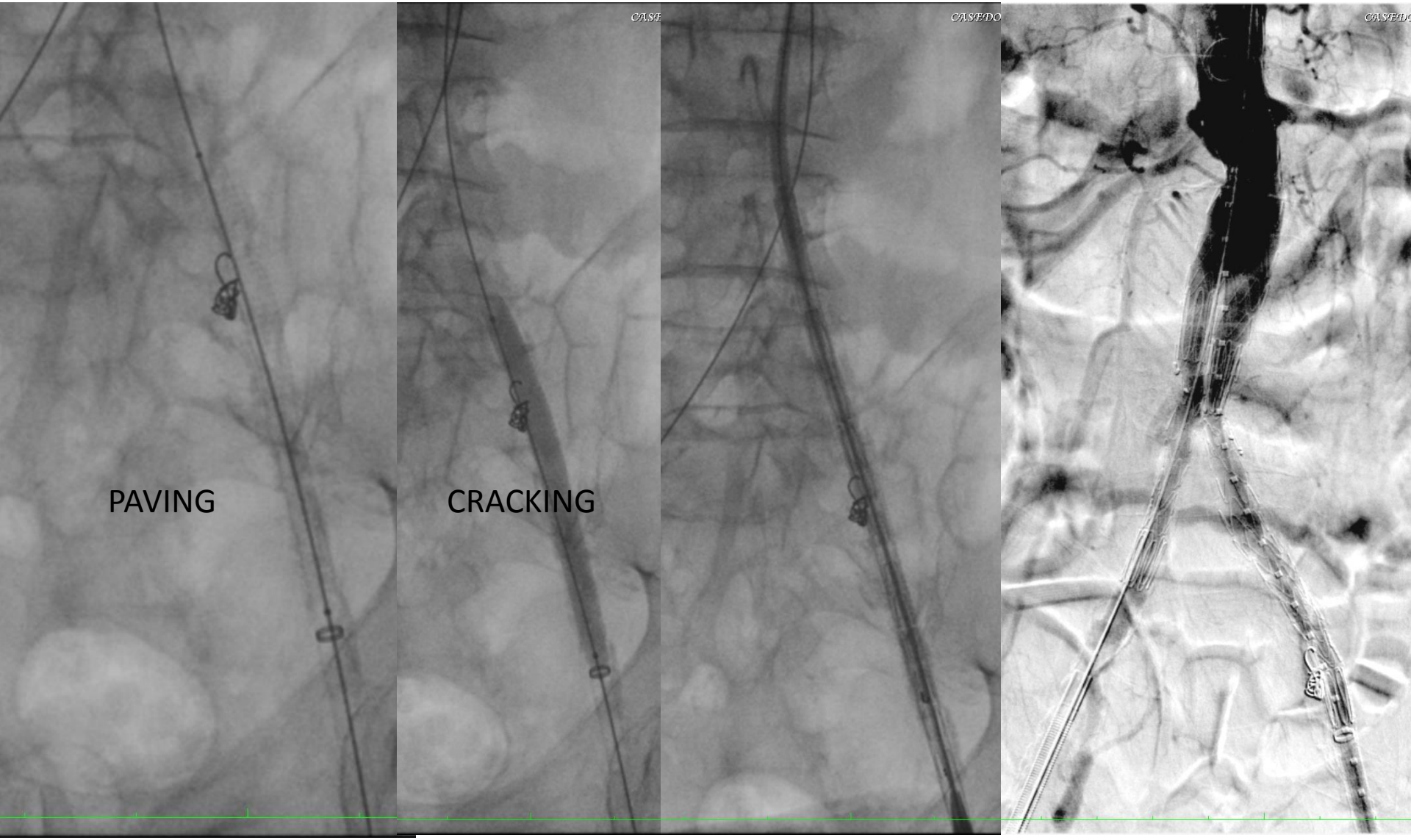

MEDTRONIC ENDURANT

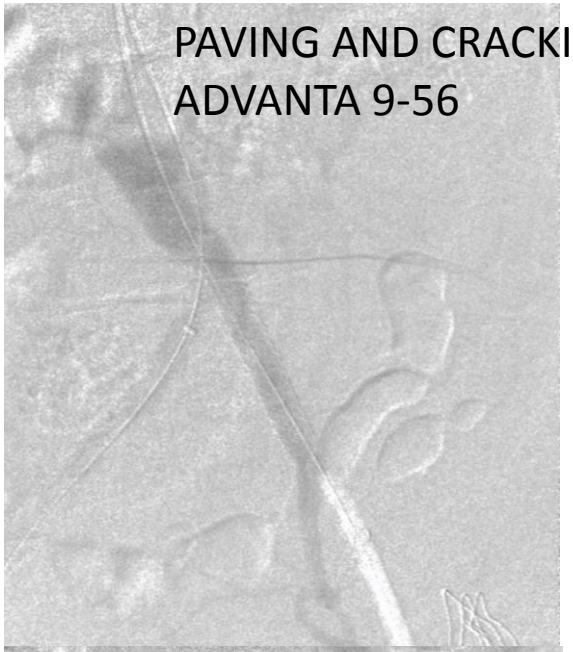

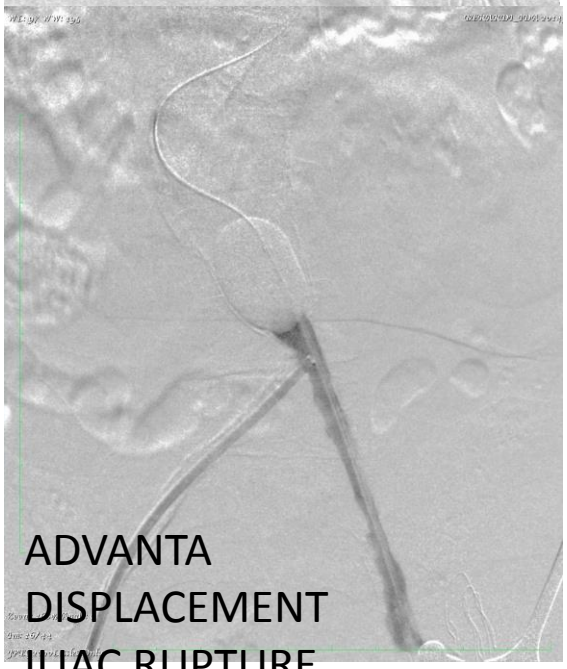

ADVANTA
DISPLACEMENT
ILIAC RUPTURE
AORTIC BALLONING

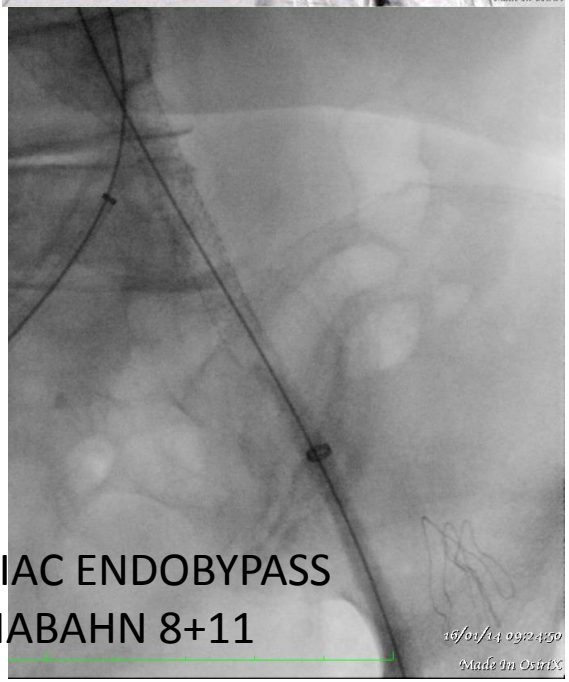

ILIAC ENDOBYPASS
VIABAHN 8+11

ENDURANT AORTO UNI 25-14-140 + 16-10-15

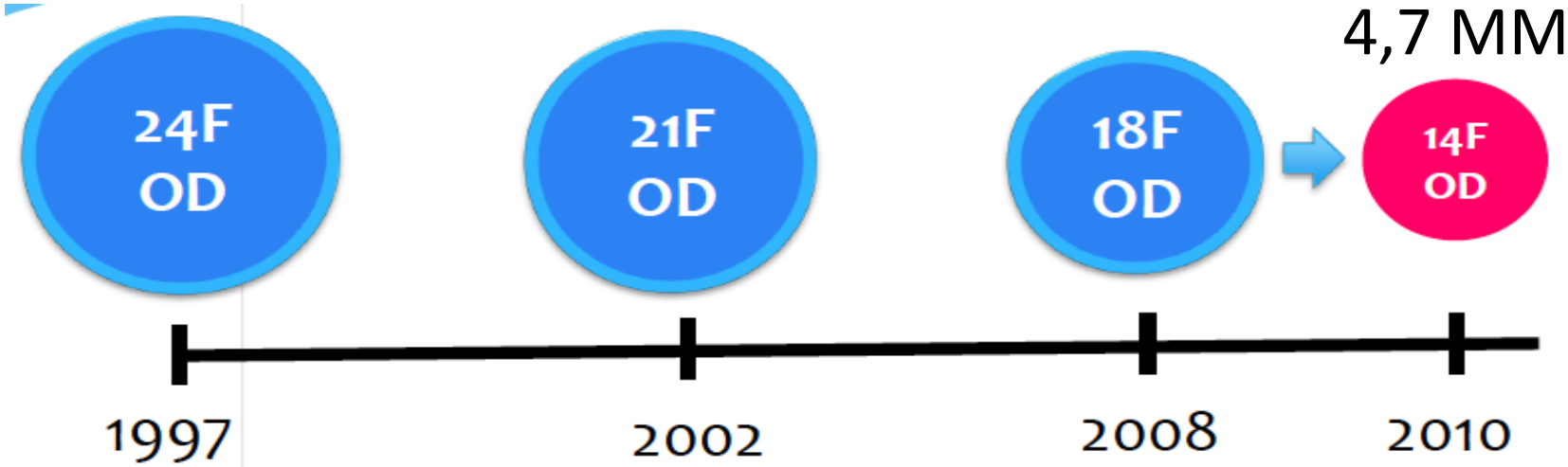

OVATION
14 F (15F→ 34 MM)
CE 2010/2012 FDA 2012

INCRAFT
14 F (16F→ 34 MM)
CE 12 AUG 2014 FDA ONGOING

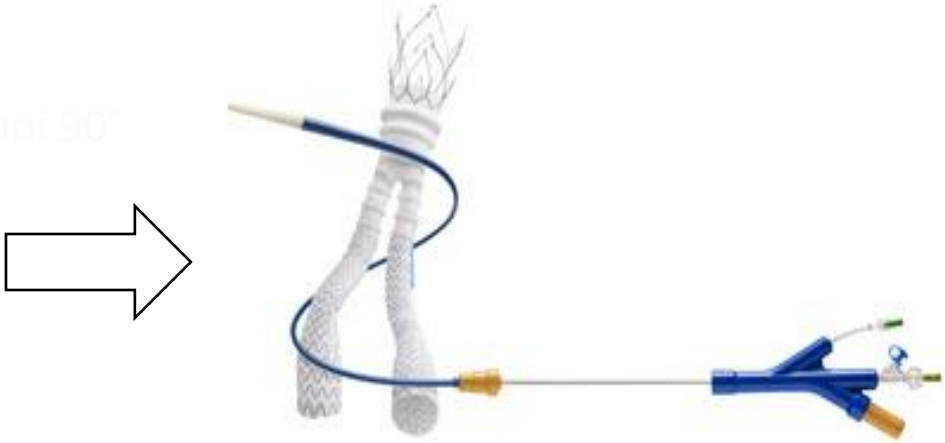

Comparison of EVAR Delivery Systems*

Lombard Aorfix™: 22F OD
Addresses 27% of AAA population*

Cook Zenith Flex®: 21F OD
Addresses 36% of AAA population*

Gore Excluder®: 20F OD
Addresses 40% of AAA population*

Endologix AFX™: 19F OD
Addresses 49% of AAA population*

Medtronic Endurant®: 18F OD
Cook LP 18F OD
Addresses 59% of AAA population*

TriVascular Ovation Prime® 14/15F OD
Addresses 83% of AAA population*
Cordis Incraft 14/16 OD
Addresses 77% of AAA population

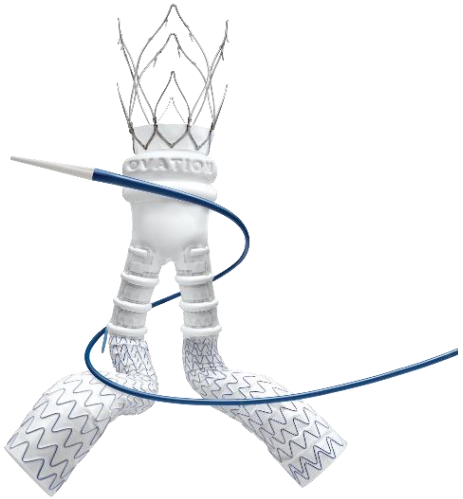

TriVascular Ovation Prime® 14F OD

Cordis Incraft 14F OD

*** Patient's Access Vessel Size Distribution**
(Derived from M2S Measurement Database of 43,000 CT Scans)

Novel Design Paradigm

14F OD

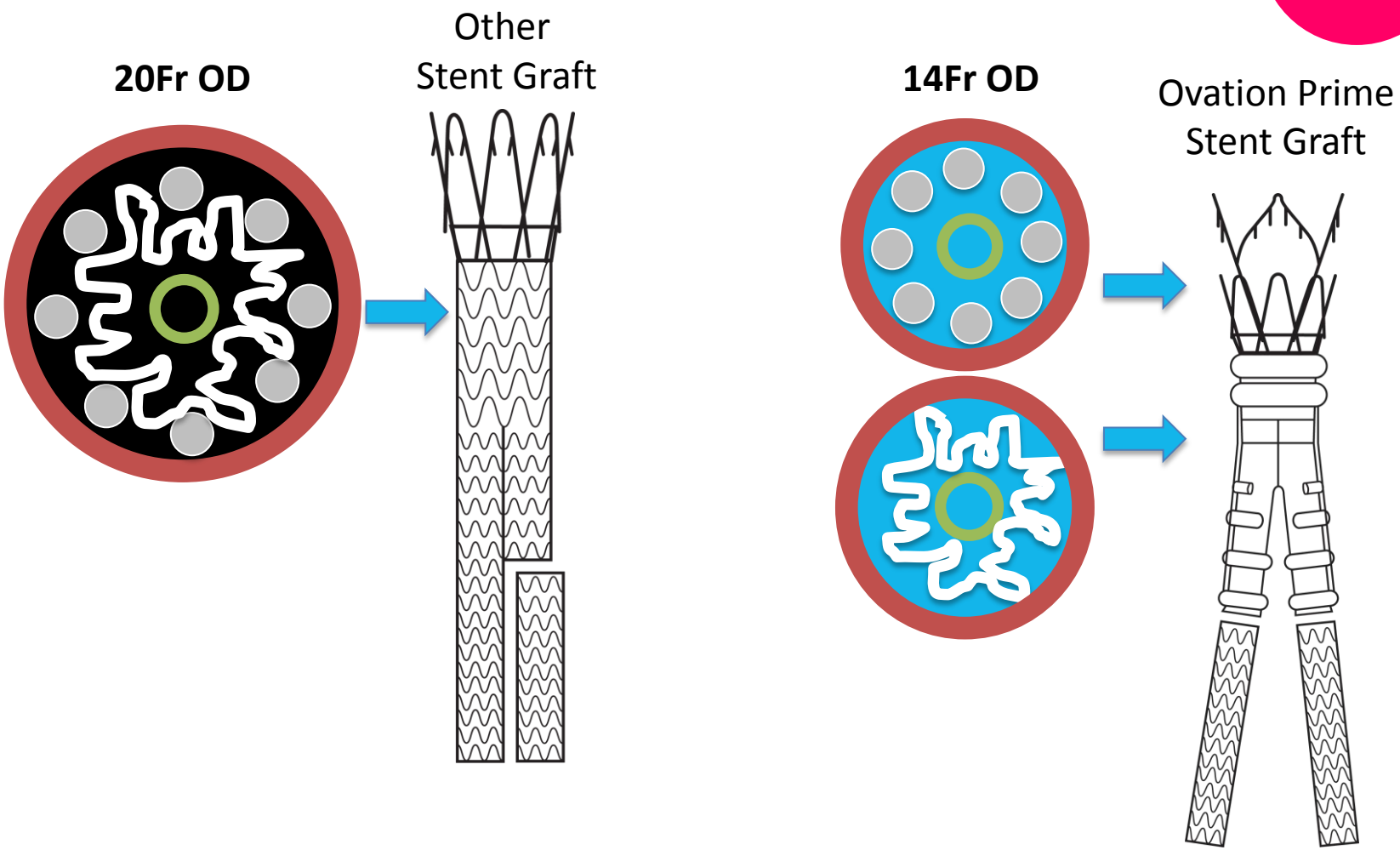

The Ovation Prime Aortic Body eliminates stent / material overlap which allows for significant reduction in profile without compromising durability

Note: Images show graphical representation of a stent graft

©2013 TriVascular, Inc. Caution: Federal (USA) law restricts this device to sale by or on the order of a physician. 830-0127-01rB

Novel Design Paradigm

14F OD

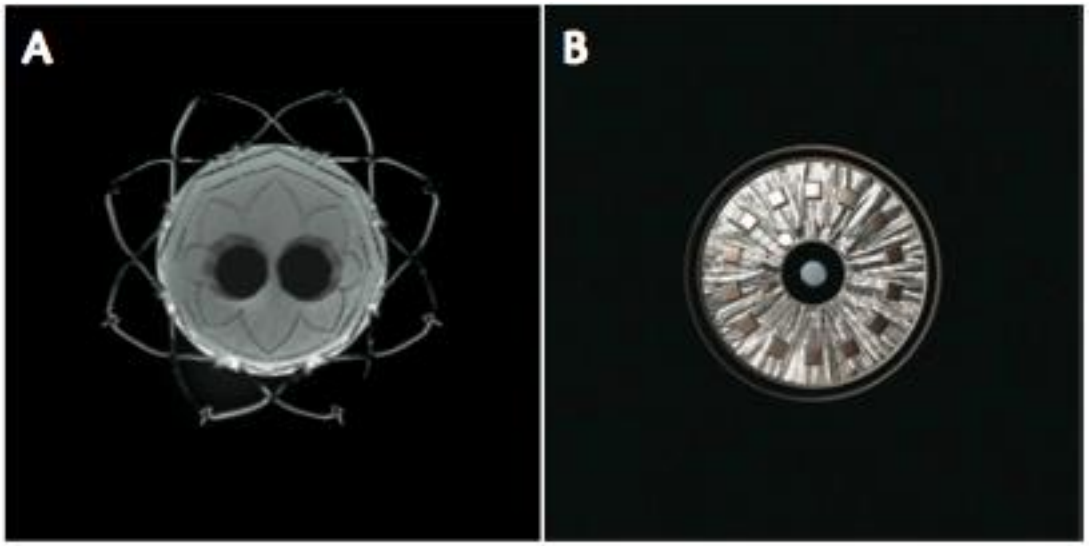

Figure 1. Fully deployed aortic bifurcate (A). Cross-sectional view illustrating the high packing efficiency of the stent graft in the ultra-low profile sheath (B).

Incraft SG caliper is reduced thanks to a laser-cut nitinol stents that pack more efficiently than more tipical wire-formed stent

High flexibility

Tri-modular design

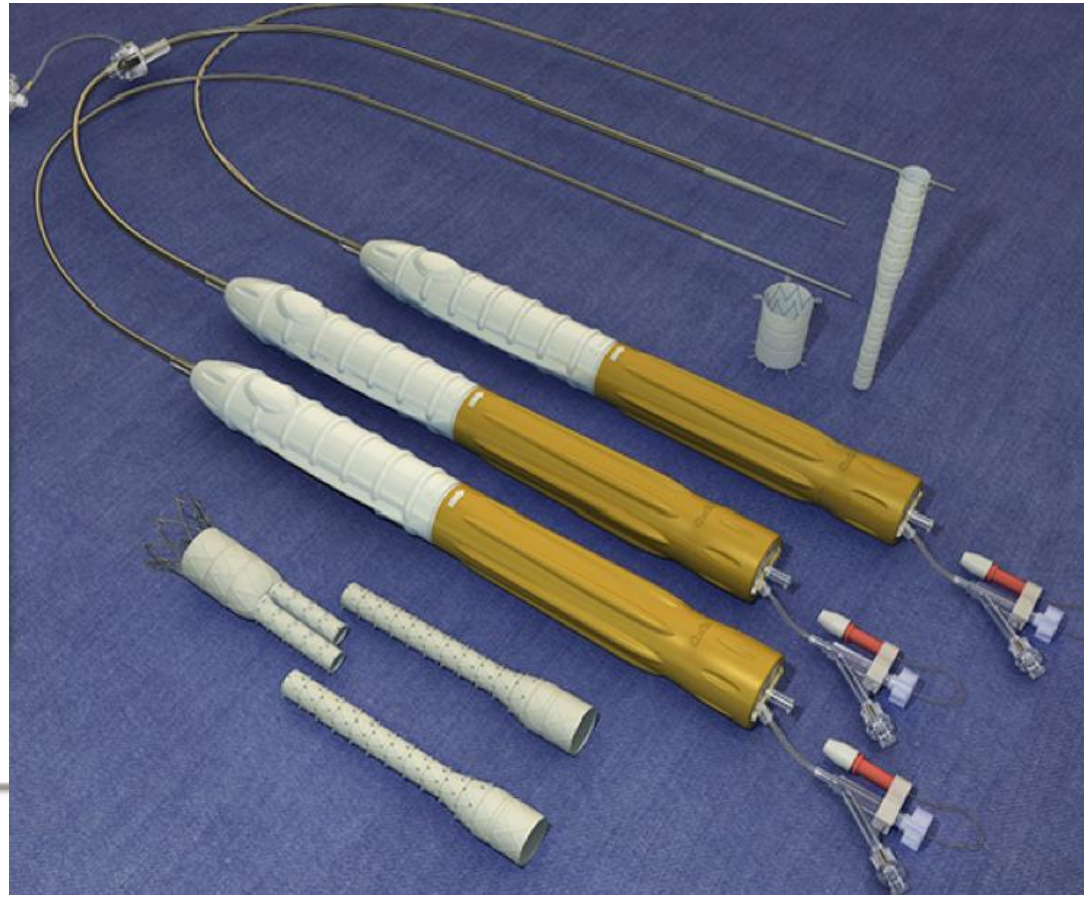

OVATION Novel Sealing Mechanism

Separation of Fixation and Seal

Fixation
Traditional stent based with anchors

Seal
Inflatable rings polymer fill without radial force

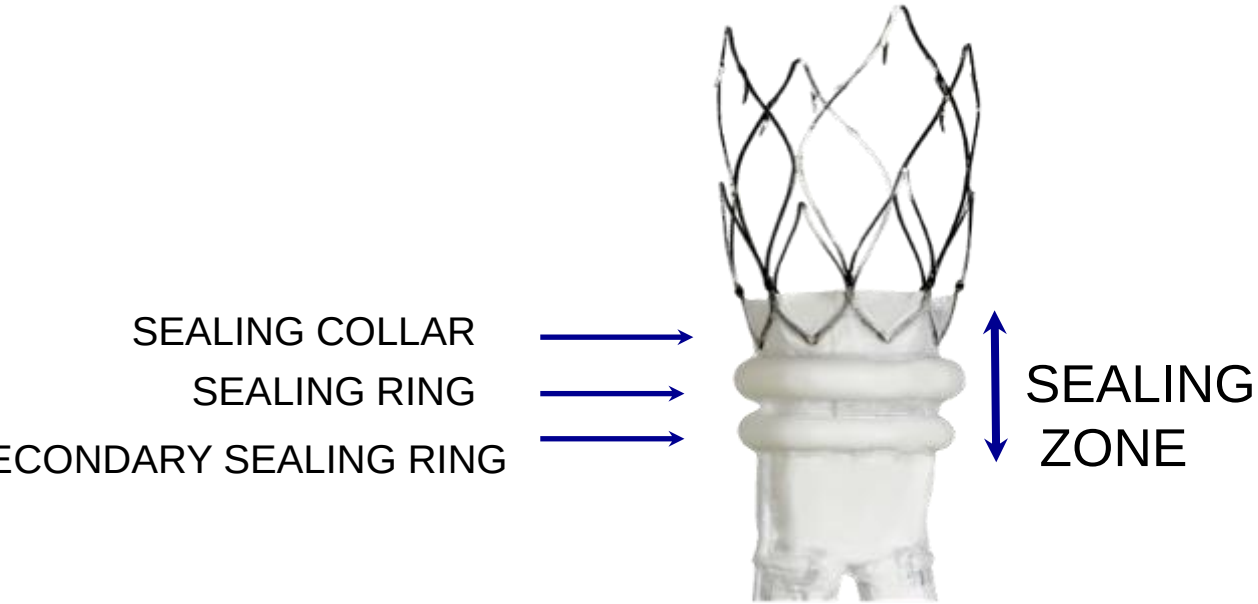

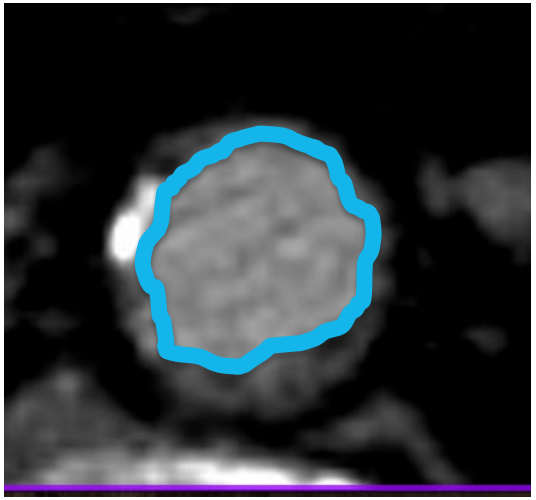

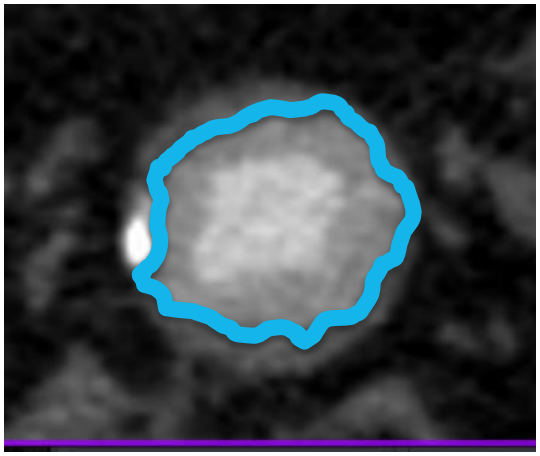

Conform **to patient anatomy**

OVATION RESULTS

Anatomically Challenging Subgroup Analysis
63 Patient Subgroup

39% (63/161) of patients treated had access vessels <6mm, aortic neck length <10mm, or both.

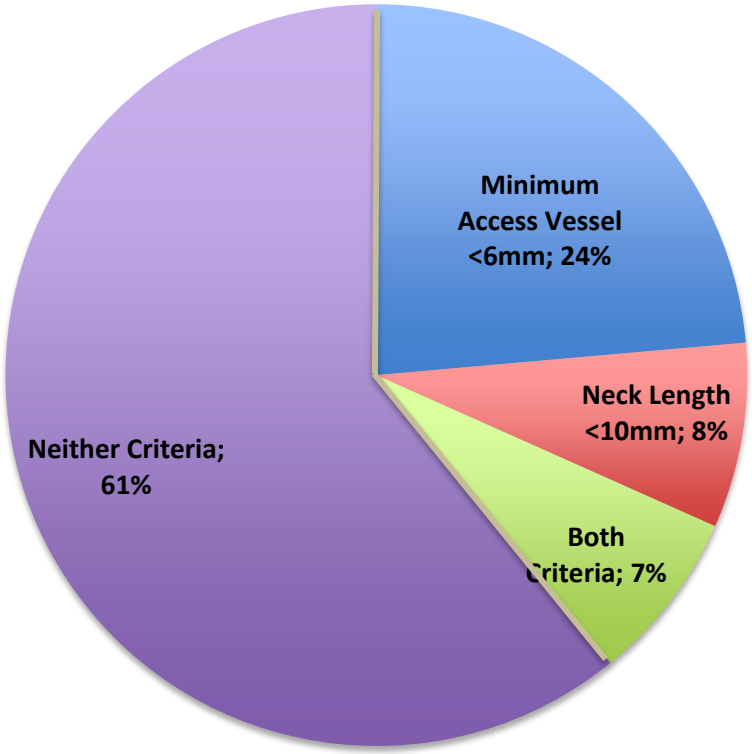

SAFETY	0-30 Days	31-365 Days
Major Adverse Events	0% (0/63)	3.2% (2/63)
Device Related MAEs	0% (0/63)	0% (0/63)

EFFECTIVENESS	30 Days	1 Year	2 Year
Freedom from Type I and III Endoleaks	100%	100%	100%
Freedom from Migration	100%	100%	100%
Freedom from Rupture	100%	100%	100%
Freedom from Conversion	100%	100%	100%

Ovation system's ultra low profile and advanced sealing technology produced excellent results in this anatomically challenging subgroup.

©2013 TriVascular, Inc. Caution: Federal (USA) law restricts this device to sale by or on the order of a physician. 830-0127-01rB

First-in-human study of the INCRAFT endograft in patients with infrarenal abdominal aortic aneurysms in the INNOVATION trial

Hostile Anatomy Attribute	*Categorization**	Absent	Mild	Moderate	Severe
Minimal aortic bifurcation ø	*(>22; 22-20; 20-18; <18)*	38%	10%	18%	33%
Left iliac sealing length (mm)	*(>30; 30-20; 20-10; <10)*	15%	12%	33%	40%
Right iliac sealing length (mm)	*(>30; 30-20; 20-10; <10)*	18%	20%	30%	32%
Left minimal access ø (mm)	*(>10; 10-8; 8-7; <7)*	2%	29%	24%	46%
Right minimal access ø (mm)	*(>10; 10-8; 8-7; <7)*	2%	30%	24%	44%
Iliac Tortuosity (τ)	*(<1,25; 1,25-1,5; 1,5-1,6; >1,6)*	85%	12%	0%	2%

OPERATIVE COMPLICATION:
1 ILIAC DISSECTION (60 PTS) COVERED BY THE LEG (1.6%)

AT 3 YRS

2 LIMB OCCLUSION (2/3RD YR)
1 FRACTURE

LAST 250 AAA CT

- ILIAC 5-6MM 14
  - OVATION 5
  - COOK LP 5
  - GORE C3 (23MM -16 F) 4

- ILIAC ≤ 5MM 6
  - OVATION 3
  - INCRAFT 2
  - COOK LP (SINGLE STEN) 1

Personal Experience
OVATION & INCRAFT

69 OVATION & 4 INCRAFT ILIAC ISSUES

✓ OVATION

- 13 ACCESS <6 mm bilat
- 18 ILIAC STENOSIS
- 12 SEVERE ILIAC TORTUOSITY

✓ INCRAFT

- 2 ACCESS < 6 mm bilat

Dirty neck

Small/Diseased/Tortuous access vessels

Narrow /Calcified Aortic Bifurcation

Narrow/Tortuous Access Vessels

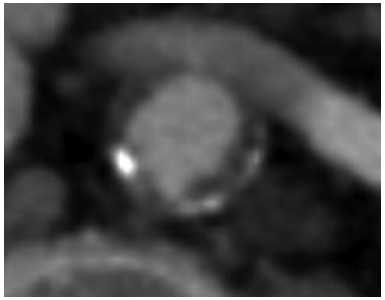

Thrombus at
sealing zone

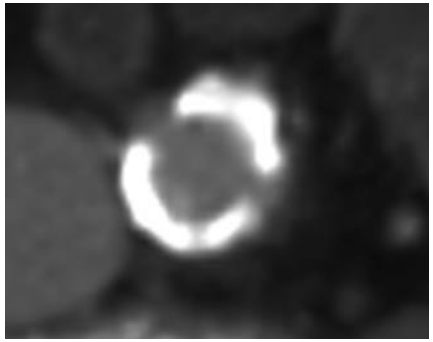

Calcification
at Bifurcation
(10x13 mm)

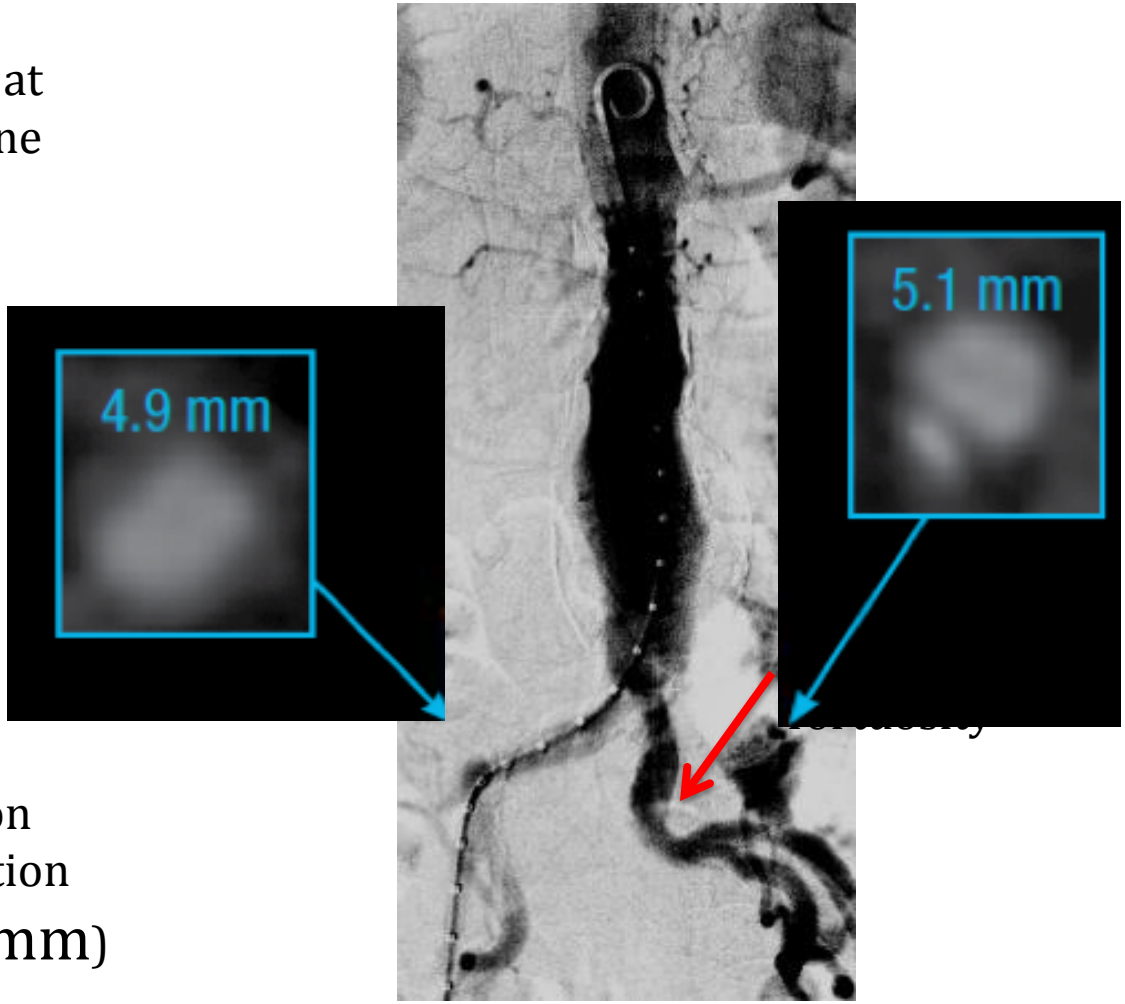

Difficult Access - Result

Percutaneous Bifurcated + 2 Limbs 50 min

PREDILATATION ON THE LEFT

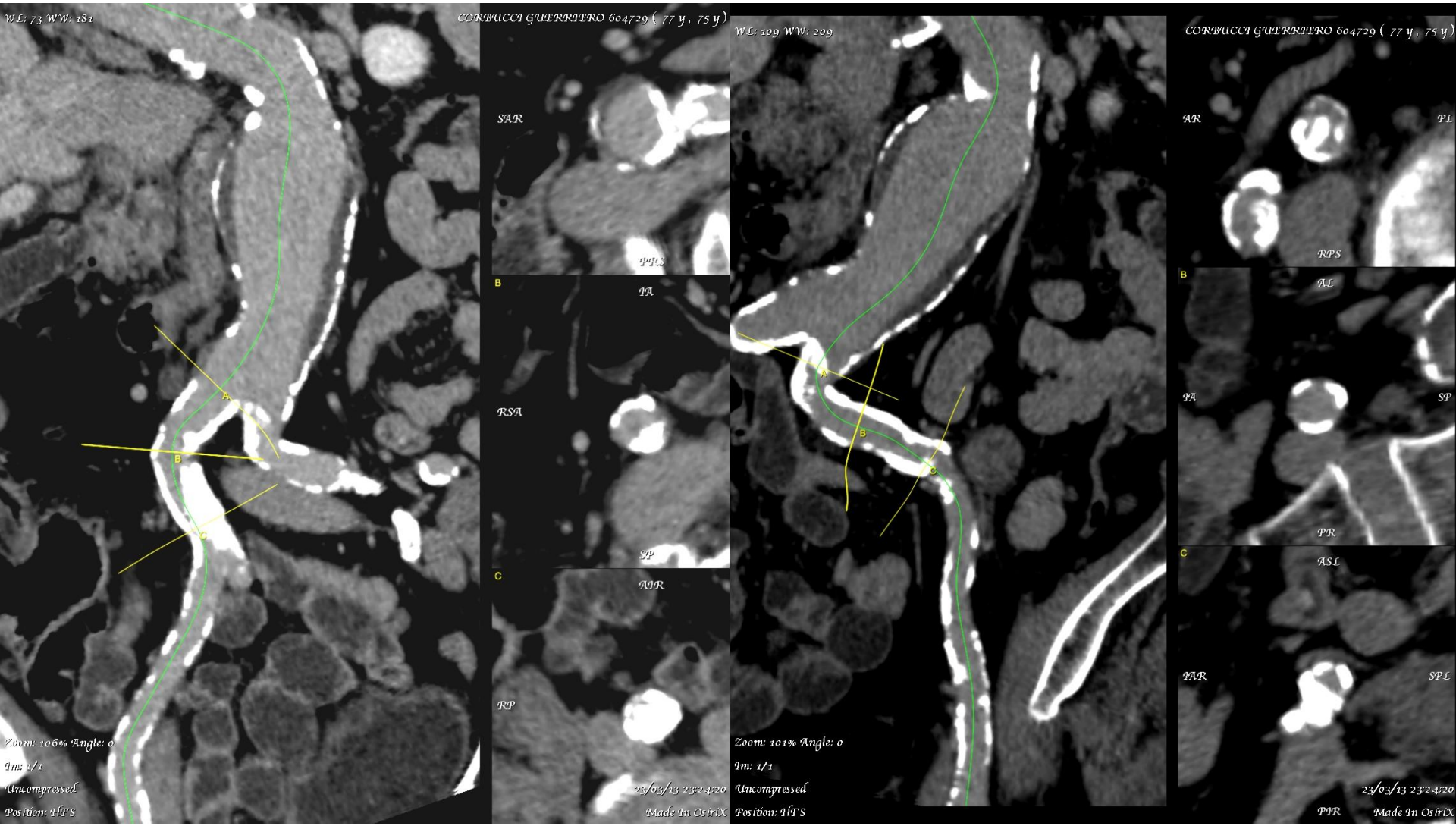

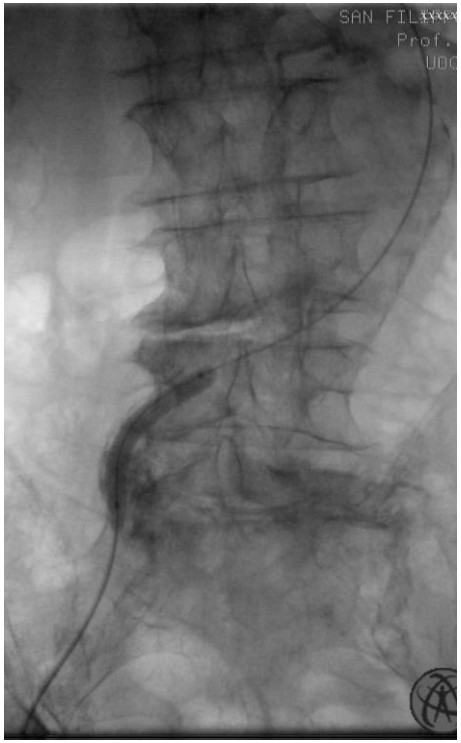
SAN FIL
Prof.
UDC

SAN FIL
Pro

INCRAFT 26 mm

FEMALE 69 YRS
HTA

BIL ILIAC STENOSIS
BIL SFA OCCL

INCRAFT

R-IA

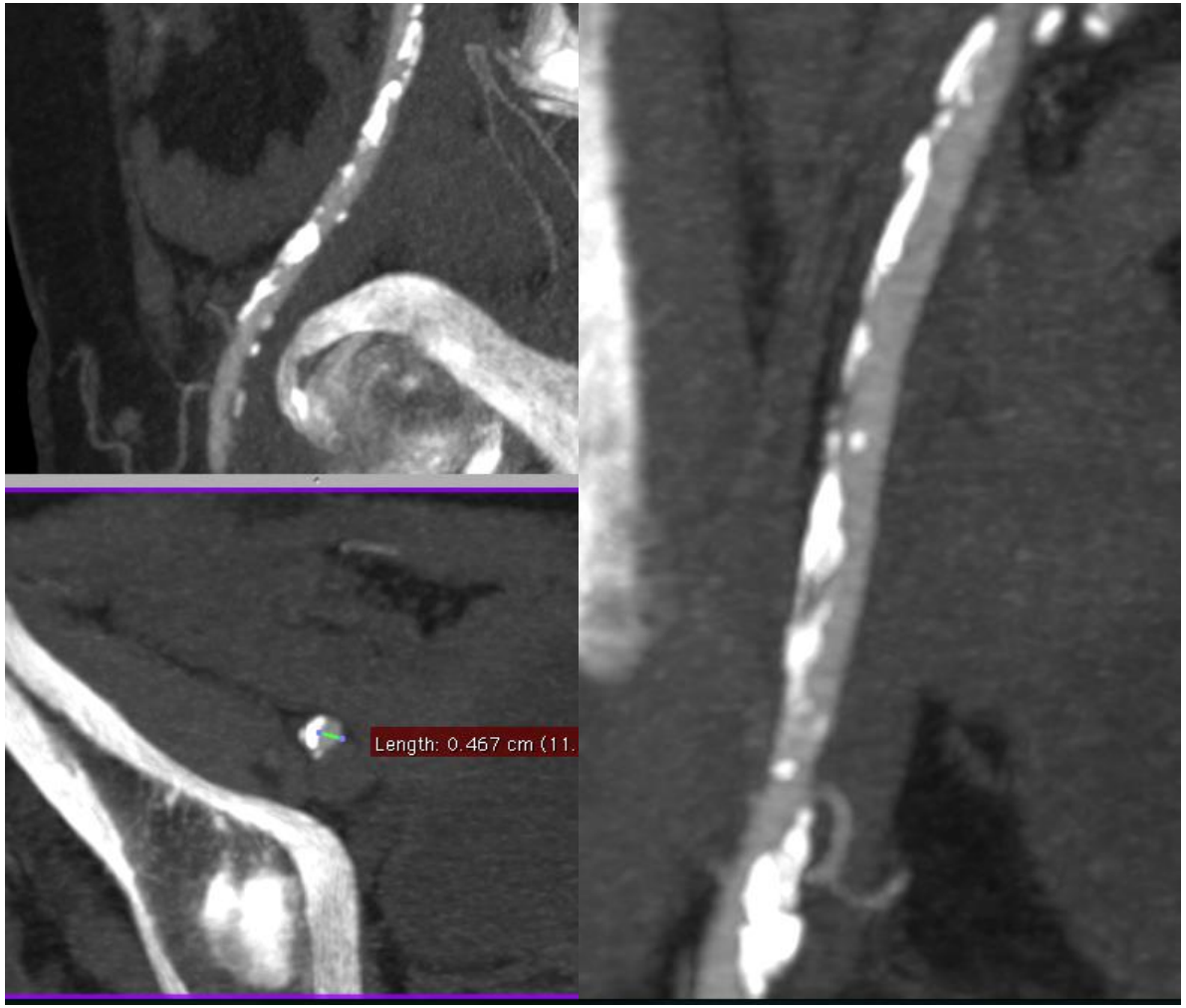

L-IA

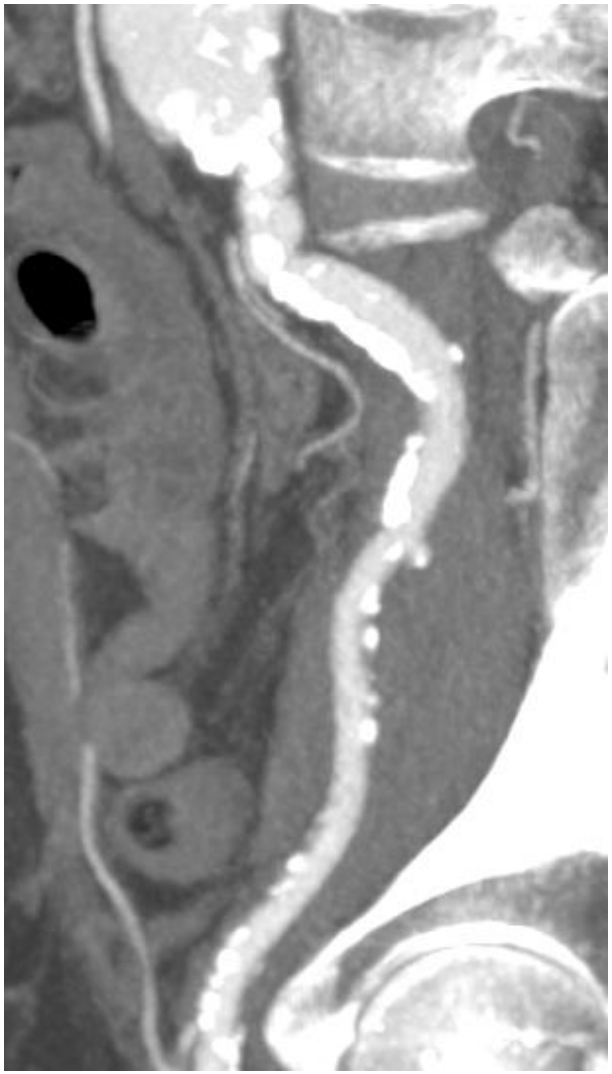

INCRAFT 26 mm

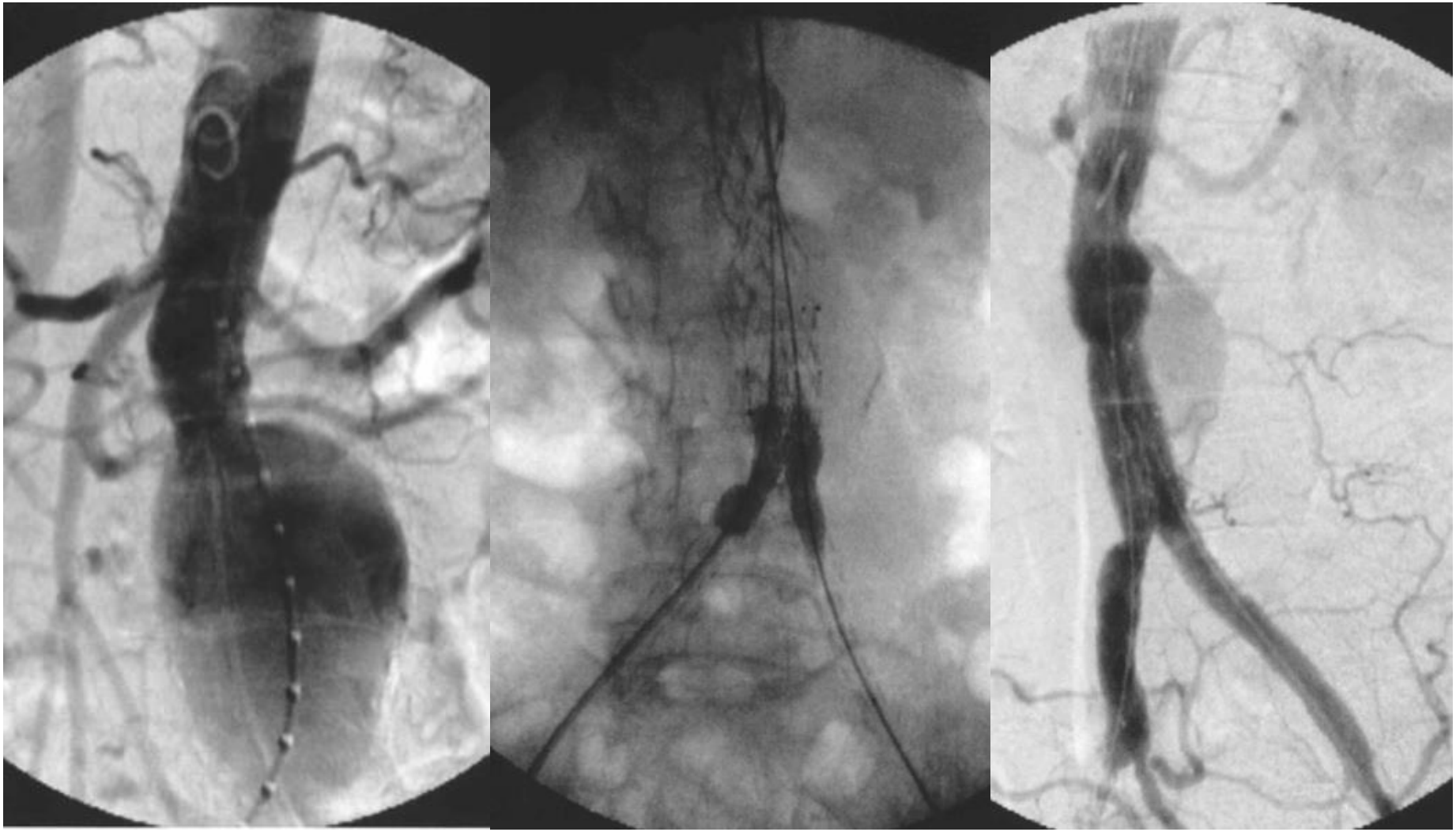

LESSON LEARNED
BALLOONING &/OR STENT RELINING TO BE DONE IMMEDIATELY!!

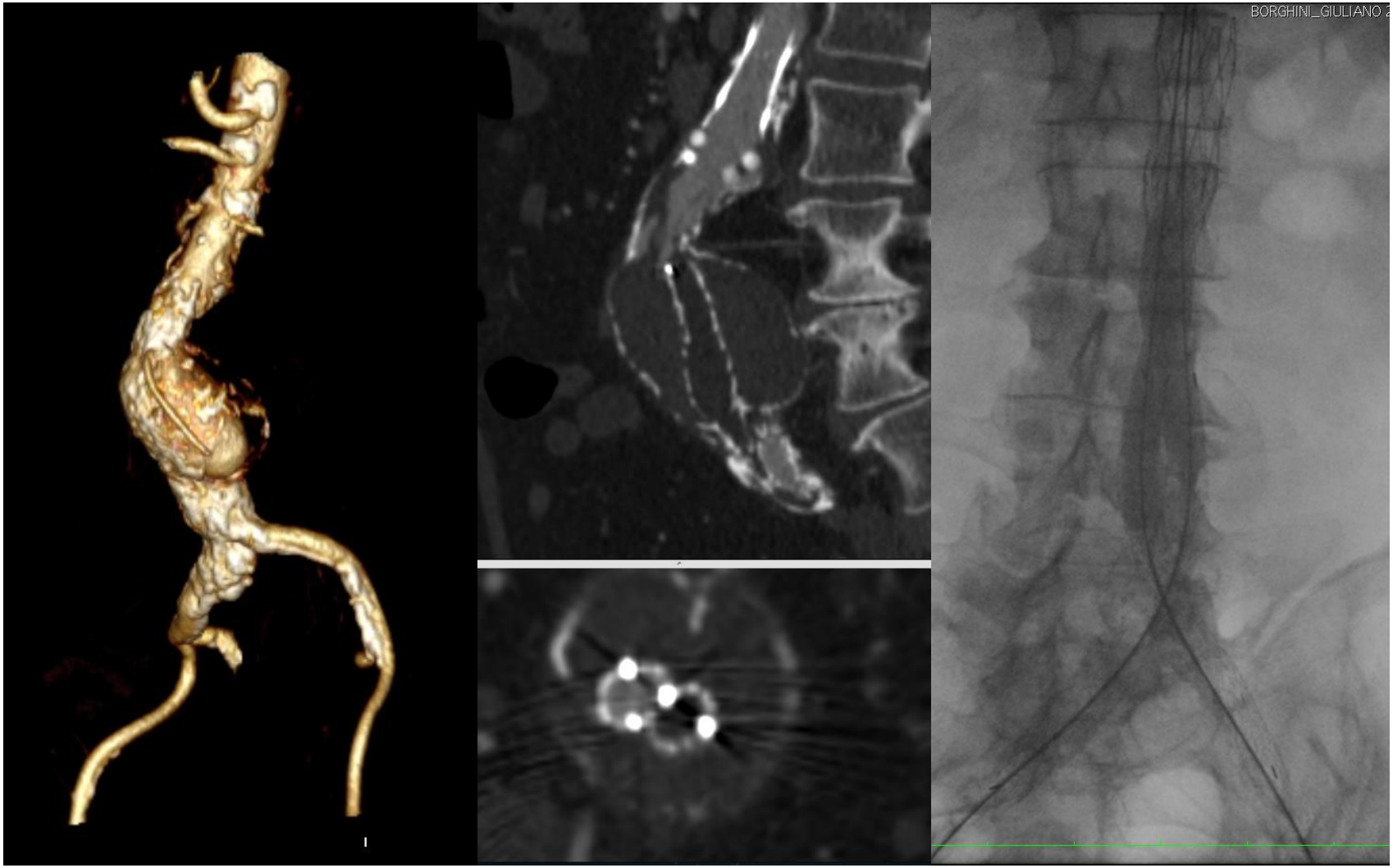

EV3 PROTEGE' 12-80

Thrombotic/Short/Angulated neck

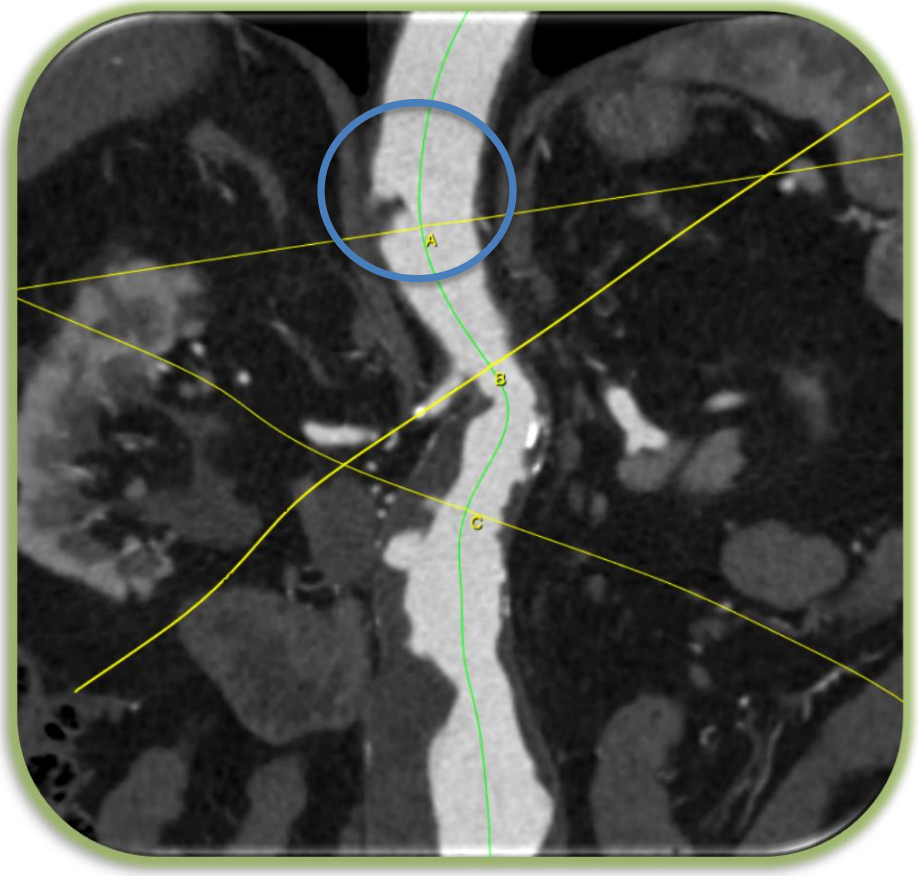

Male 70-75 years	
Neck Diameter	20.8 mm
Aneurysm Diameter	52 mm
Iiac Diameters	R: 11.6mm L: 8.1 mm
Access Diameters	R: 4.6 mm L: 4.9 mm

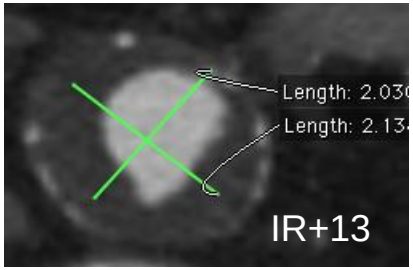

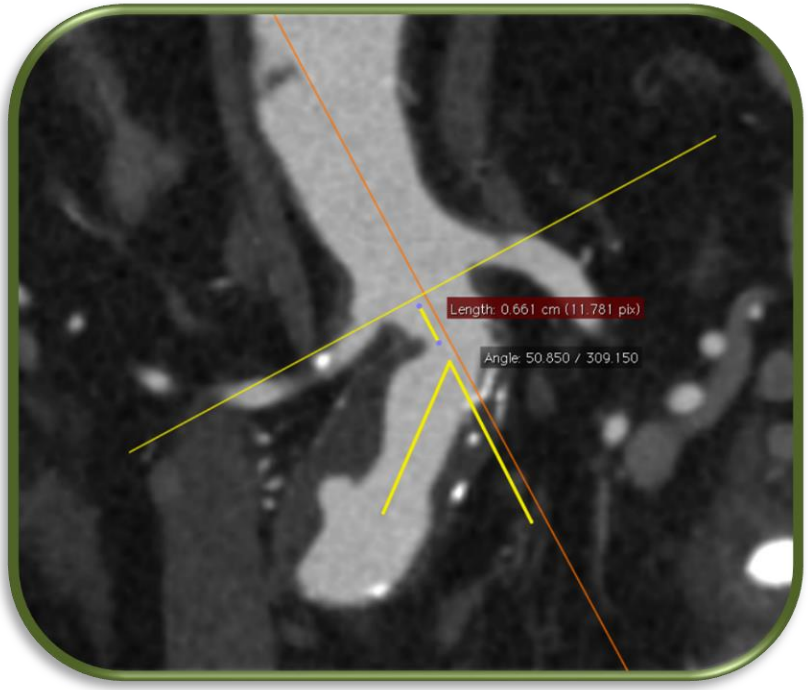

Small/Diseased iliac arteries : previous stenting on the left side

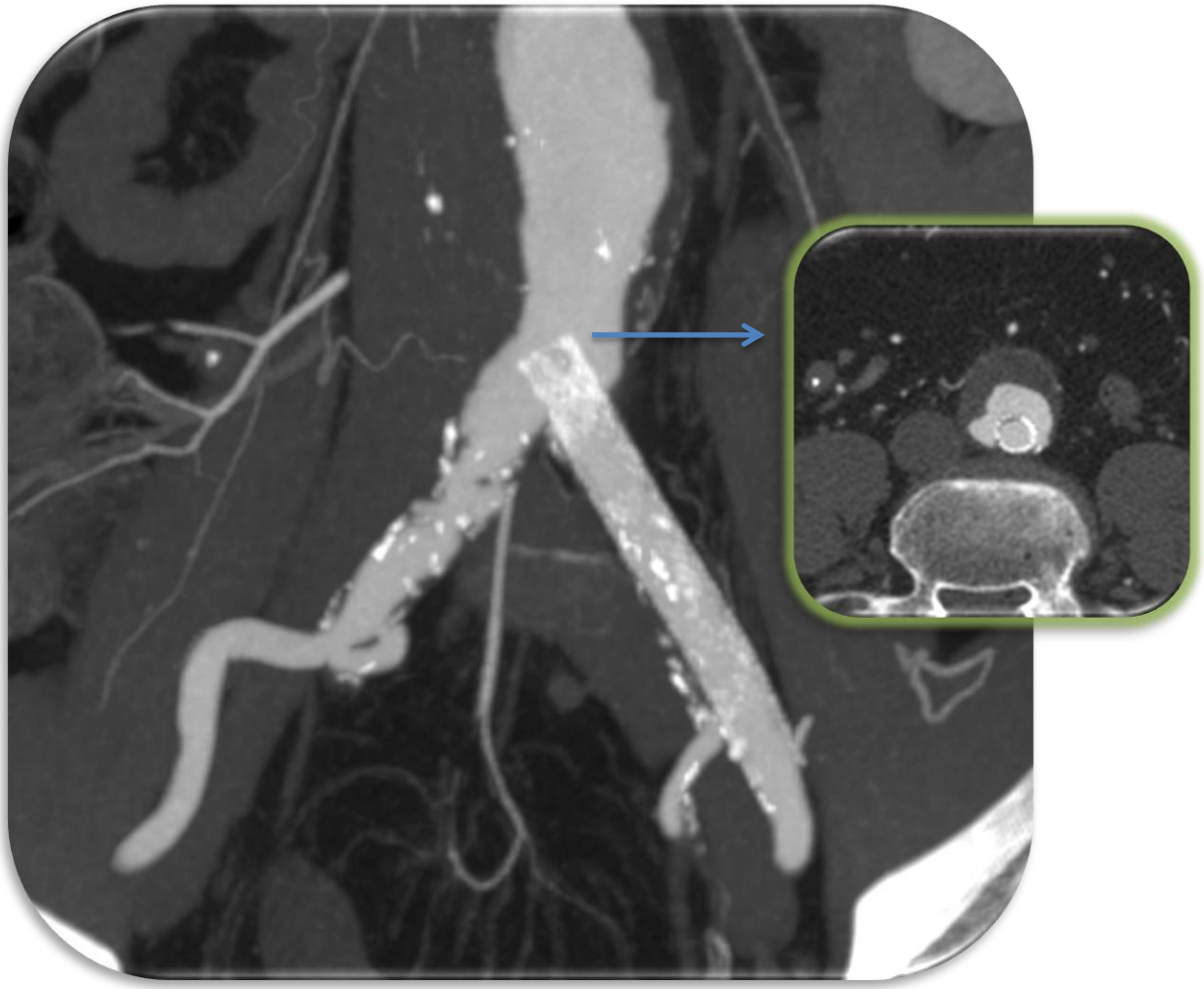

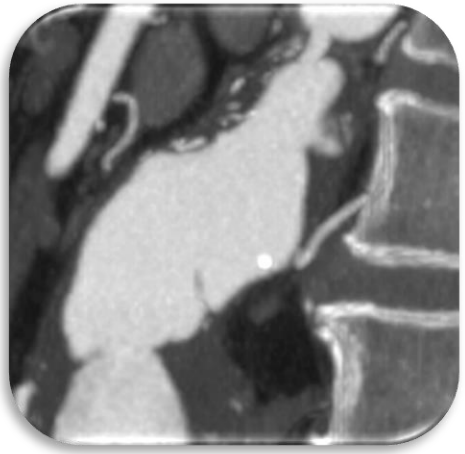

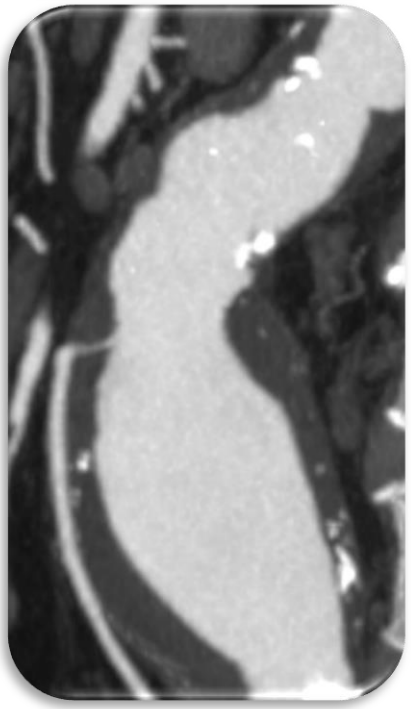

Percutaneous Bifurcated + 4 Limbs 50 min

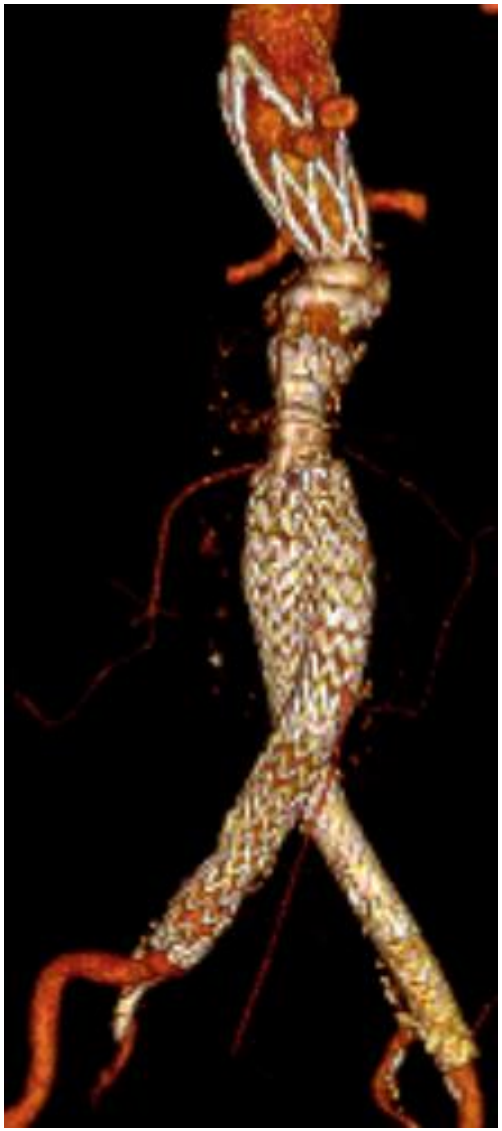

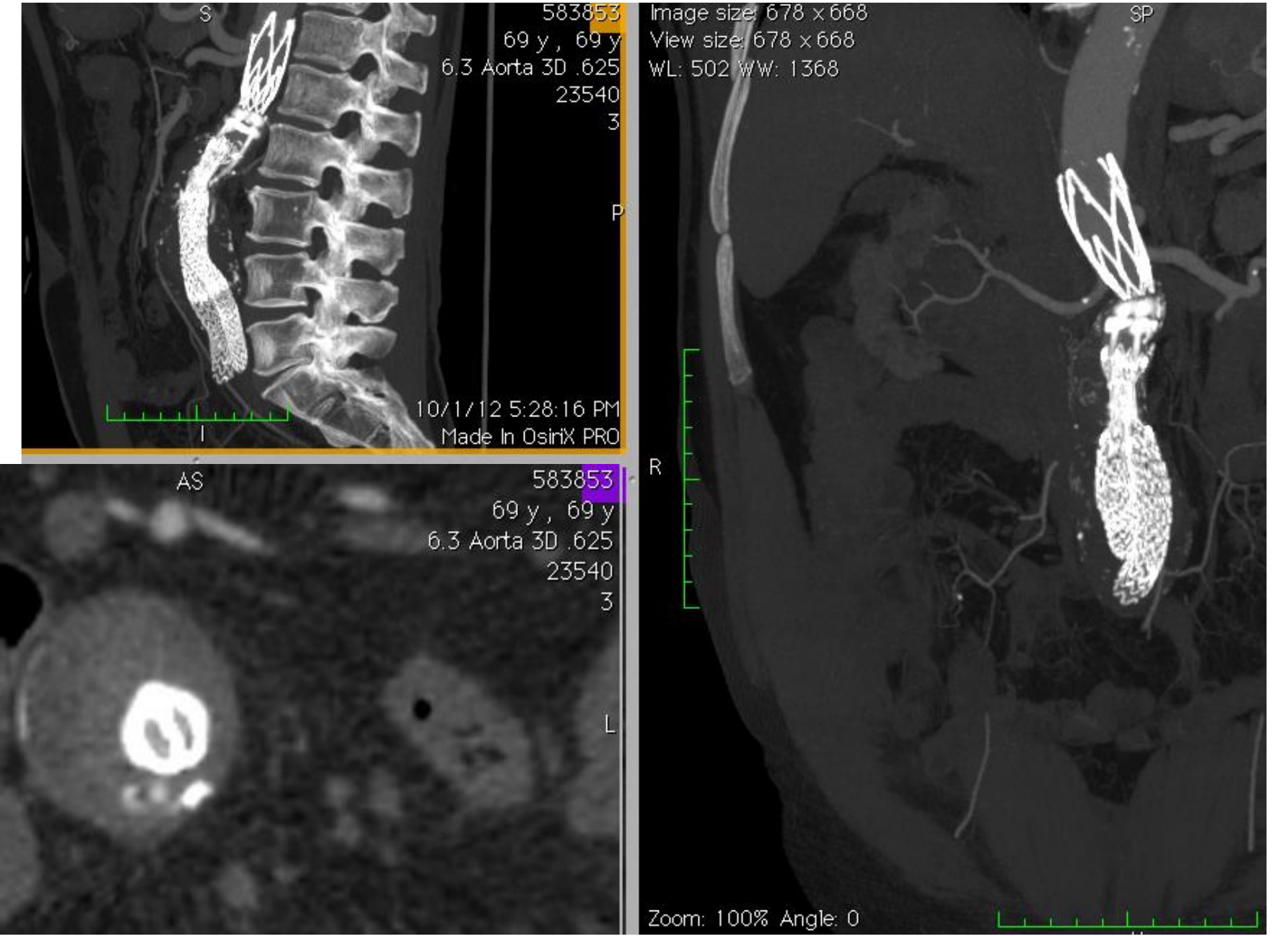
S
583853
69 y , 69 y
6.3 Aorta 3D .625
23540
3
P
I
10/1/12 5:28:16 PM
Made In OsiriX PRO
AS
583853
69 y , 69 y
6.3 Aorta 3D .625
23540
3
L
Image size: 678 x 668
View size: 678 x 668
WL: 502 WW: 1368
SP
R
Zoom: 100% Angle: 0

5 days after …. R-Branch occlusion
→ Recanalization & STENTING

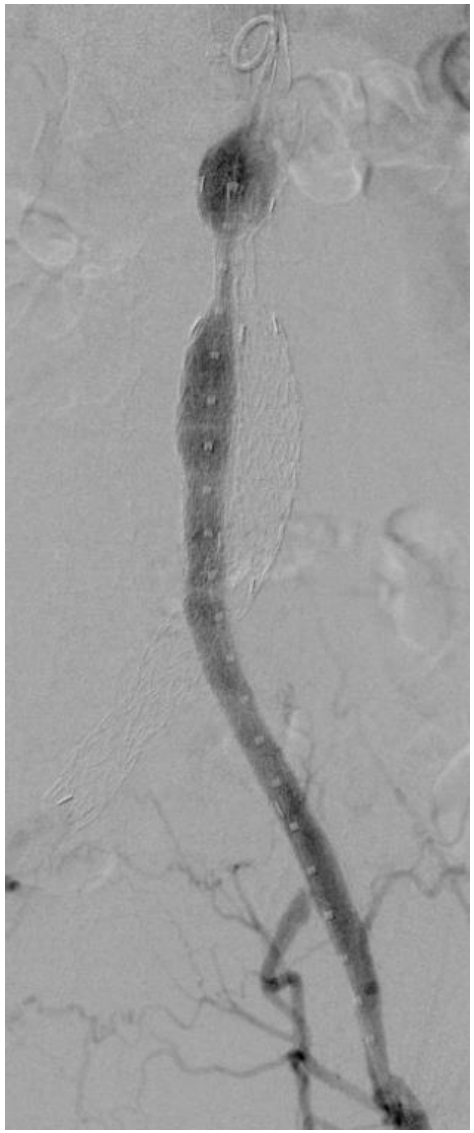

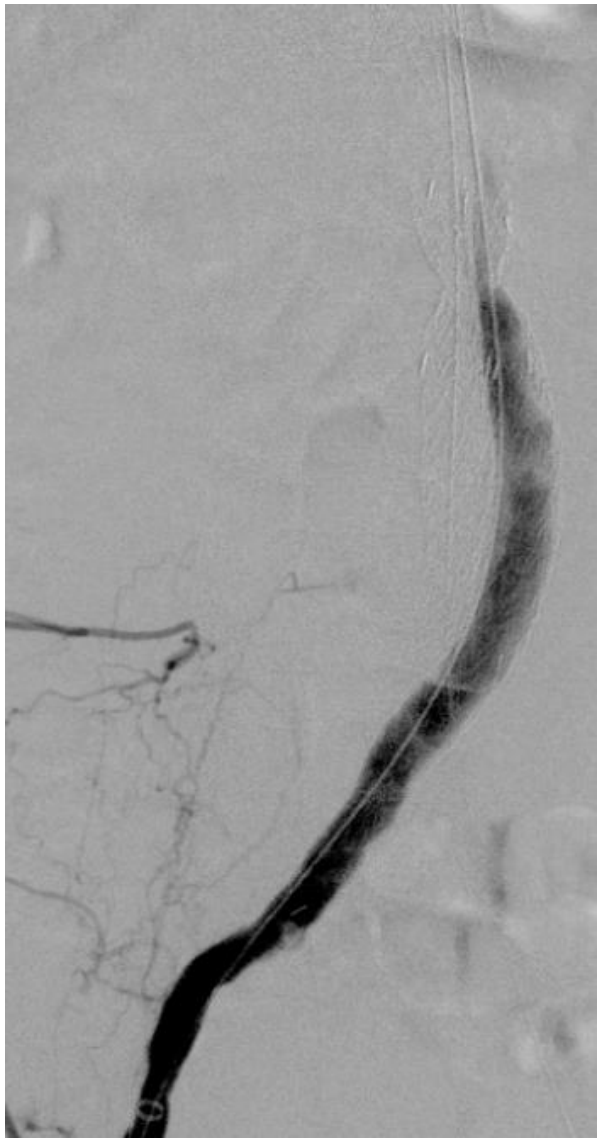

OVATION
Our experience: 69 pts
Immediate results

- Immediate complications

*	– Bleeding	1
	– Polimer extravasation	1
	(allergic reaction – no sequaele)	
	– Endoleak type I	2 *
	– Branch occlusion	1 *

* FIRST OVATION 2010-12

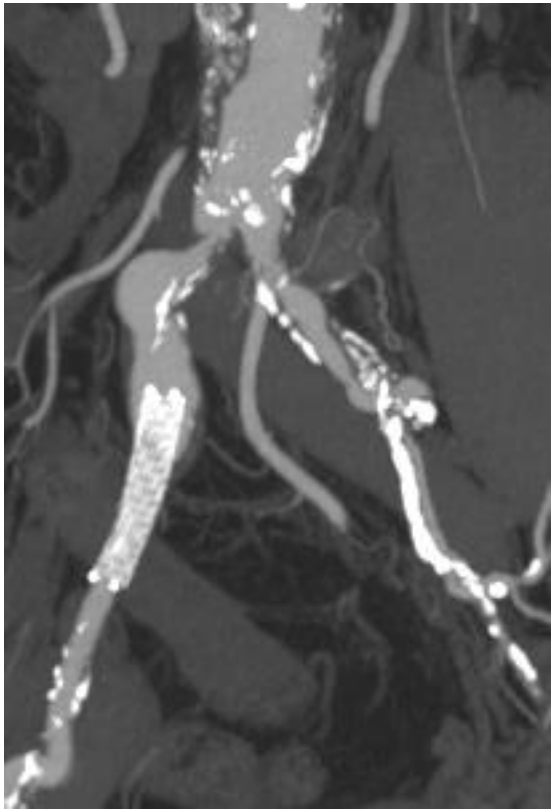

*treated

Personal experience: 69 pts late results
Mean f-up 19 (1-49 mths)

– Death	0
– Type I EL	1 *
– Branch occlusion	1 *

*treated

INCRAFT
Personal experience: 4 pts
Immediate results

- MORTALITY 0
- COMPLICATION 0
- TYPE II EL 1

Percutaneous endovascular aneurysm repair with the ultra-low profile Ovation Abdominal Stent-Graft System

N. MANGIALARDI, S. RONCHEY, H. KASEMI, V. ALBERTI, S. FAZZINI, E. SERRAO

TABLE I.—Patients baseline characteristics

Variable	Value
Patients	35
Age, yr	73±7 (55-84)
Male gender, N. (%)	31 (89)
Maximal aneurysm diameter, mm	52±8 (35-75)
Aortic neck characteristics, mm	
Diameter	23±3 (18-30)
Challenging anatomy	32 (91)
Significant thrombus or calcium	20 (57)
Flare >2 mm	13 (37)
Angulation >45°	8 (23)
Taper >2 mm	1 (3)
Access artery characteristics	
Pre-existing stent	4 (11)
Minimum femoral artery diameter, mm	
Left	7.7±1.7 (4.1-10.9)
Right	7.5±1.6 (4.1-10.0)
Challenging anatomy	27 (77)
Significant calcium / stenosis	15 (43)
Aneurysmal / dissected	14 (40)
Tortuous	12 (34)
Diameter <6 mm	11 (31)

Values are mean±SD (min-max) or N. (%).

100% percutaneous

97% under local anesthesia

TriVascular European LIFE Study

LOW RISK PTS
LOCAL ANESTHESIA
PEVAR
24 HRS HOSPITAL STAY

CONCLUSION

PAVING & CRACKING

“IS NOT NECESSARY ANY MORE WITH THESE NEW LOW PROFILE GRAFT”

TRES BON!!!!