CONTROVERSIES & UPDATES IN VASCULAR SURGERY
JANUARY 22-24 2015
MARRIOTT RIVE GAUCHE & CONFERENCE CENTER PARIS, FRANCE

Infrarenal vs. suprarenal: controversy continues

S Rinckenbach, G Agag

CHRU Besançon
centre hospitalier régional universitaire

Disclosure

.....

- ☐ I have the following potential conflicts of interest to report:
- ☐ Consulting
- ☐ Employment in industry
- ☐ Shareholder in a healthcare company
- ☐ Owner of a healthcare company
- ☐ Other(s)
- ☒ I do not have any potential conflict of interest

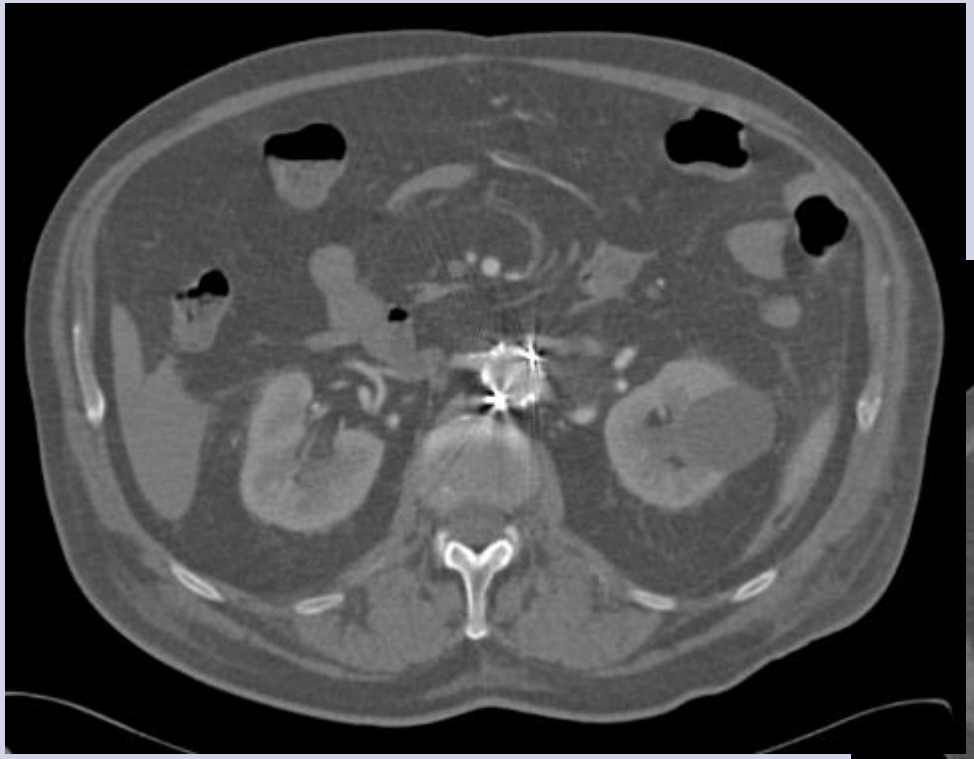

@ 4 years

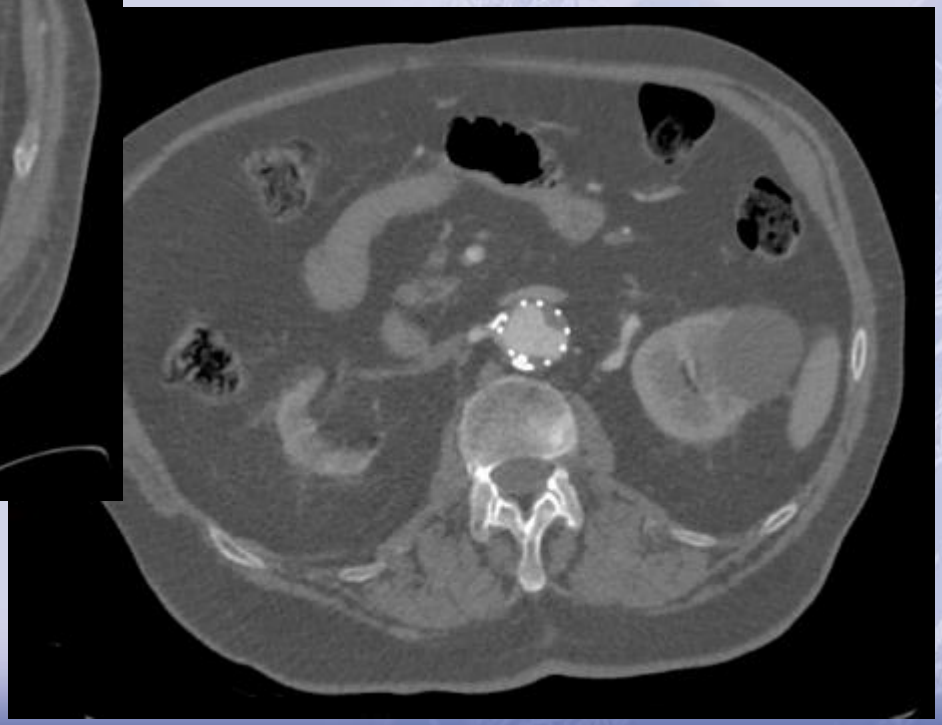

Case report


Taille de l'image : 1024 x 1024
Taille de la vue : 527 x 527
NF : 1415 LF : 2080
unnamed
Zoom : 52% Angle : 0
Im : 40/49
Non compressé
06/11/14 10:34:58
Made in OsiriX

In our every-day practice

- Is suprarenal fixation really safe?
  - Renal function
- Is there any difference?
  - Compare to infrarenal devices

Method

- Objective
  - Comparison infrarenal vs suprarenal devices
  - Renal function @ 12 months
    - Cockroft and Gault Clearance
    - CKD-EPI Clearance
- Retrospective review
- All consecutive endovascular cases
- Only elective surgery
- Sept 2007-jan 2014
  - Both type of devices implanted

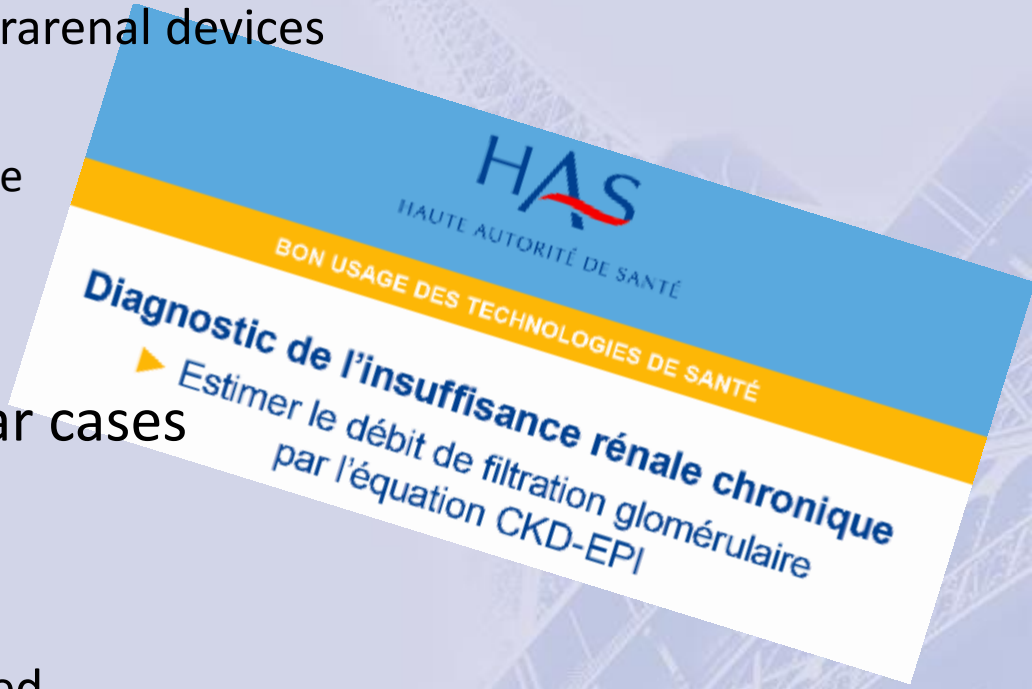

Our population

	Infrarenal fixation (n=45)	Suprarenal fixation (n=63)	P
	n (%)	n (%)	
Anaconda	5 (11.1)		
Endologix	1 (2.2)		
Endurant		33 (52.4)	
Excluder	39 (86.7)		
Talent		8 (12.7)	
Zenith		22 (34.9)	
Male	44 (98)	58 (92)	
Female	1 (2)	5 (8)	.4
Mean age	74 ±9.6	74.4 ±8.7	.8
BMI	27.1 ±5	27.5 ±5	1

Our population

Comorbidities

	Infrarenal fixation (n=45)	Suprarenal fixation (n=63)	p
Lower limb arteriopathy	14 (31)	25 (40)	.4
COPD	19 (42)	29 (46)	.7
Obstructive sleep apnea	6 (13)	12 (19)	.4
Cardiopathy	25 (56)	35 (56)	1
HTA	28 (62)	42 (67)	.6
Diabetes	8 (18)	15 (24)	.4
Dyslipidemia	21 (47)	33 (52)	.6
Smokers	18 (40)*	14 (22)	.04
ASA IV	3 (7)	2 (3)	.8
Statins	22 (49)	43 (68)*	.04
IEC	16 (36)	27 (43)	.4

Our population

Renal factors

	Infrarenal fixation	Suprarenal fixation	P
Nephrectomy	0	1 (2)	.4
Renal Artery Stenosis	0	0	1
Serum Creatinin	95.4 ±28.6	91.6 ±21.6	.4
Cockroft Clearance	75 ±27.6	76.3 ±30.4	.8
CKD-EPI Clearance	70.5 ±17.2	71.5 ±17.6	.8

Our population

Procedures

	Infrarenal fixation	Suprarenal fixation	P
Mean time	102.4 ±48.8	109.1 ±43.1	.4
Contrast product	130.1 ±57.5	103.7 ±35.2*	.006
secondary interventions @12M	6 (13.3)	11 (17.4)	.6

Our population

Renal outcomes

	Infrarenal fixation	Suprarenal fixation	Intergroup Variation
Serum Creatinin			
Preop	95.4 ±28.6	91.6 ±21.6	p=.4
Variation @1M *(p)*	+.2 ±12.4 *(.4)*	+5.3 ±15.8 *(.01)*	
Variation @12M *(p)*	-1.2 ±11.2 *(.4)*	+7 ±13 *(<.0001)*	p=.02
Cockroft and Gault Clearance			
Preop	75 ±27.6	76.3 ±30.4	p=.8
Variation @1M *(p)*	+.6 ±9.1 *(.7)*	-3.1 ±11.3 *(.03)*	
Variation @12M *(p)*	-1.5 ±9.8 *(.3)*	-6.6 ±10.2 *(<.0001)*	p=.01
CKD-EPI Clearance			
Preop	70.5 ±17.2	71.5 ±17.6	p=.8
Variation @1M *(p)*	+.8 ±8.7 *(.6)*	-2.7 ±9.6 *(.03)*	
Variation @12M *(p)*	-.9 ±7.6 *(.4)*	-6 ±9.2 *(<.0001)*	p=.003

Literature

Experimental studies

- Desgranges JVIR 1997
  - Strecker stents (Tantalum)
  - 38% stenosis or occlusion
  - @1 month
  - Overestimation due to histologic method?
- Malina Eur J Vasc Endovasc Surg 1997
  - Palmaz and Gianturco Stents (Stainless steel)
  - No renal flow impairment
  - @7 days
- Birch EJVES 1997
  - Stent type influence
  - Stainless steel > Nitinol

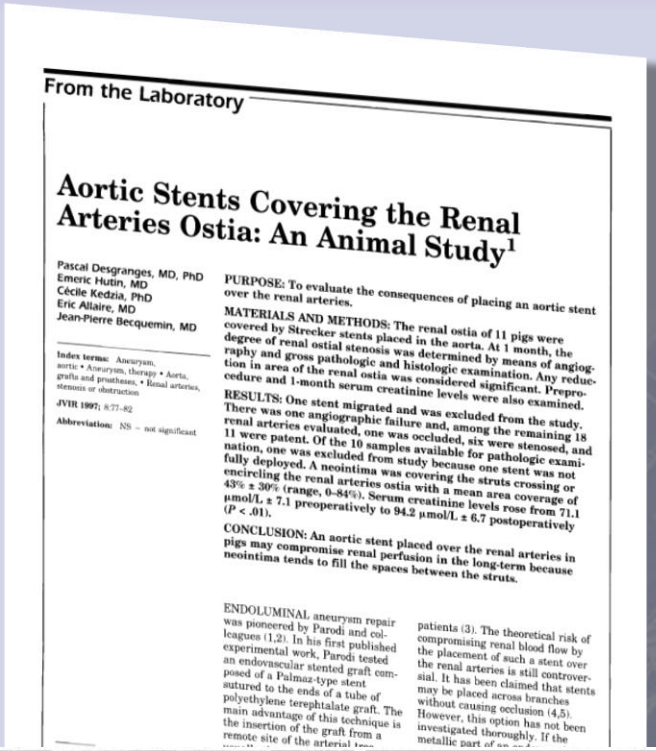

From the Laboratory

Aortic Stents Covering the Renal Arteries Ostia: An Animal Study[1]

Pascal Desgranges, MD, PhD
Emeric Hutin, MD
Cécile Kedzia, PhD
Eric Allaire, MD
Jean-Pierre Becquemin, MD

Index terms: Aneurysm, aortic • Aneurysm, therapy • Aorta, grafts and prostheses, • Renal arteries, stenosis or obstruction

JVIR 1997; 8:77–82

Abbreviation: NS = not significant

PURPOSE: To evaluate the consequences of placing an aortic stent over the renal arteries.

MATERIALS AND METHODS: The renal ostia of 11 pigs were covered by Strecker stents placed in the aorta. At 1 month, the degree of renal ostial stenosis was determined by means of angiography and gross pathologic and histologic examination. Any reduction in area of the renal ostia was considered significant. Preprocedure and 1-month serum creatinine levels were also examined.

RESULTS: One stent migrated and was excluded from the study. There was one angiographic failure and, among the remaining 18 renal arteries evaluated, one was occluded, six were stenosed, and 11 were patent. Of the 10 samples available for pathologic examination, one was excluded from study because one stent was not fully deployed. A neointima was covering the struts crossing or encircling the renal arteries ostia with a mean area coverage of 43% ± 30% (range, 0–84%). Serum creatinine levels rose from 71.1 μmol/L ± 7.1 preoperatively to 94.2 μmol/L ± 6.7 postoperatively ($P < .01$).

CONCLUSION: An aortic stent placed over the renal arteries in pigs may compromise renal perfusion in the long-term because neointima tends to fill the spaces between the struts.

ENDOLUMINAL aneurysm repair was pioneered by Parodi and colleagues (1,2). In his first published experimental work, Parodi tested an endovascular stented graft composed of a Palmaz-type stent sutured to the ends of a tube of polyethylene terephtalate graft. The main advantage of this technique is the insertion of the graft from a remote site of the arterial tree

patients (3). The theoretical risk of compromising renal blood flow by the placement of such a stent over the renal arteries is still controversial. It has been claimed that stents may be placed across branches without causing occlusion (4,5). However, this option has not been investigated thoroughly. If the metallic part of an end

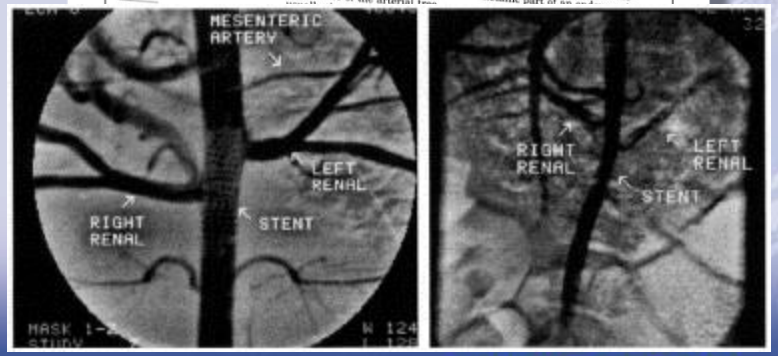

Literature

First clinical experiences

- Malina Eur J Vasc Endovasc Surg 1997
  - 18 patients
  - @ 6 months
  - No Serum creatinin variation
- Walker J Endovasc Surg 1998
  - 164 patients
  - 140 suprarenal fixation
    - No impact

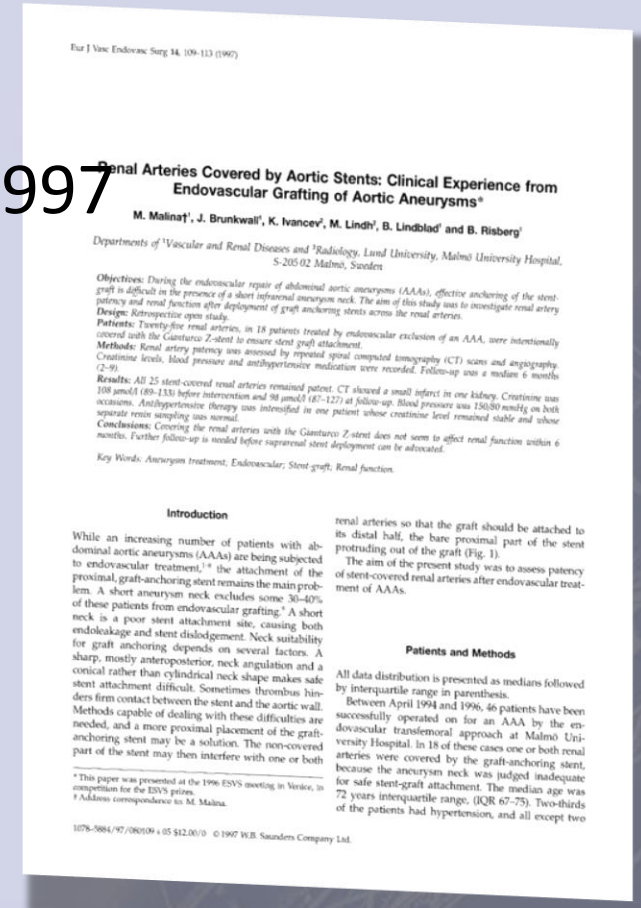

Eur J Vasc Endovasc Surg 14, 109–113 (1997)

Renal Arteries Covered by Aortic Stents: Clinical Experience from Endovascular Grafting of Aortic Aneurysms*

M. Malina†[1], J. Brunkwall[1], K. Ivancev[2], M. Lindh[2], B. Lindblad[1] and B. Risberg[1]

Departments of [1]Vascular and Renal Diseases and [2]Radiology, Lund University, Malmö University Hospital, S-205 02 Malmö, Sweden

Objectives: *During the endovascular repair of abdominal aortic aneurysms (AAAs), effective anchoring of the stent-graft is difficult in the presence of a short infrarenal aneurysm neck. The aim of this study was to investigate renal artery patency and renal function after deployment of graft anchoring stents across the renal arteries.*
Design: *Retrospective open study.*
Patients: *Twenty-five renal arteries, in 18 patients treated by endovascular exclusion of an AAA, were intentionally covered with the Gianturco Z-stent to ensure stent graft attachment.*
Methods: *Renal artery patency was assessed by repeated spiral computed tomography (CT) scans and angiography. Creatinine levels, blood pressure and antihypertensive medication were recorded. Follow-up was a median 6 months (2–9).*
Results: *All 25 stent-covered renal arteries remained patent. CT showed a small infarct in one kidney. Creatinine was 108 μmol/l (89–133) before intervention and 98 μmol/l (87–127) at follow-up. Blood pressure was 150/90 mmHg on both occasions. Antihypertensive therapy was intensified in one patient whose creatinine level remained stable and whose separate renin sampling was normal.*
Conclusions: *Covering the renal arteries with the Gianturco Z-stent does not seem to affect renal function within 6 months. Further follow-up is needed before suprarenal stent deployment can be advocated.*

Key Words: Aneurysm treatment; Endovascular; Stent-graft; Renal function.

Introduction

While an increasing number of patients with abdominal aortic aneurysms (AAAs) are being subjected to endovascular treatment,[1–8] the attachment of the proximal, graft-anchoring stent remains the main problem. A short aneurysm neck excludes some 30–40% of these patients from endovascular grafting.[9] A short neck is a poor stent attachment site, causing both endoleakage and stent dislodgement. Neck suitability for graft anchoring depends on several factors. A sharp, mostly anteroposterior, neck angulation and a conical rather than cylindrical neck shape makes safe stent attachment difficult. Sometimes thrombus hinders firm contact between the stent and the aortic wall. Methods capable of dealing with these difficulties are needed, and a more proximal placement of the graft-anchoring stent may be a solution. The non-covered part of the stent may then interfere with one or both renal arteries so that the graft should be attached to its distal half, the bare proximal part of the stent protruding out of the graft (Fig. 1).

The aim of the present study was to assess patency of stent-covered renal arteries after endovascular treatment of AAAs.

Patients and Methods

All data distribution is presented as medians followed by interquartile range in parenthesis.

Between April 1994 and 1996, 46 patients have been successfully operated on for an AAA by the endovascular transfemoral approach at Malmö University Hospital. In 18 of these cases one or both renal arteries were covered by the graft-anchoring stent, because the aneurysm neck was judged inadequate for safe stent-graft attachment. The median age was 72 years interquartile range, (IQR 67–75). Two-thirds of the patients had hypertension, and all except two

* This paper was presented at the 1996 ESVS meeting in Venice, in competition for the ESVS prizes.
† Address correspondence to M. Malina.

1078–5884/97/080109 + 05 $12.00/0

Literature

« Cockroft review »

2001-2008

First Author	Year of publication	Type of study	Mean follow up	Supra renal cases	Infrarenal cases	Open repair	Serum Creatinin	Cockroft-Gault clearance	MDRD	CKD-EPI	preop-after F/U difference
Izzedine	2001	Retrospective	30	15	0	0	☑	☑	☐	☐	NS
Lau	2003	Retrospective	12	32	57	0	☑	☐	☐	☐	NS
Alric	2003	Registry	18(SR)/36 (IR)*	169	146	0	☑	[illegible]	☐	☐	NS
Cayne	2003	Retrospective	17	69	61	[illegible]	[illegible]	[illegible]	☐	☐	S (intragroup)
Greenberg	2004	Registry	NA	351	[illegible]	[illegible]	[illegible]	[illegible]	☐	☐	NS
Surowiec	2004	Retrospective	22	[illegible]	[illegible]	[illegible]	[illegible]	[illegible]	[illegible]	☐	NS
Alsac	2005	Retrospective	[illegible]	[illegible]	[illegible]	[illegible]	[illegible]	[illegible]	☐	☐	NS
England	2006	[illegible]	[illegible]	[illegible]	[illegible]	[illegible]	[illegible]	☑	☐	☐	NS
Forbes	2006	[illegible]	[illegible]	[illegible]	[illegible]	[illegible]	☑	☑	☐	☐	NS
Davey	2006	[illegible]	[illegible]	[illegible]	[illegible]	0	☑	☑	☐	☐	NS
Parmer	2006	[illegible]	[illegible]	79	147	0	☑	☑	☐	☐	S (intragroup)
Waasdorp	2007	[illegible]rospective	12	119	190	0	☑	☑	☐	☐	S (intragroup)
Mills	2008	Retrospective	24(SR)/20 (OR)	113*		120	☑	☑	☐	☐	S
O'Donnell	2007	Prospective	52	29	0	0	☑	☑	☐	☐	NS
Davey	2008	Prospective	12	28	0	24	☑	☑	☐	☐	NS
Garcia	2008	Retrospective	20(SR)/36 (OR)	160	0	59	☑	☑	☐	☐	NS
Gawenda	2008	Prospective	NA	84*	60	229	☑	☑	☐	☐	S

Meta-analysis : Walsh J Vasc Surg 2008
« currently data are insufficient…. »
« …suprarenal fixation increased the risk of renal dysfunction… study heterogeneity… »

Literature

« MDRD / CKD-EPI review »

2012-2014

First Author	Year of publication	Type of study	Mean follow up	Supra renal cases	Infrarenal cases	Open repair	Serum Creatinin	Cockroft-Gault clearance	MDRD	CKD-EPI	preop-after F/U difference
Saratzis	2012	nested case-control analysis	12	46*	46	0	☐	☐	☑	☐	S
Pisimisis	2012	Retrospective	6	110	98	0	☐	☐	☑	☐	NS
de Bruin	2013	Retrospective	60	95		94	☐	☐	☑	☑	NS
Saratzis	2014	nested case-control analysis	24	90*	90	45*	☐	☐	☐	☑	S

- Saratzis J Vasc Surg 2012&2014
  - Nested case control study
  - EVAR supra & infrarenal matched with open repairs
    - 90 SR- 90 IR- 45 OR
  - 24 months f/u
  - CKD-EPI

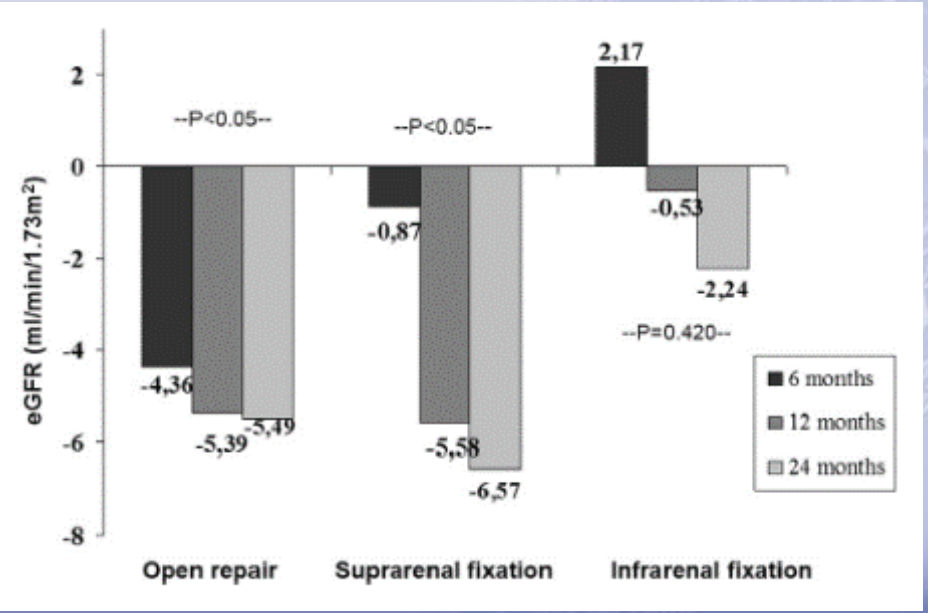

Enough Evidence?

- Avoiding suprarenal fixation?
- Advantages
  - Prevention of migration
  - Short neck
  - Angulated neck
  - Emergency cases
- Confounding factors
  - Iodinated contrast product repeated
  - Age
  - Weight
  - …

NO!

So what?

- Specific survey for suprarenal?
- ESSEA
  - Duplex scan versus CT
- Follow up by Duplex scan
  - Avoiding iodinated product contrast
  - Assessment renal artery
- Renal function survey
- Infrarenal fixation
  - Renal impairment
  - Validated morphology

CHRU Besançon
centre hospitalier régional universitaire