Compression of the Left Common Iliac Vein: an Algorithm for Diagnosis by Duplex

Olivier Pichot

Disclosure


I DO NOT HAVE ANY POTENTIAL CONFLICT OF INTEREST...
FOR THIS PRESENTATION!

May Thurner Syndrome: Anatomy

Figure 5. Left common iliac vein compression by the right common iliac artery. Chronic changes in the left common iliac vein secondary to endothelial damage with (a) intraluminal spurs, (b) webs and (c) channels are depicted.

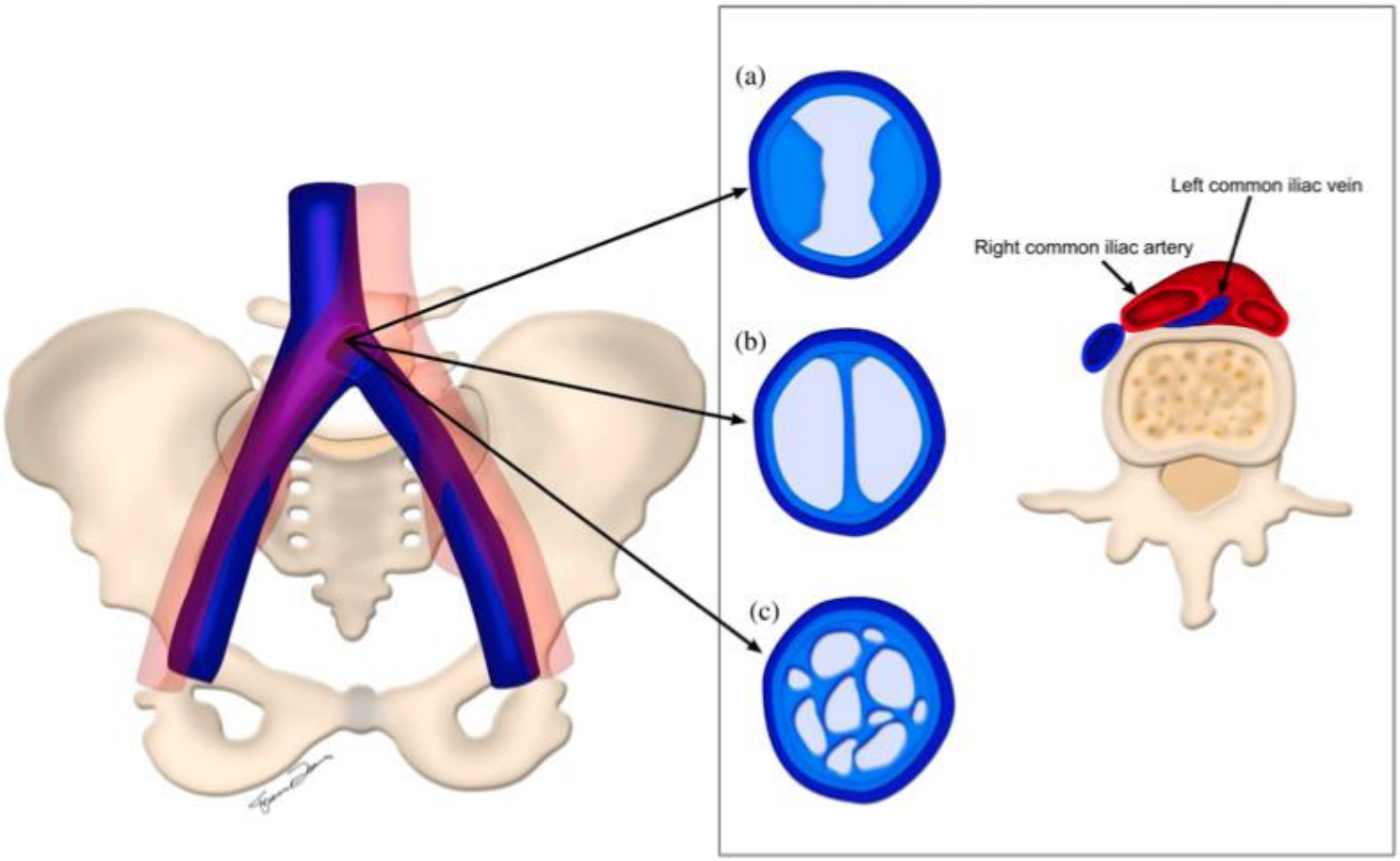

Boutros S et al. Venous compression syndromes: clinical features, imaging findings and management. BJR 2014

May Thurner Syndrome: Clinical Presentation

- **Iliac vein thrombosis**
  - Acute
  - Sequelae (post thrombotic syndrome)
- **Venous hypertension**
  - Venous claudication
  - Edema
  - (Varicose vein)
- **Asymptomatic**

~~Radiologist~~ Commun Point of View

Imaging findings

Doppler ultrasound is accurate in identifying the presence of DVT in the lower extremity; however, iliac vein thrombosis may be technically challenging to depict and compressibility may not be possible to assess [42]. Lack of respiratory variations and the absence of response to Valsalva manoeuvre in the common femoral vein could be a sign of more proximal compression or obstruction (Figure 6).

Boutros S et al. Venous compression syndromes: clinical features, imaging findings and management. BJR 2014

Advanced non-invasive diagnostic testing

A number of physiological tests and imaging modalities have been used to evaluate patients for obstruction of the iliac vein outflow tract. Trans-abdominal duplex ultrasound is often unable to visualize the iliac vein with sufficient diagnostic accuracy due to overlying bowel gas and the vein's depth within the pelvis.

Birn J et al. May–Thurner syndrome and other obstructive iliac vein lesions: Meaning, myth, and mystery Vasc Medicine 2014

Iliac veins

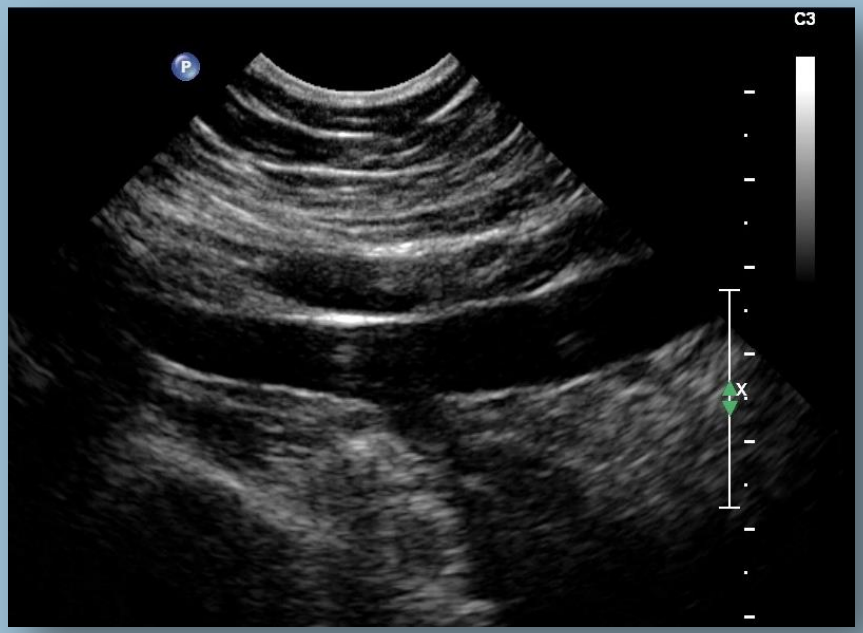

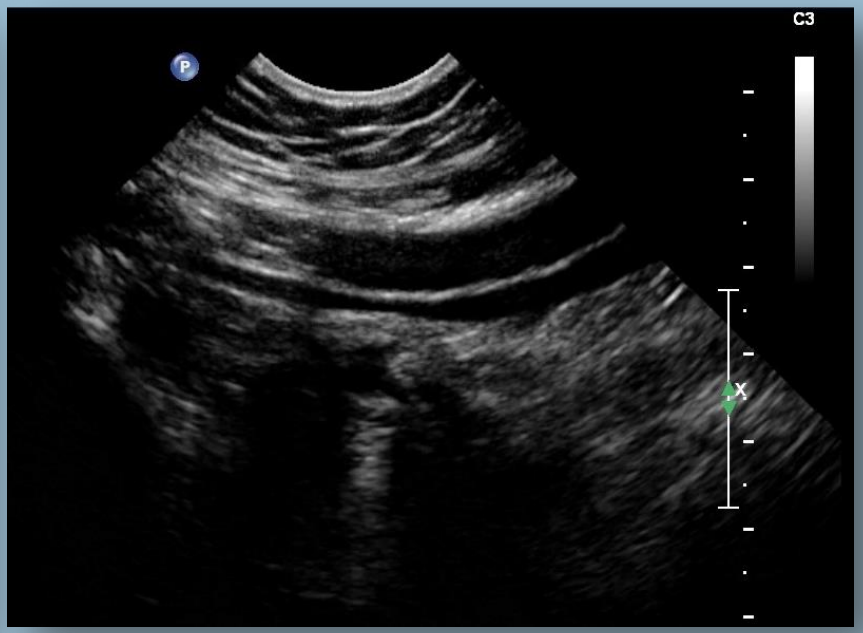

- B mode offers often a good visualization
- Compression maneuver can often be achieved

Iliac veins: difficult cases

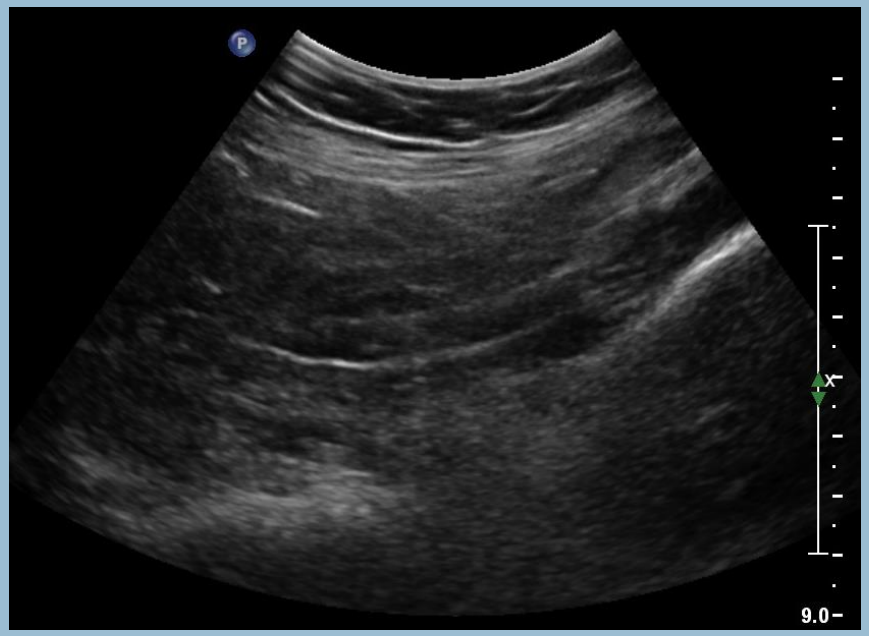

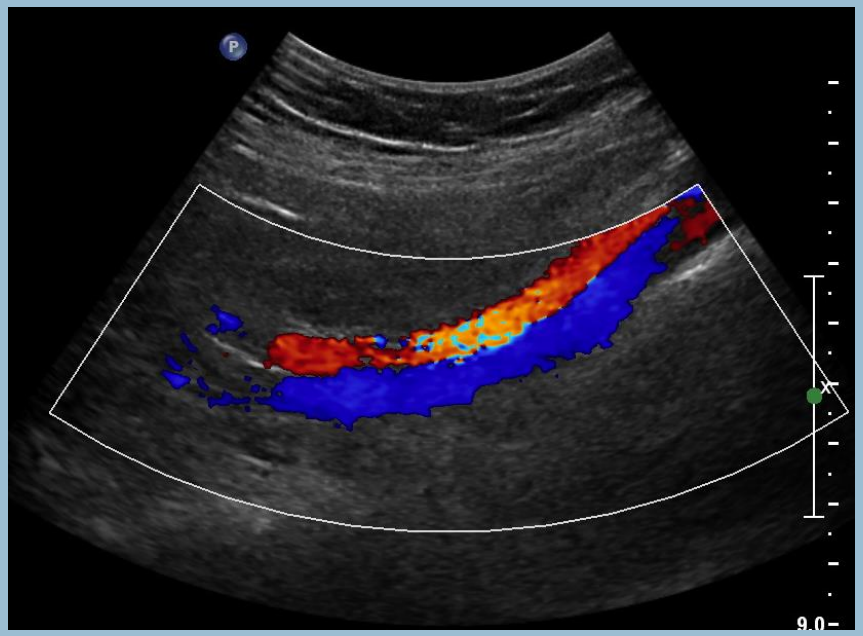

💡 Use color doppler and augmentation maneuver

Iliac veins: difficult cases

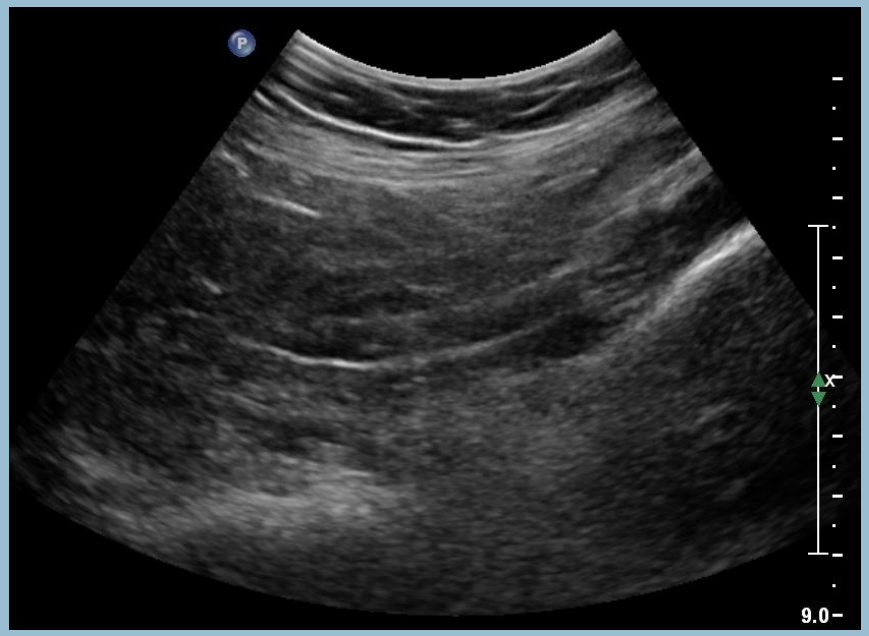

💡 Use harmonic imaging

Left primitive iliaque v. termination

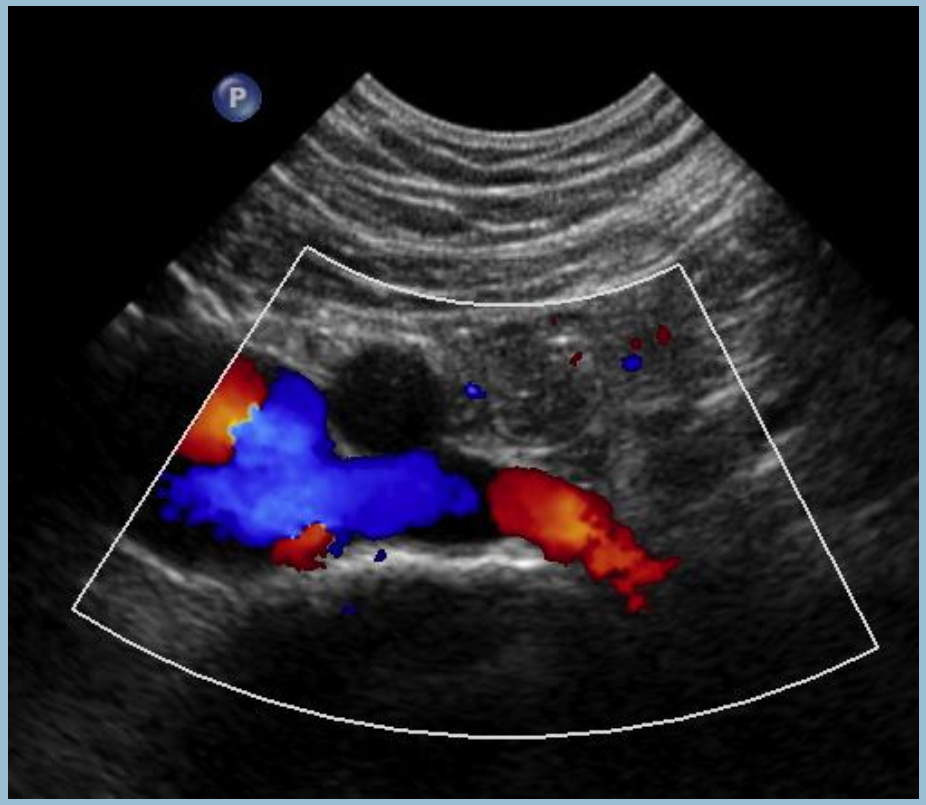

Acute Left Iliac Vein Thrombosis

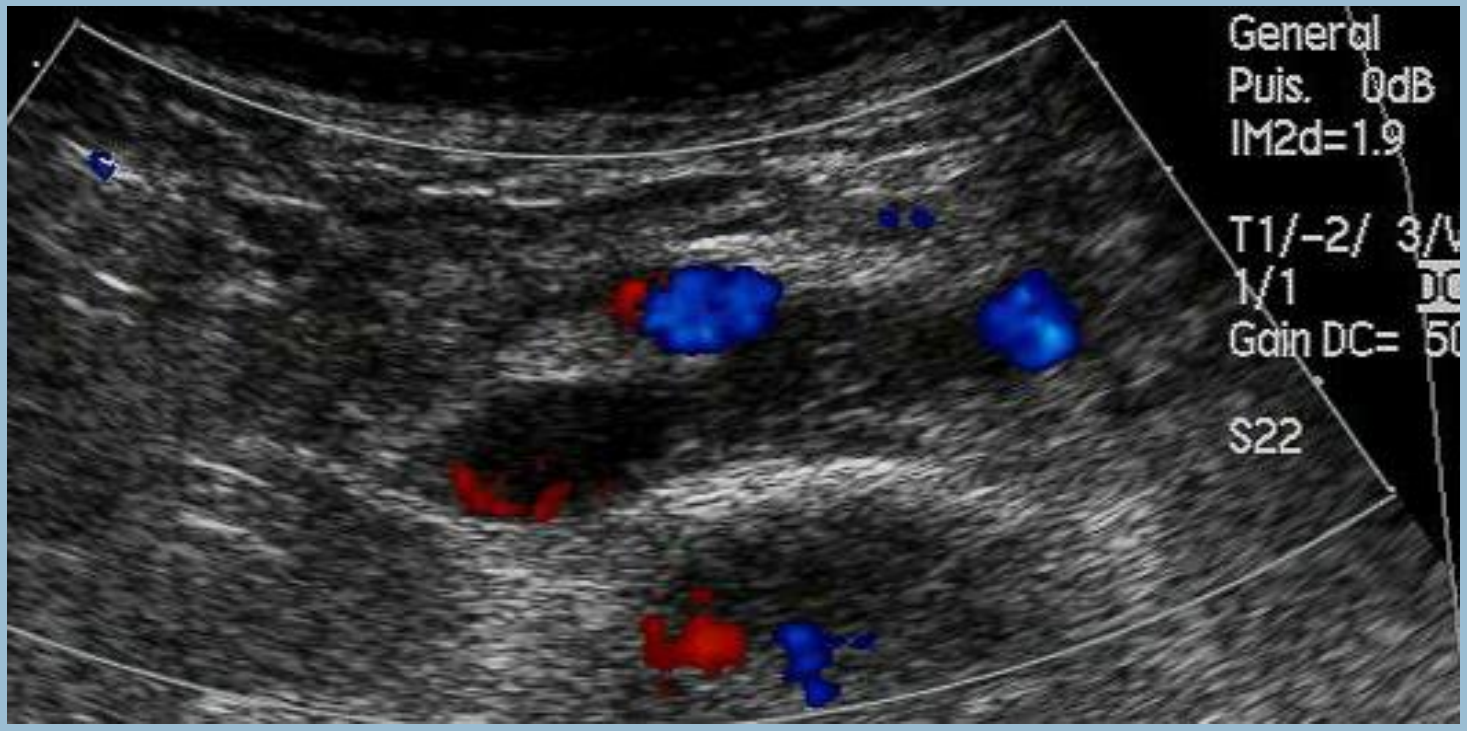

0.8% of all DVT

9.4% in : Females, age < 35 years, PE suspicion

Barrelier MT et al. Thromboses veineuses profondes iliaques isolées. Etude de 48 cas recueillis en 7 ans parmi 18 297 explorations écho-doppler des membres inférieurs. JVS 2011

Left Iliac vein thrombosis: Sequelae

- Iliac vein shrinkage and CDU filling defect

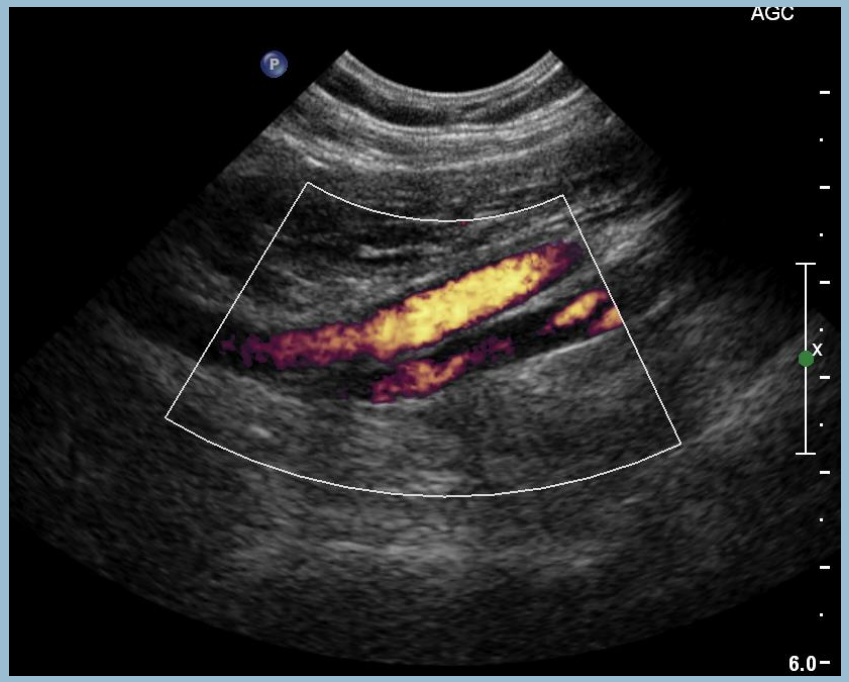

Left iliac vein

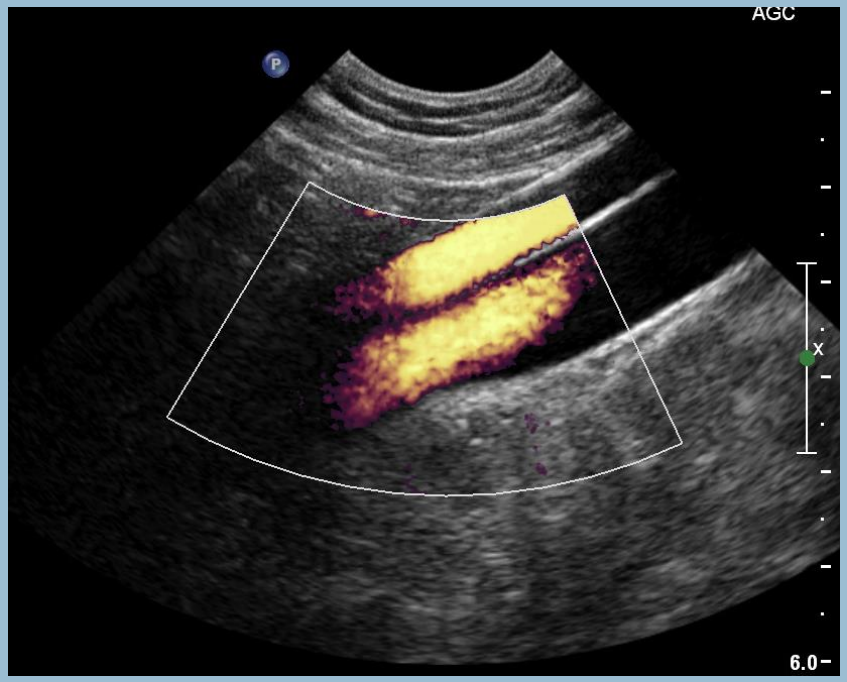

Right iliac vein

MTS: Invasive Examination Technics

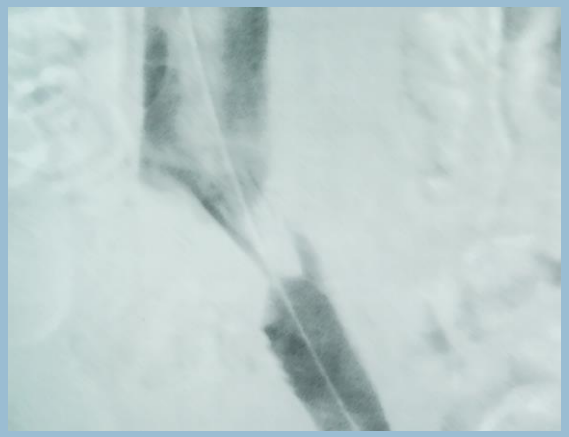

Venography

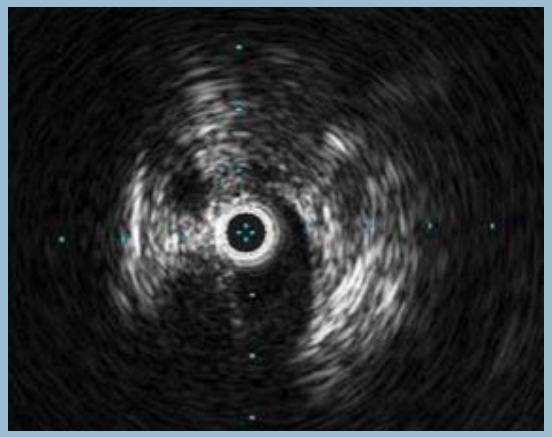

IVUS

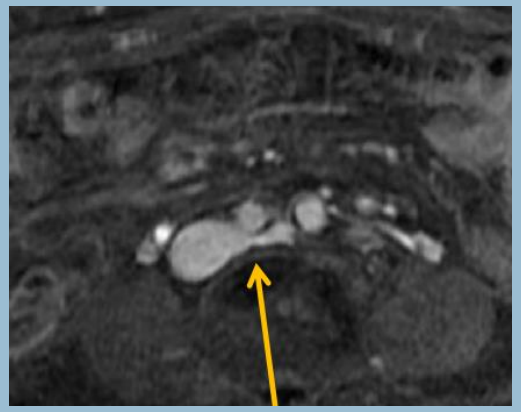

CT venography

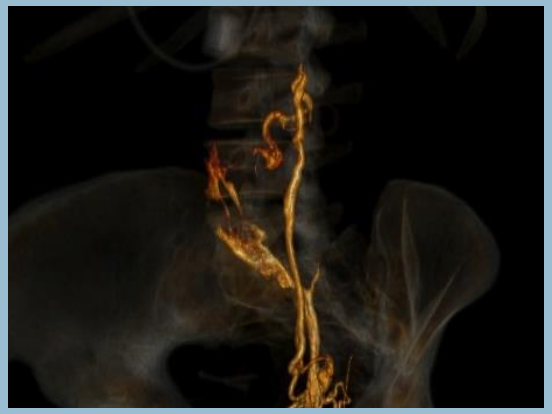

CT venography

MR venography

Calculation of a degree of stenosis based on the AP diameter of the LIV

- CT scan retrospective study (300 patients)

Table 1. Comparison of iliac vein diameter measurements.

	Relative to ipsilateral distal segments			Relative to RCIV at the same level		
Severity of stenosis	No. of patients	Percentage	Cumulative percentage	No. of patients	Percentage	Cumulative percentage
≥90%	12	4.0	4.0	5	1.7	1.7
80–90%	22	7.3	11.3	21	7.0	8.7
70–79%	25	8.3	19.7	22	7.3	16.0
60–69%	44	14.7	34.3	30	10.0	26.0
50–59%	31	10.3	44.7	32	10.7	36.7
<50%	166	55.3	100.0	190	63.3	100.0

19.6

16

- No difference in the mean percentage of stenosis between patients with and without various signs and symptoms of IVS.

Nazzal et al. Incidence and clinical significance of iliac vein compression Vascular 2014

Incidence of LIV Compression in Asymptomatic Patients

- CT scan retrospective study
- 50 asymptomatic patients

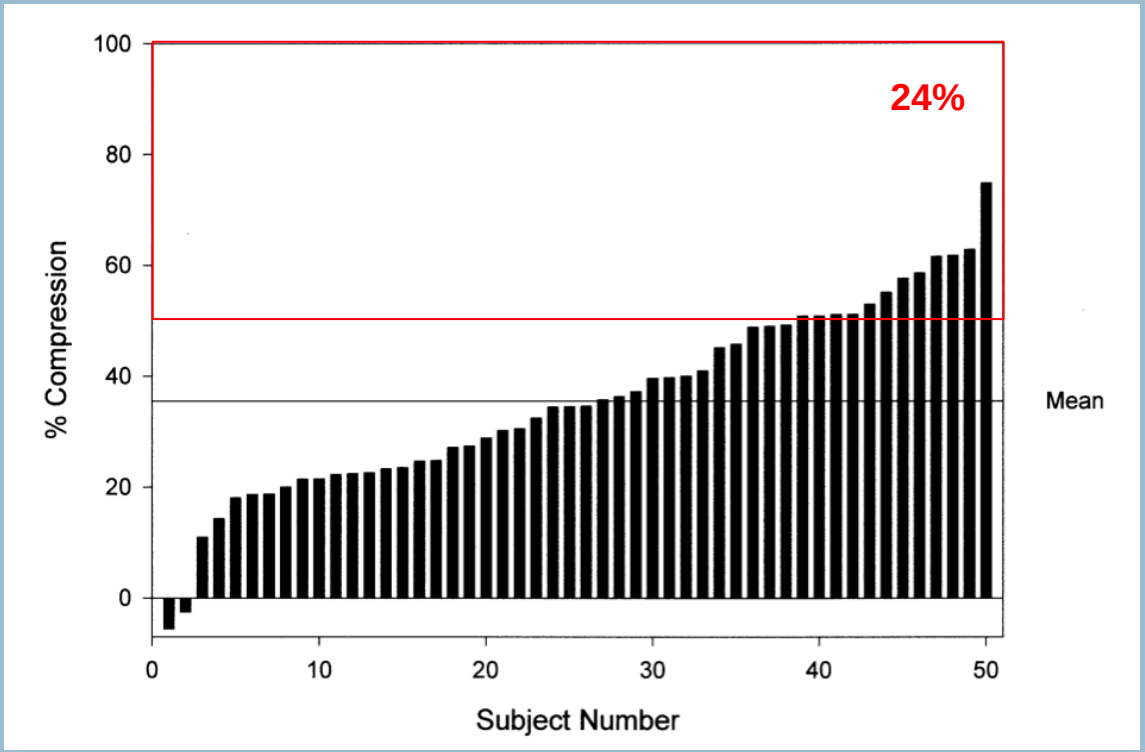

35.5 ± 2.5 %

Kibbe et al. Iliac vein compression in an asymptomatic patient population. JVS 2014

Ultrasound
LCIV Diameter Measurement

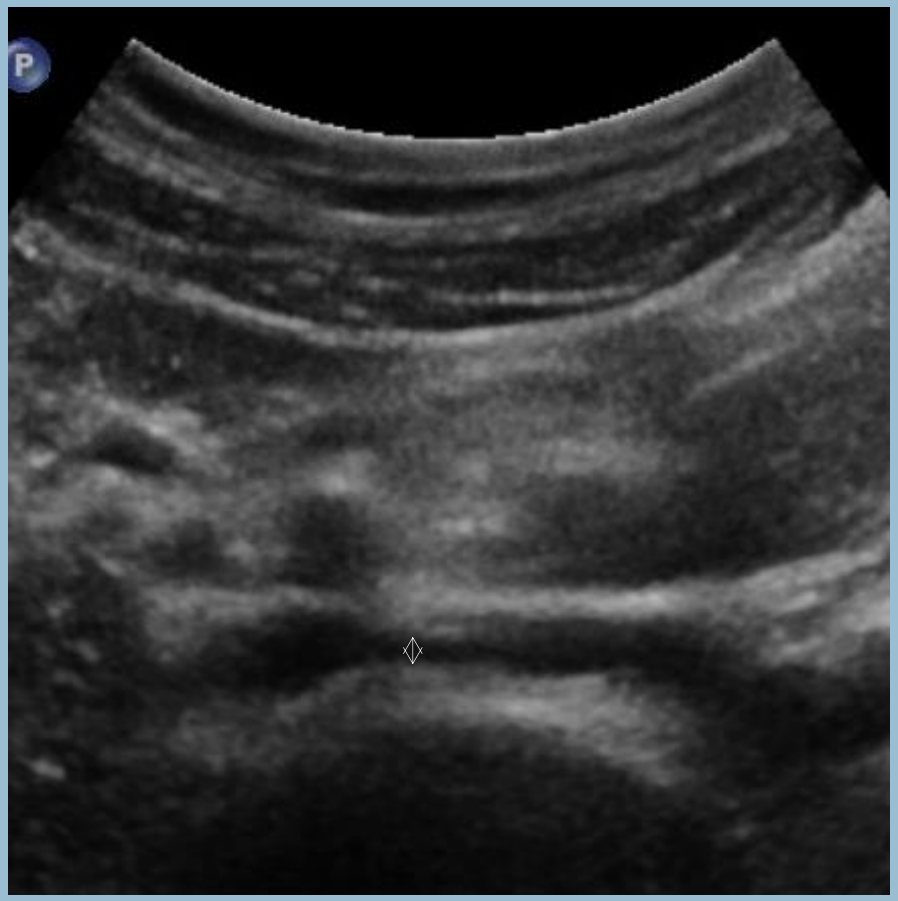

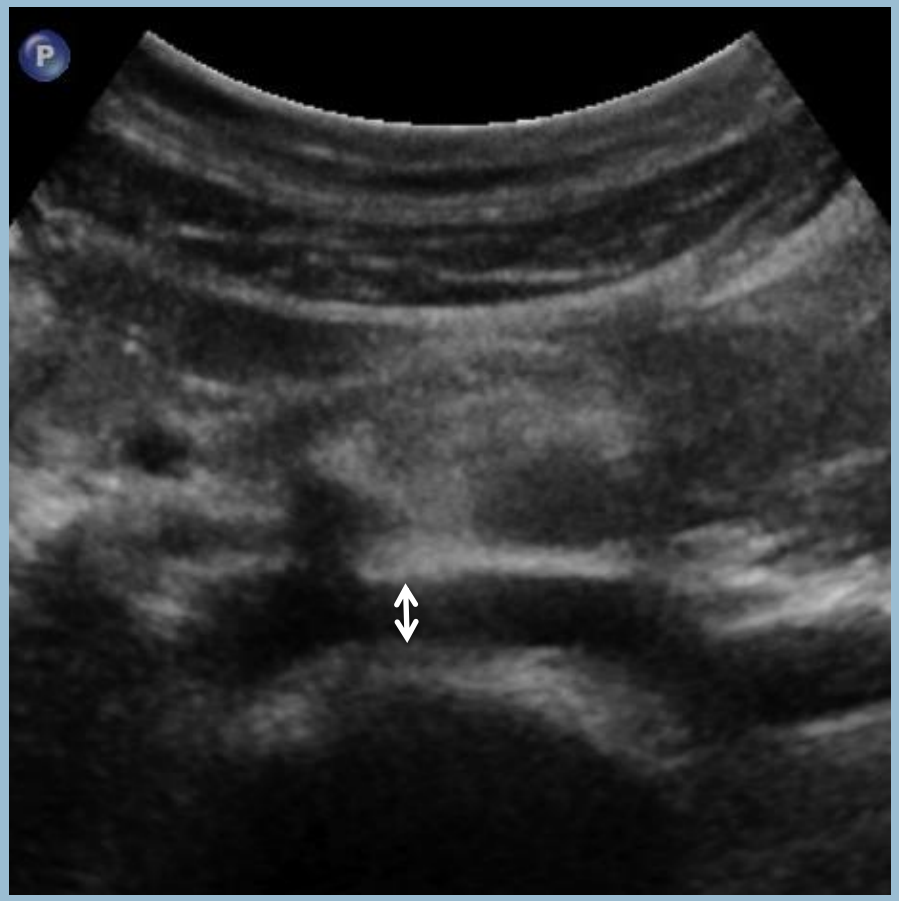

Ultrasound
LCIV Diameter Measurement

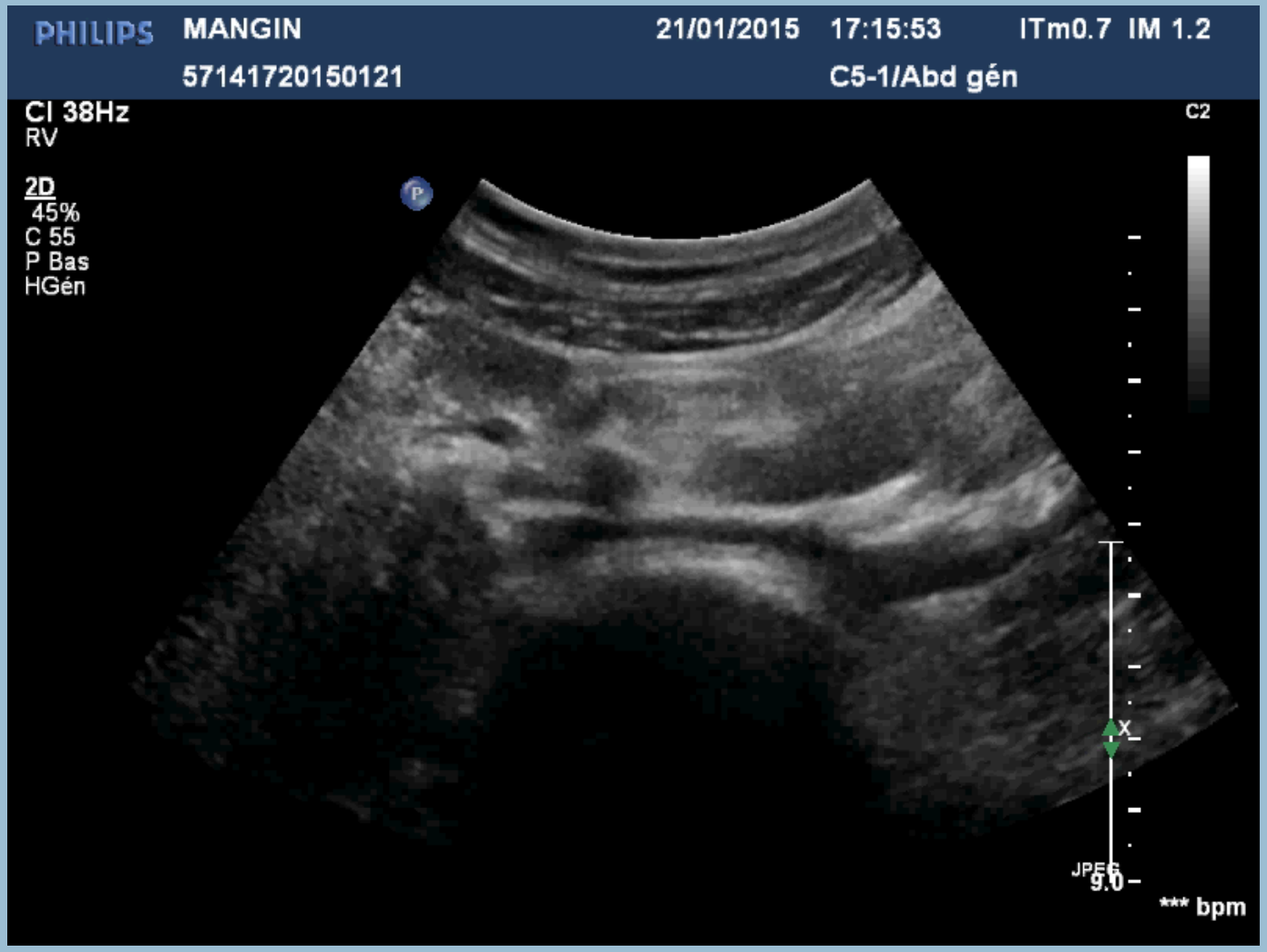

LIV: Respiration Variation

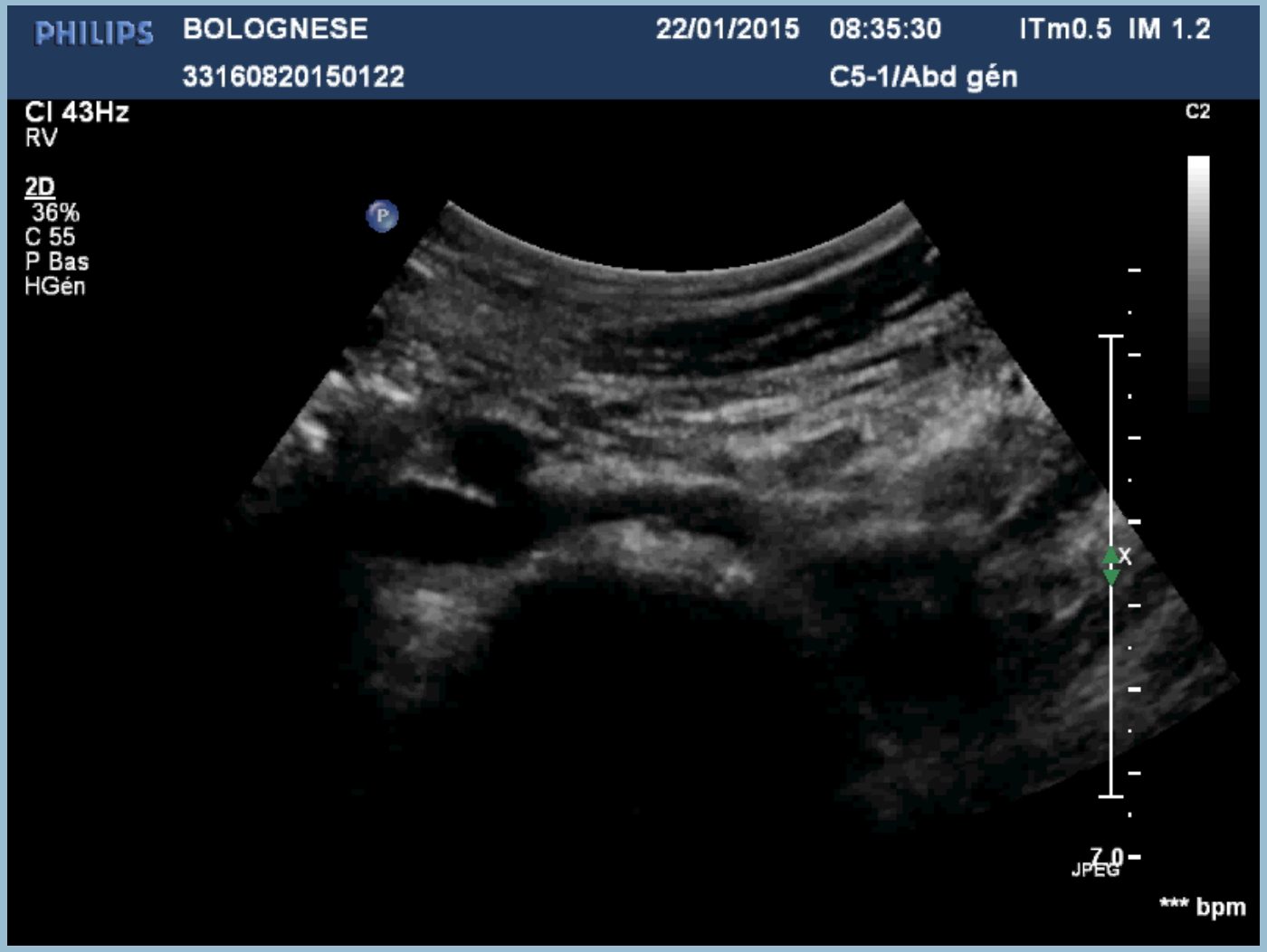

LIV: Valsala

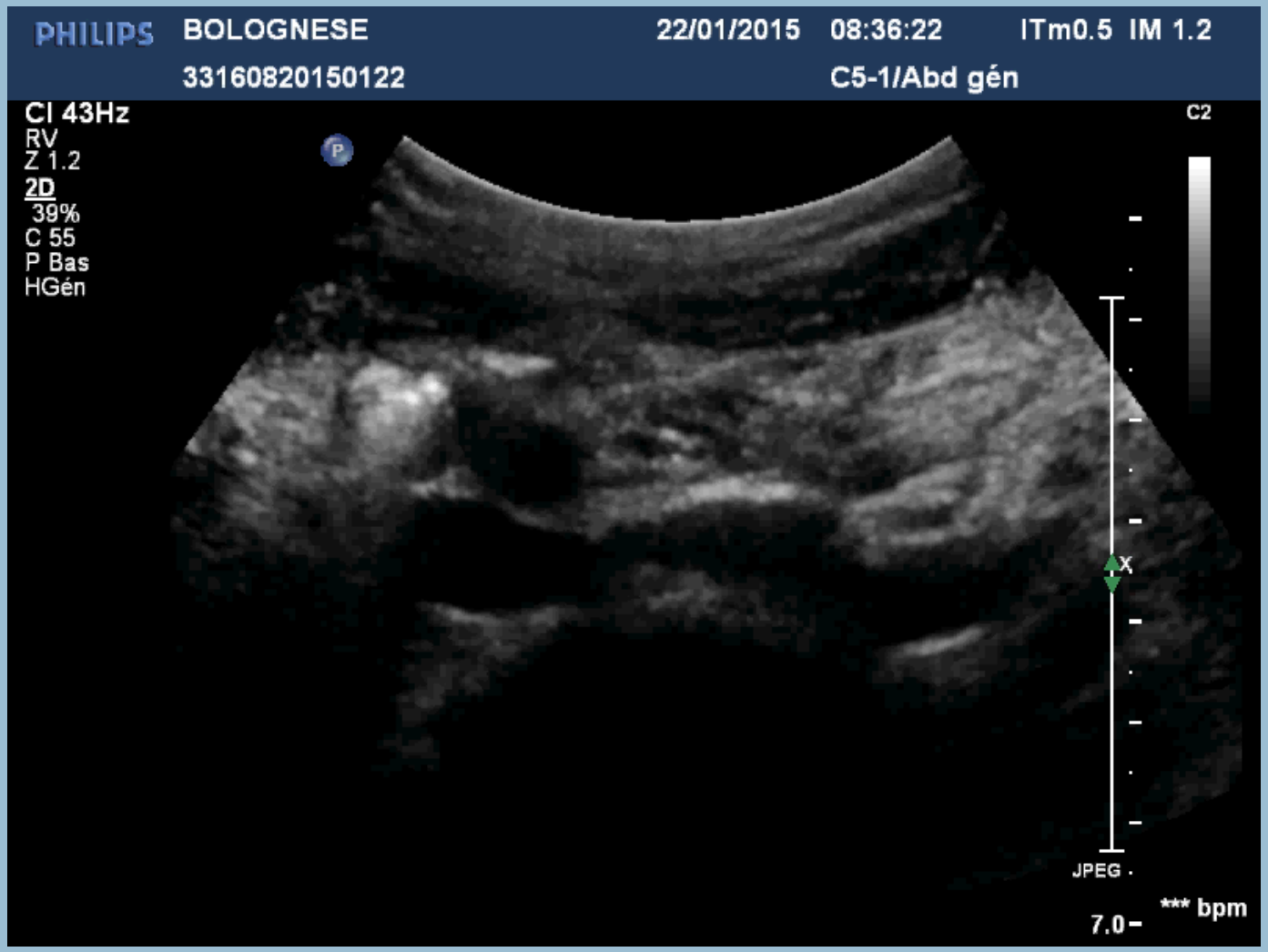
PHILIPS
BOLOGNESE
22/01/2015
08:36:22
ITm0.5 IM 1.2
33160820150122
C5-1/Abd gén
CI 43Hz
RV
Z 1.2
2D
39%
C 55
P Bas
HGén
C2
JPEG
7.0
*** bpm

Section Measurement Methodology

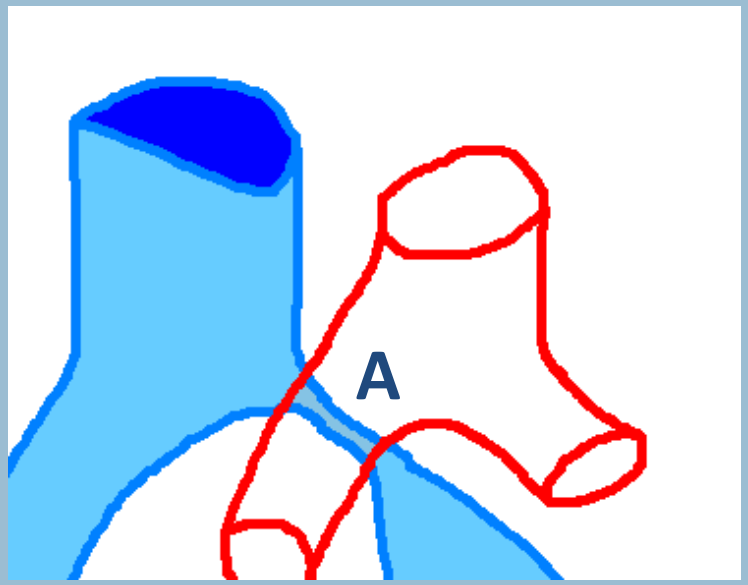

A: ↘ diameter



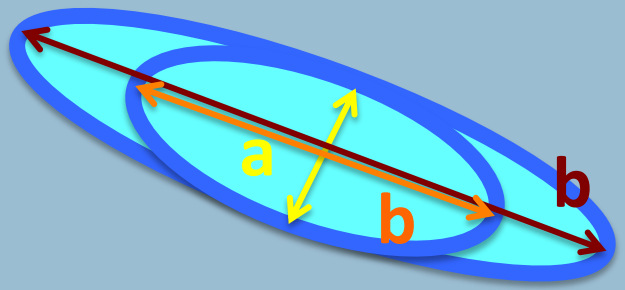

Section area = a x b x Π

Diameter Measurement Limitation

Valsalva maneuver

Diameter

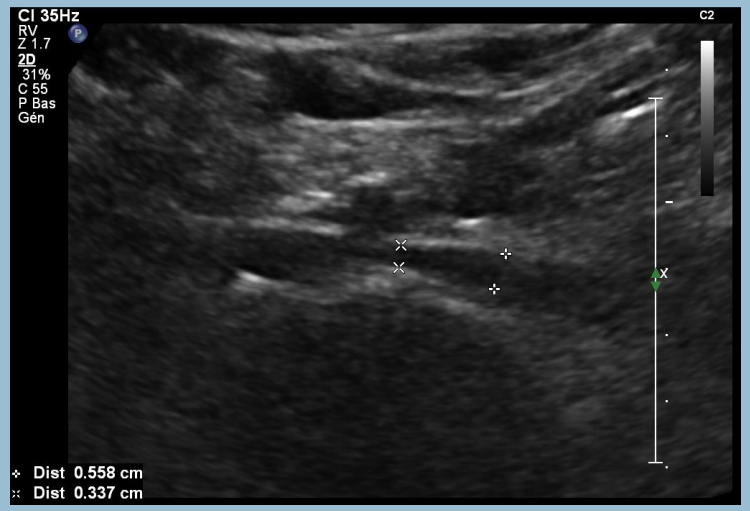

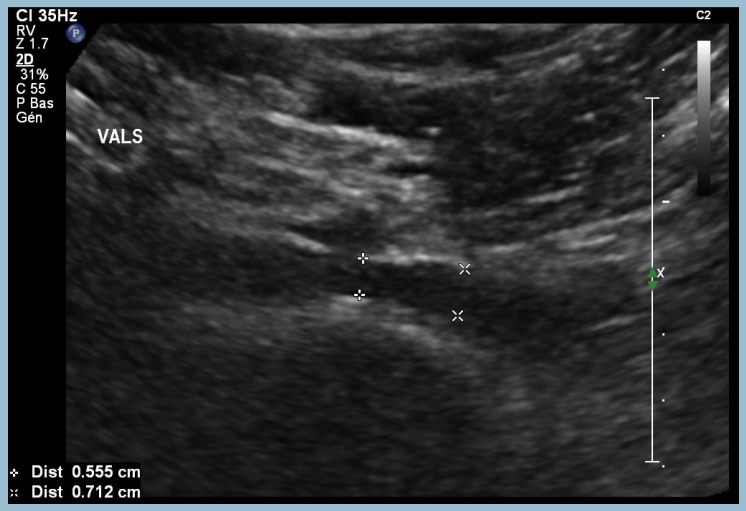

Section

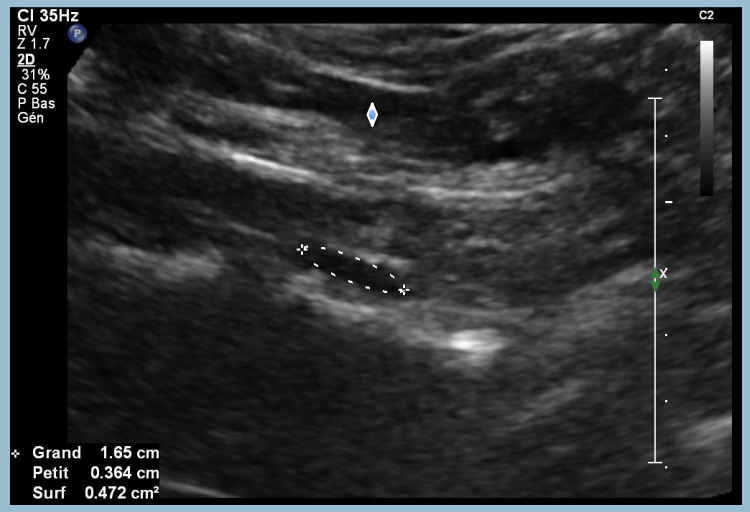

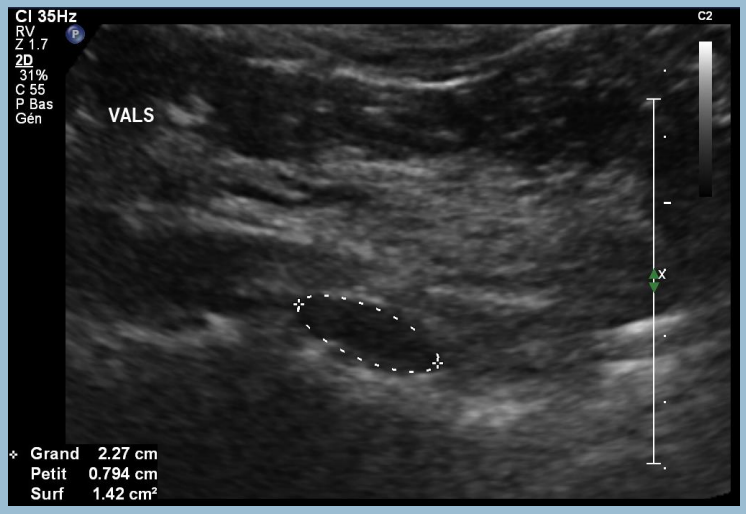

MTS: Duplex Anatomy Analysis

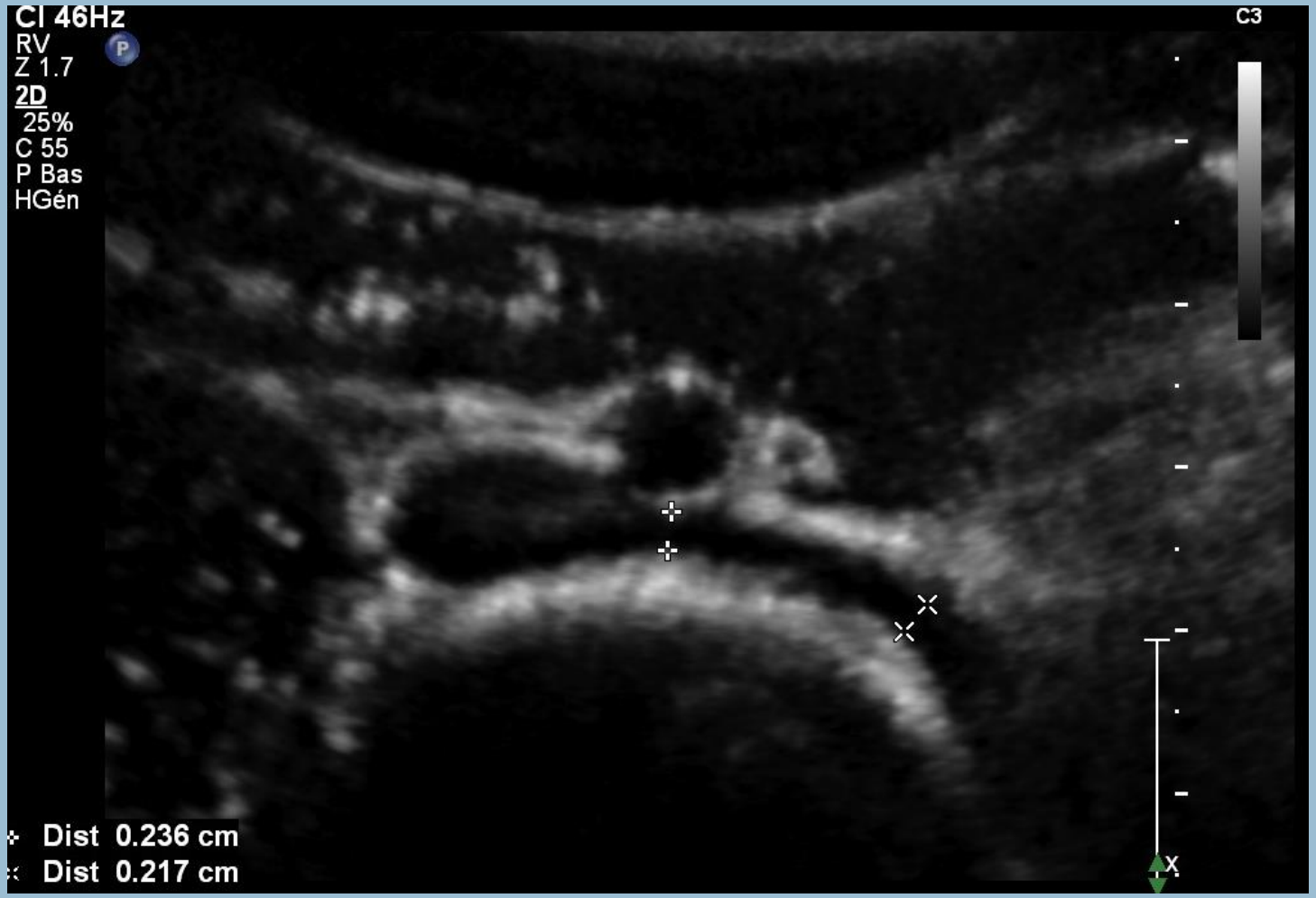

MTS: Duplex Anatomy Analysis

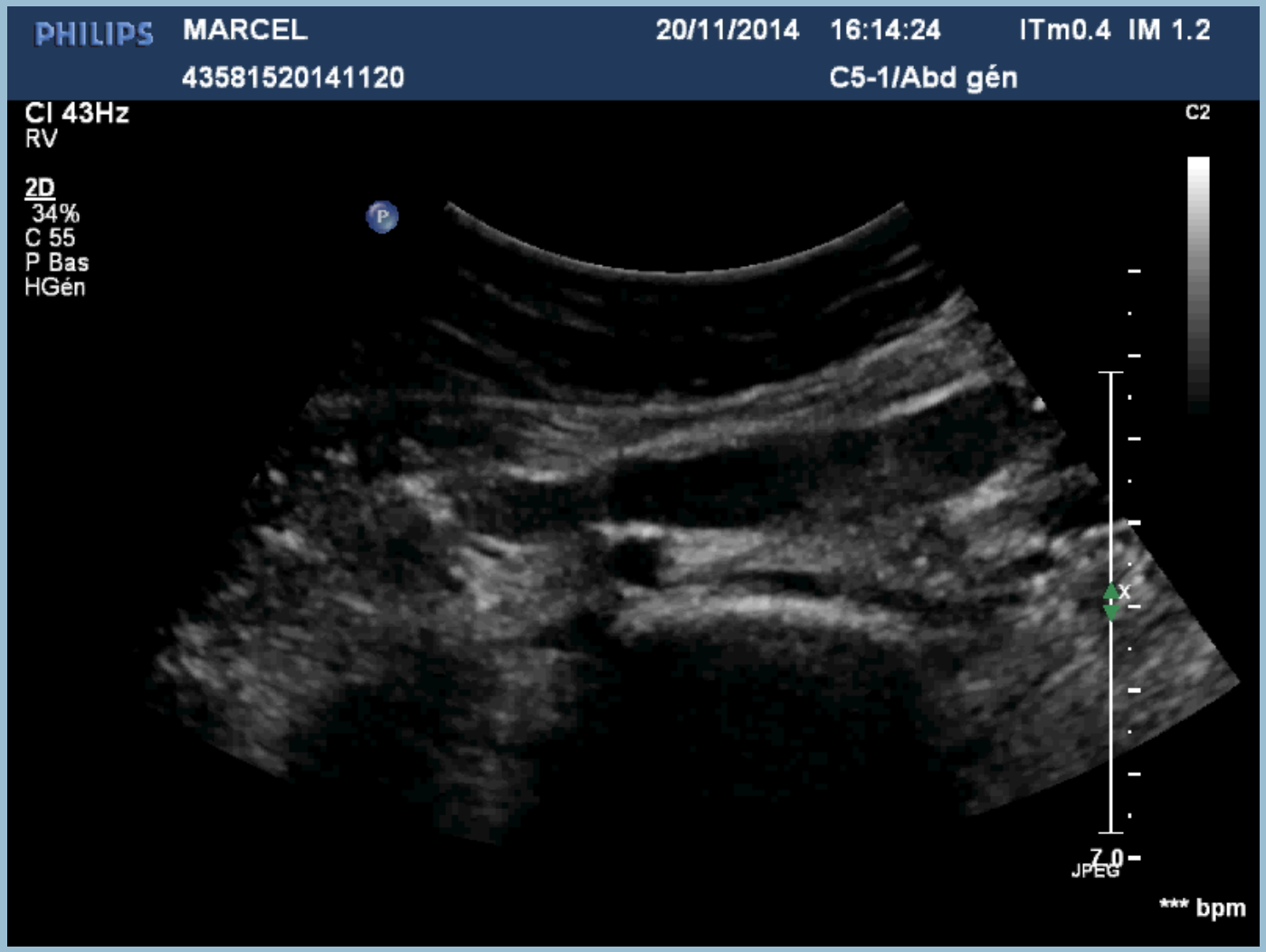

MTS
Comprehensive Pathophysiology

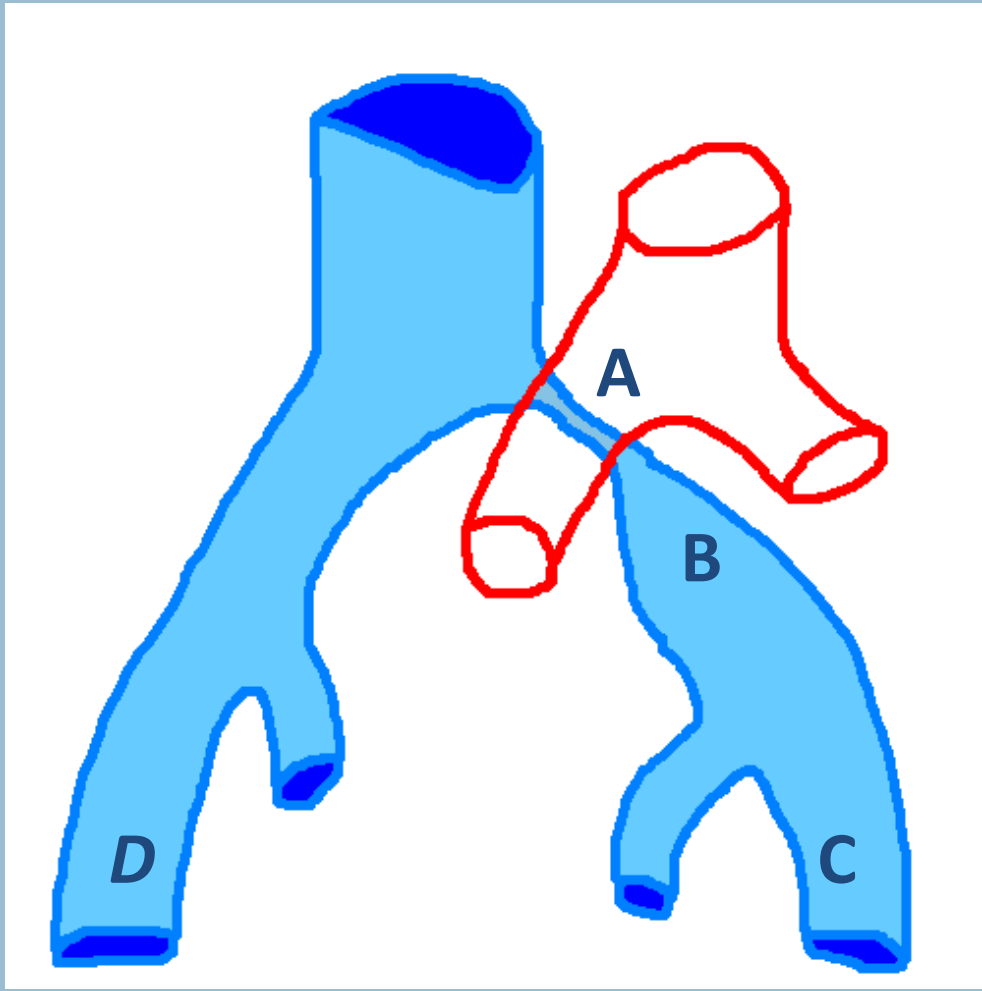

A: ↗ velocity

↘ diameter

B: ↘ velocity

↗ diameter

C: ↘ flux phasicity

***D**: Comparative normal flux phasicity*

Central Veins Stenosis DU Criteria

- 11 iliac veins stenosis in 39 central veins stenosis in 37 symptomatic patients
- DU versus:
  - Phlebography (50% diameter)
  - Pressure measurement (3 mmHg)
  - IVUS (11 patients, 75% section)

Table III. Pressure gradient, velocity measurements and ratios across the stenosis

	Mean	*Median*	*IQR*	*Range*
ΔP	7	6	4-9	3-22
V2/V1	5.2	4.9	3-8	2.5-15
V2/V1 normal	0.98	0.95	0.87-1.05	0.83-1.17
PVV after stenosis	112	91	79-173	55-294
PVV before stenosis	12	10	7-15	5 to 26
PVV control	28	25	19-36	14-49

ΔP, Pressure difference across the stenosis; *V2/V1*, velocity ratio across the stenosis; *V2*, poststenotic velocity; *V1*, prestenotic velocity; *PVV*, peak vein velocity; *IQR*, interquartile range.

- Ratio V1/V2 > 2.5
- Asymmetry of flux: 14 in 17 (82%)

Labropoulos et al. Criteria for defining significant central vein stenosis with duplex ultrasound . JVS 2007

MTS: Duplex Velocities Analysis

A

B

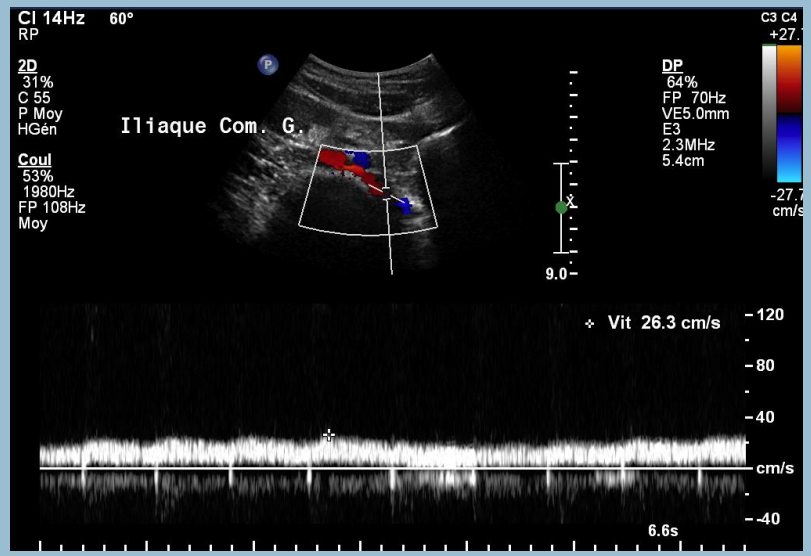

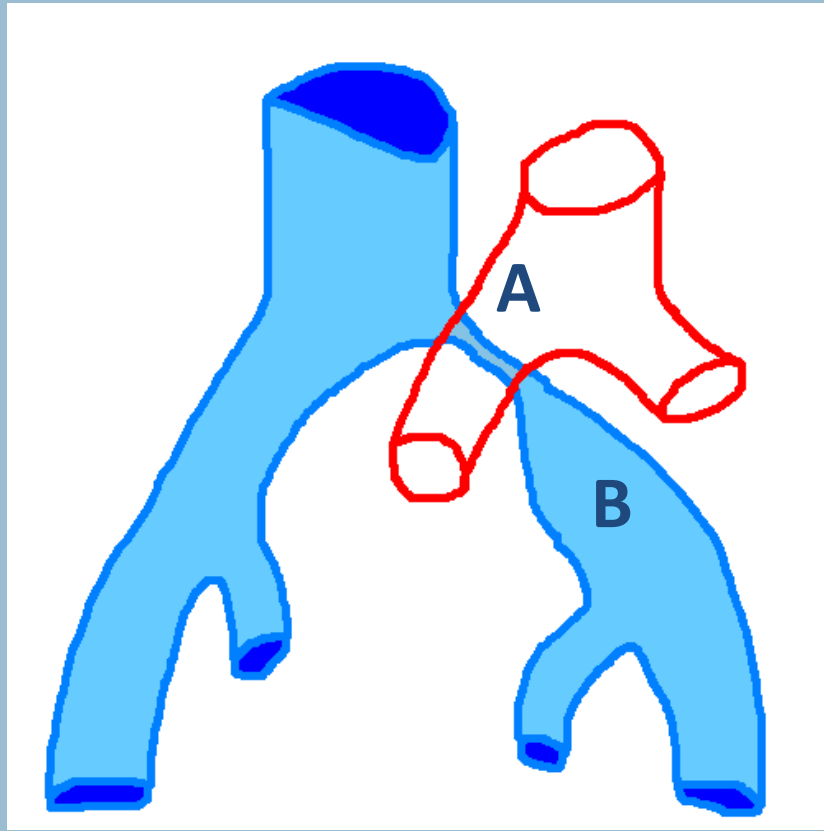

MTS
"More" Comprehensive Pathophysiology

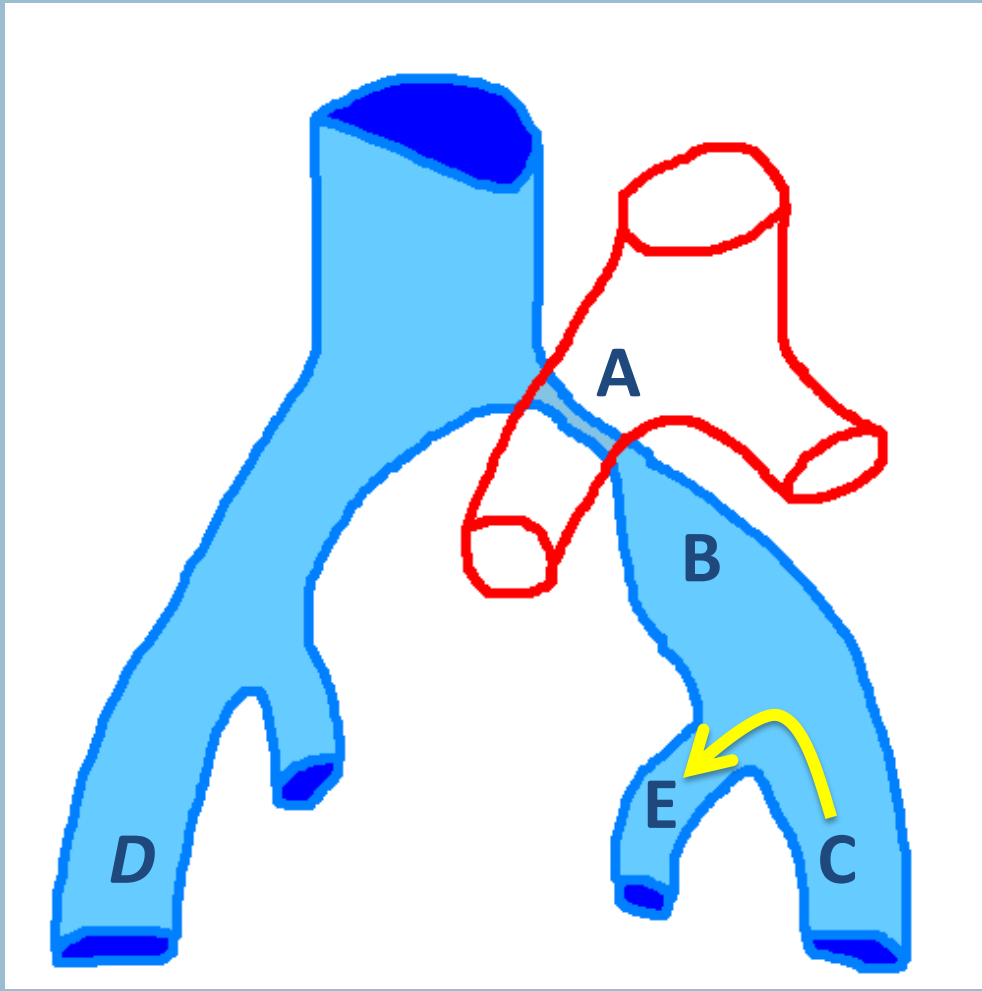

A: N or ↗ velocity
↘ diameter

B: ↘ velocity
N or ↗ diameter

C: ↘ flux phasicity

***D**: Comparative normal flux phasicity*

E: Retrograde flux

Internal Iliac Vein Flux

Antegrade

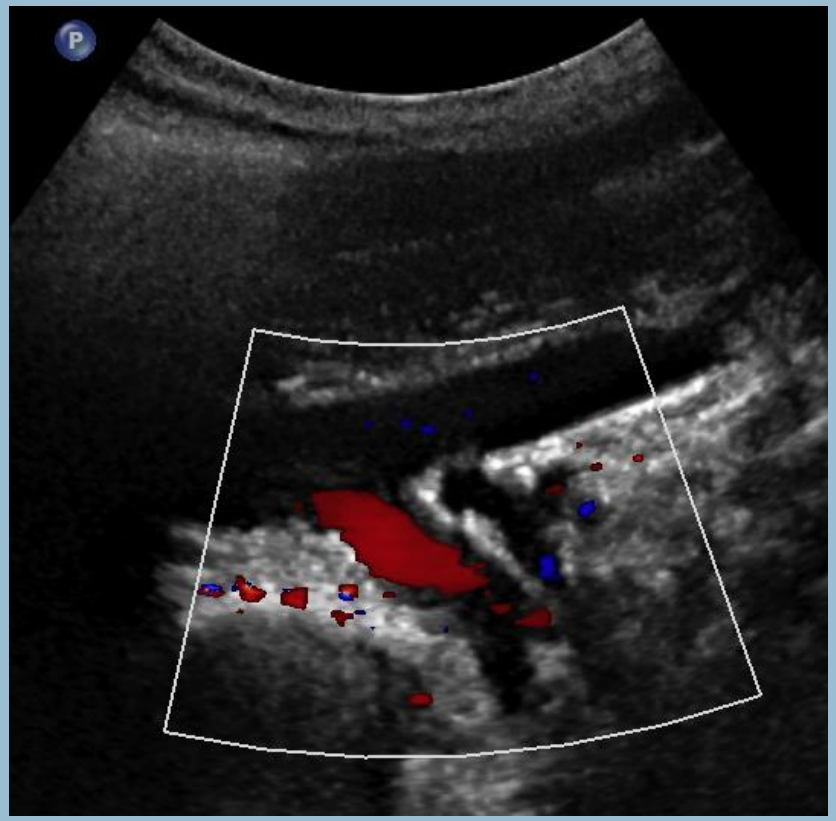

Retrograde

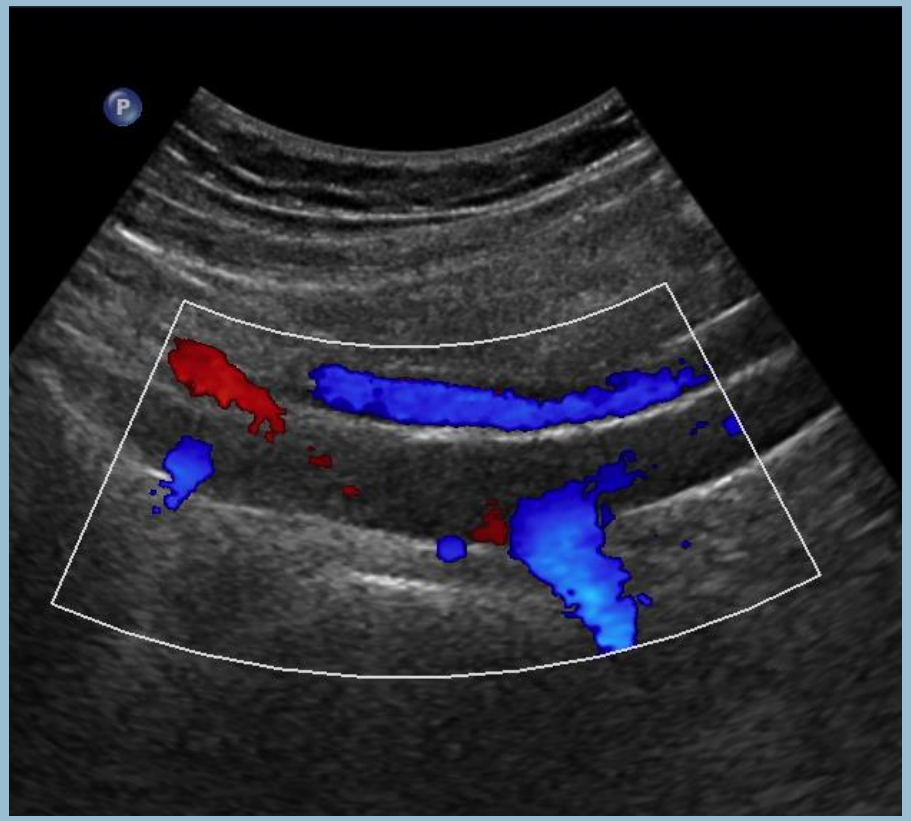

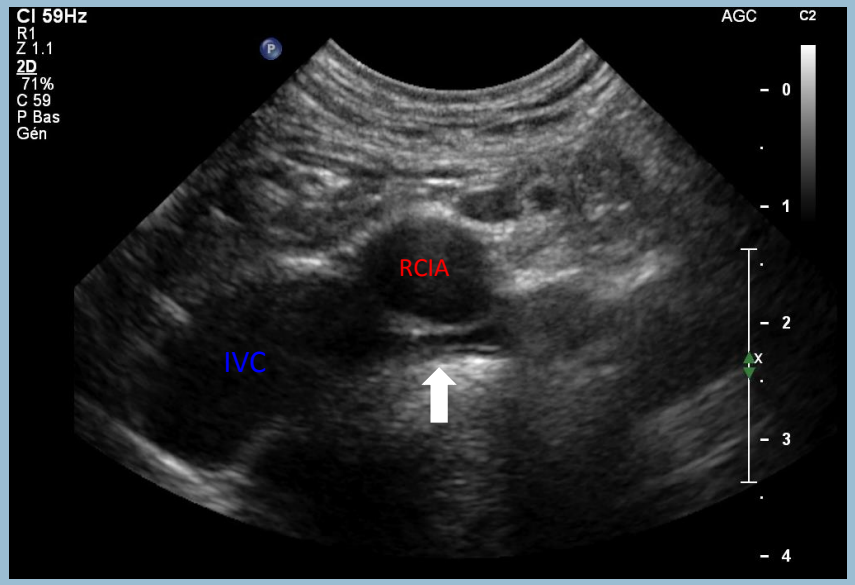

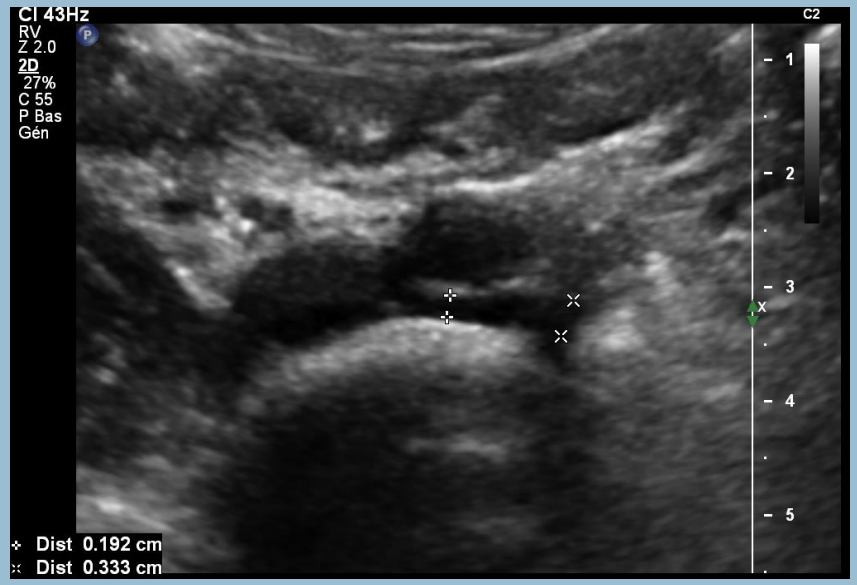

Left commun iliac vein termination

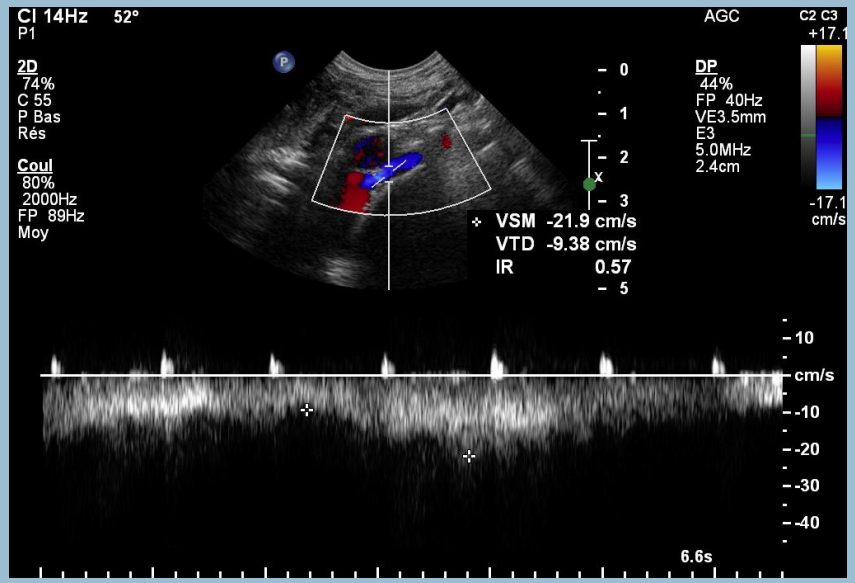

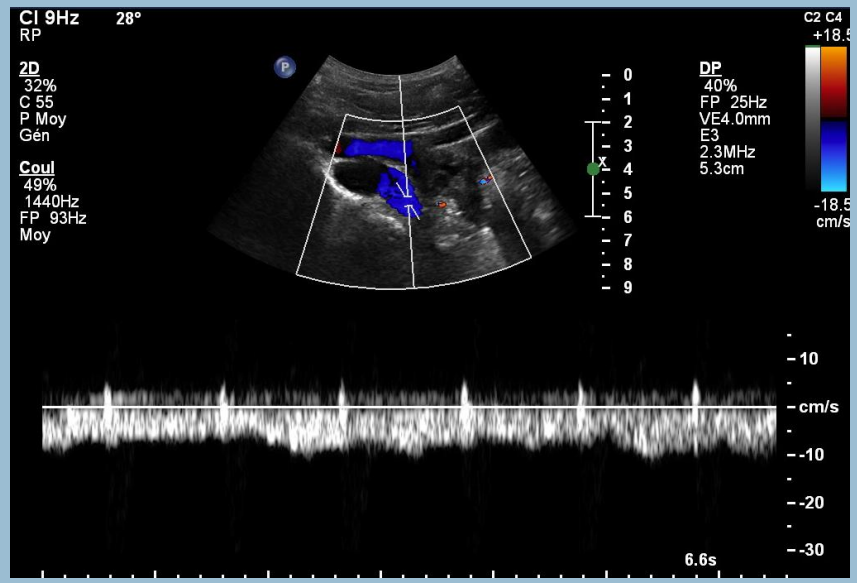

Left internal iliac vein retrograde flux

Common Femoral Vein Flow

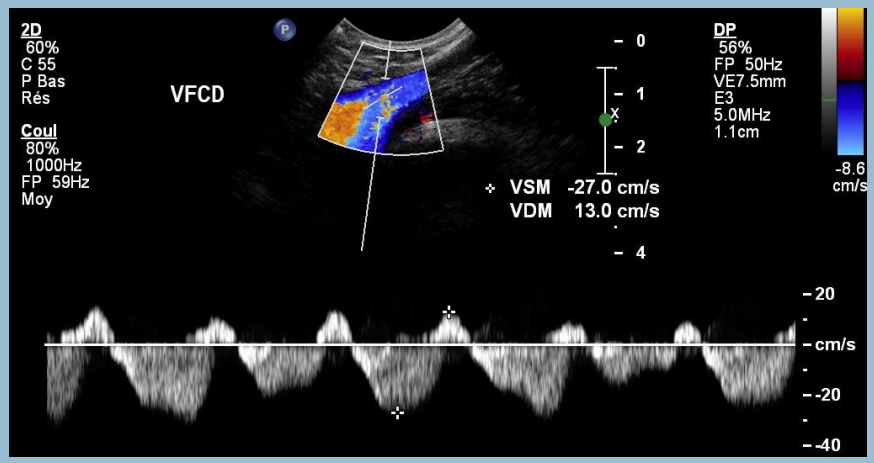

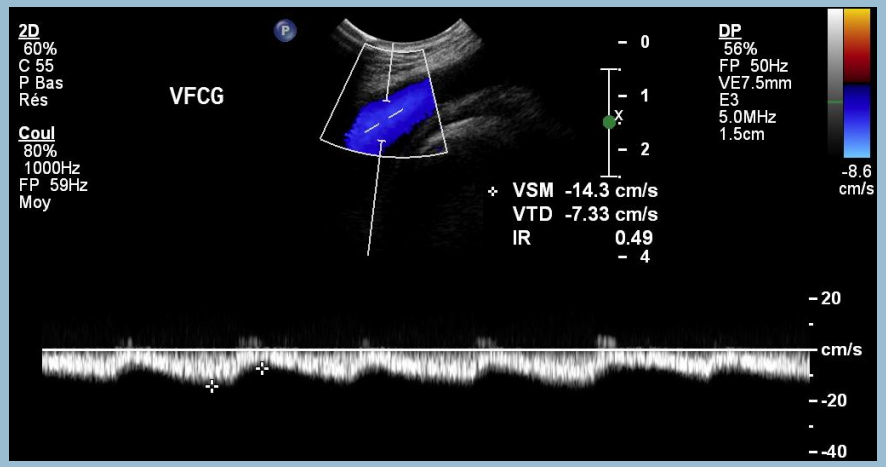

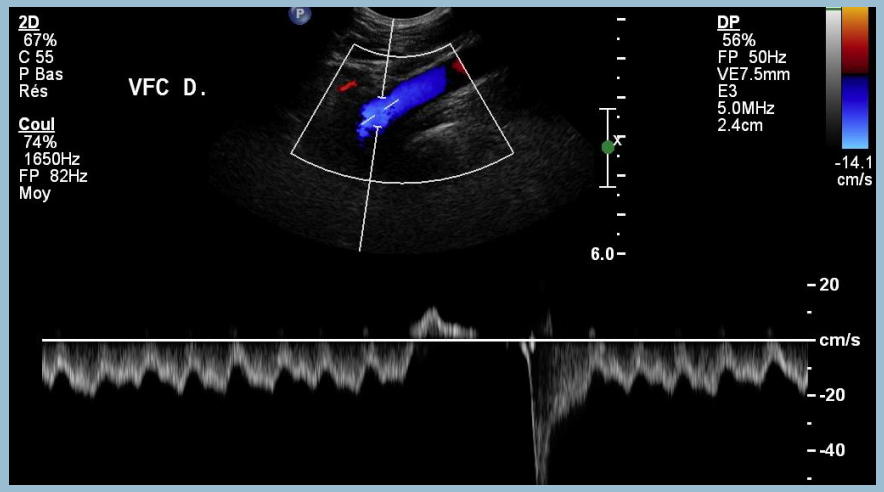

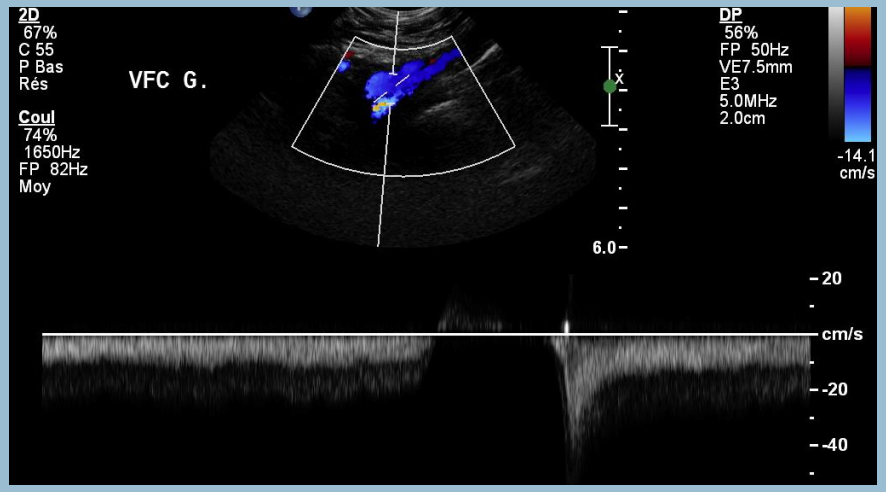

DU Examination Algorithm

1) Right and left CFV flow analysis

Symmetric

Asymmetric → May Thurner Syndrome

DU Examination Algorithm

1) Right and left CFV flow analysis

Symmetric

Asymmetric

2) LIIV flux analysis

Antegrade

Retrograde

May Thurner Syndrome

DU Examination Algorithm

1) Right and left CFV flow analysis

Symmetric → 2) LIIV flux analysis

Asymmetric → May Thurner Syndrome

Antegrade → 3) LCIV analysis

Retrograde → May Thurner Syndrome

Diameter

Velocity

DU Examination Algorithm

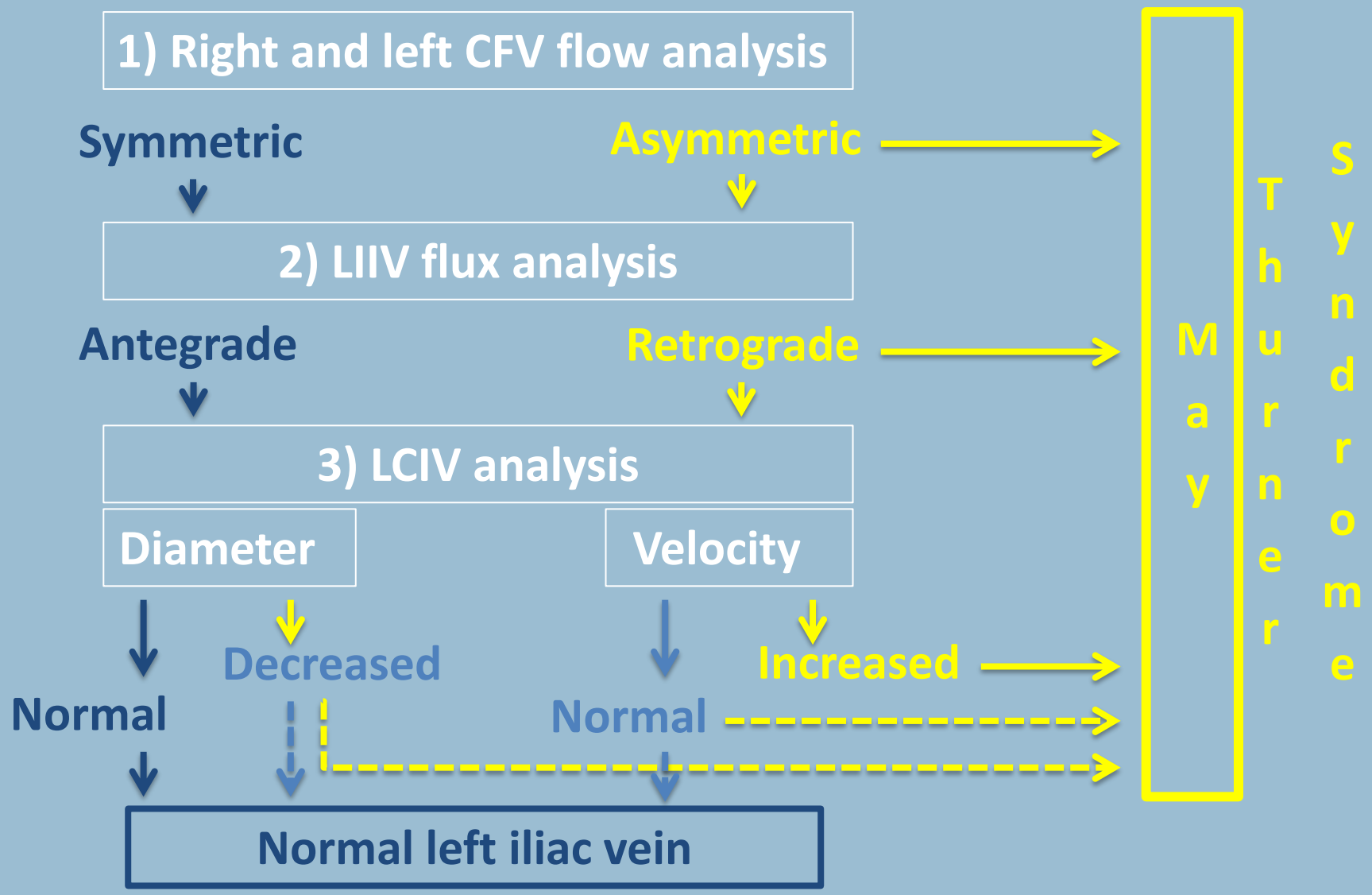

Dynamic Ultrasound Testing

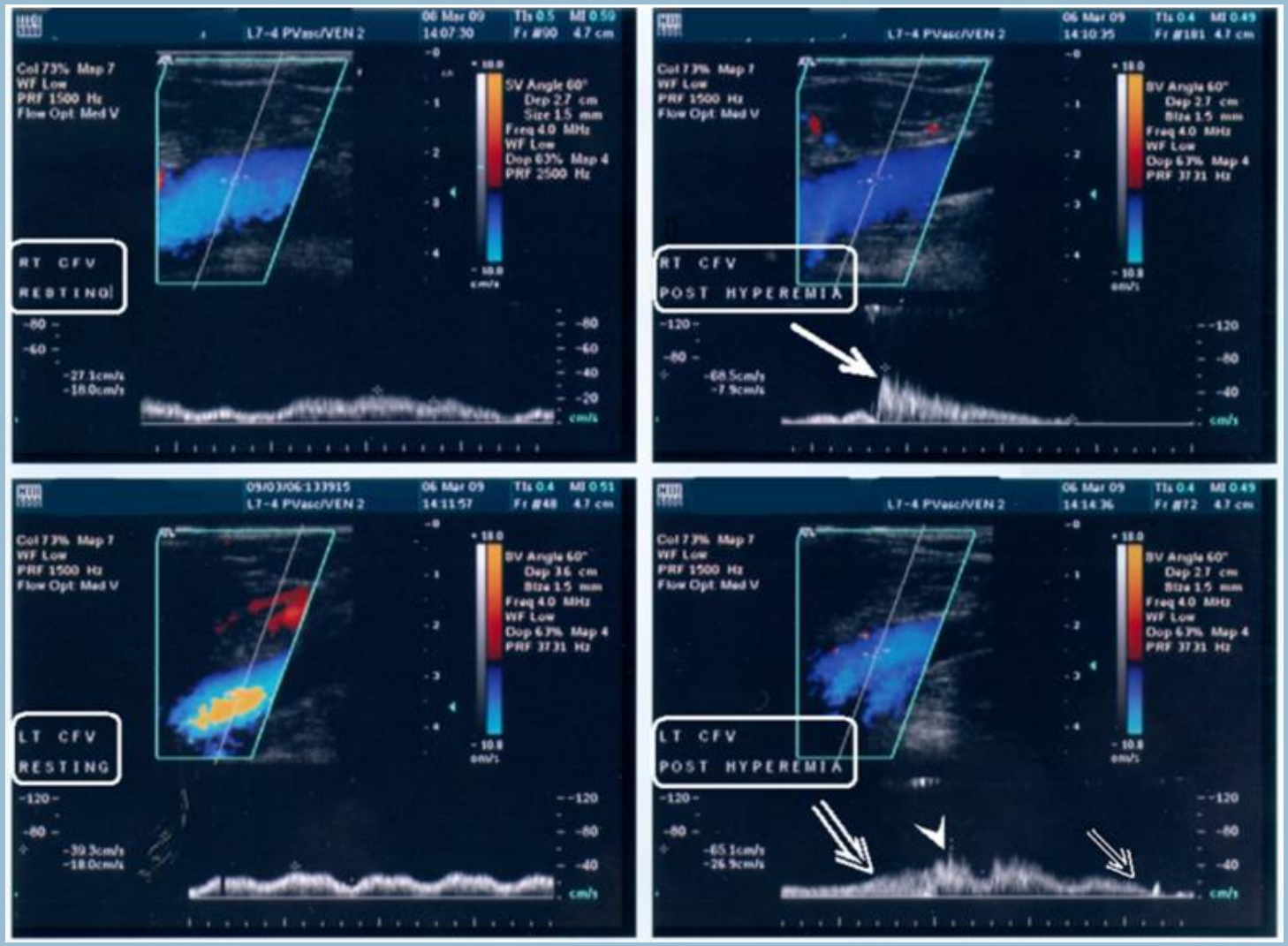

Jones TM et al.Maximal venous outflow velocity: an index for iliac vein obstruction. Ann vAsc Surg 2012

Taking Home Message !

- Isolated measurement of the LCIV diameter expose to false positive risk
- Isolated measurement of the LCIV velocity expose to false negative risk
- Accurate ultrasound MTS diagnosis must integrate :
  - Anatomic and hemodynamic sign
  - Direct and indirect signs
  - Static and dynamic signs