24 Janvier 2015

# Nutcracker syndrome can be improved by left common iliac vein stenting in case of concomitant May-Thurner syndrome

O Hartung

Sce de Chirurgie Vasculaire, CHU Nord, Marsei

# Introduction

- **Nutcracker syndrome (NCS)**
  - Rare but disabling pathology
    - Lumbar pain + hematuria
    - Pelvic congestion syndrome (PCS)
  - Stenting or surgery
- **May-Thurn**
  - Can cause
  - Stenting

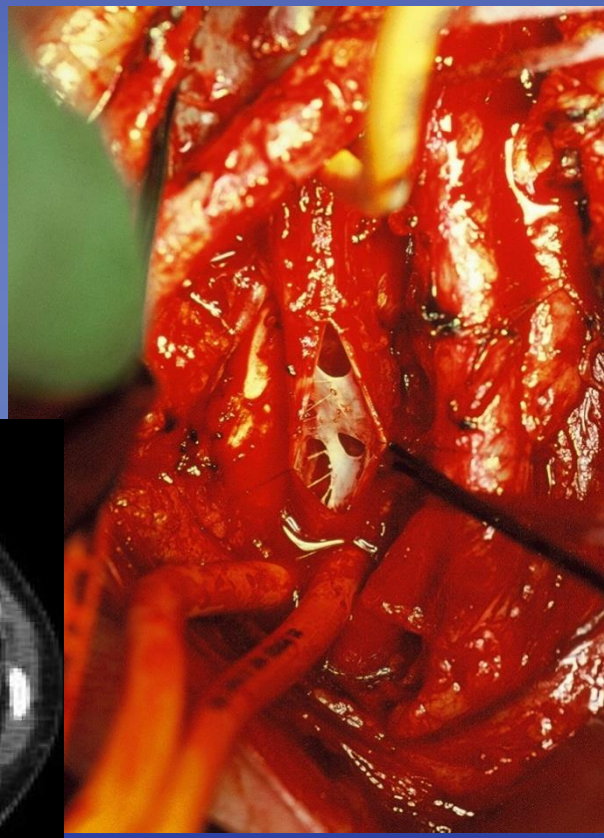

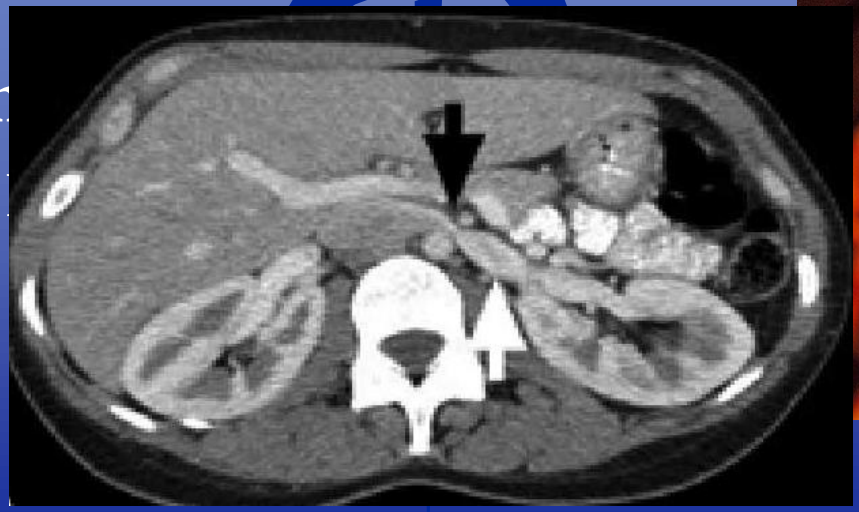

# Material and methods

- **October 2002-September 2014**
  - 44 consecutive patients with NCS
  - 18 women suffering from PCS with NCS + MTS
    - Median age 37 years
    - Lumbar pain 16
    - Hematuria 10
    - Lower limb
      - C0 : 4
      - C2 : 11
      - C3: 3

# Diagnosis

- **Duplex-scan**
- **CT scan**
- **Phlebography (LA)**
  - Iliocavography
  - Left renal vein phlebography
  - Reno-caval pullback gradient > 3mm Hg (3-5)
  - Incompetent LOV : 14
    - Previously embolized : 2
    - Competent : 2

JEN
ID: Anonymous
O
Study 1
13/03/2013
11:04:11
1 IMA 30 FRM 1
ARCADIS
Soustraction en radioscopie
Ortho/Trauma/All body region/Standard
SINGLE PLANE
W: 1365
C: 1771

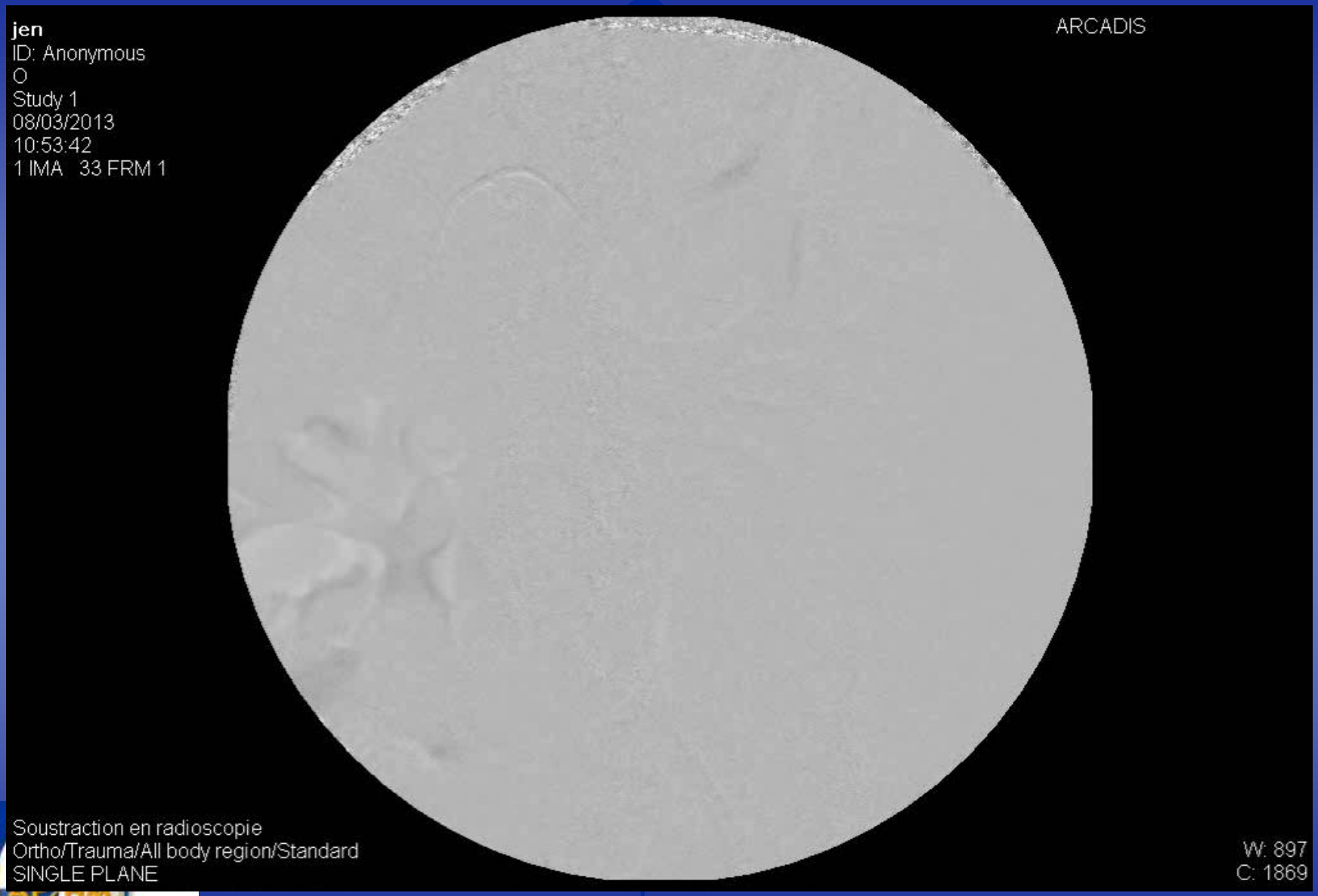


**Service de Chirurgie Vasculaire, CHU Nord, Marseille**

# Treatment

- **Left common iliac vein stenting**
  - Local anesthesia + sedation
  - Echo-guided common femoral vein approach
  - Self-expanding stent
    - Wallstent 16 x 60



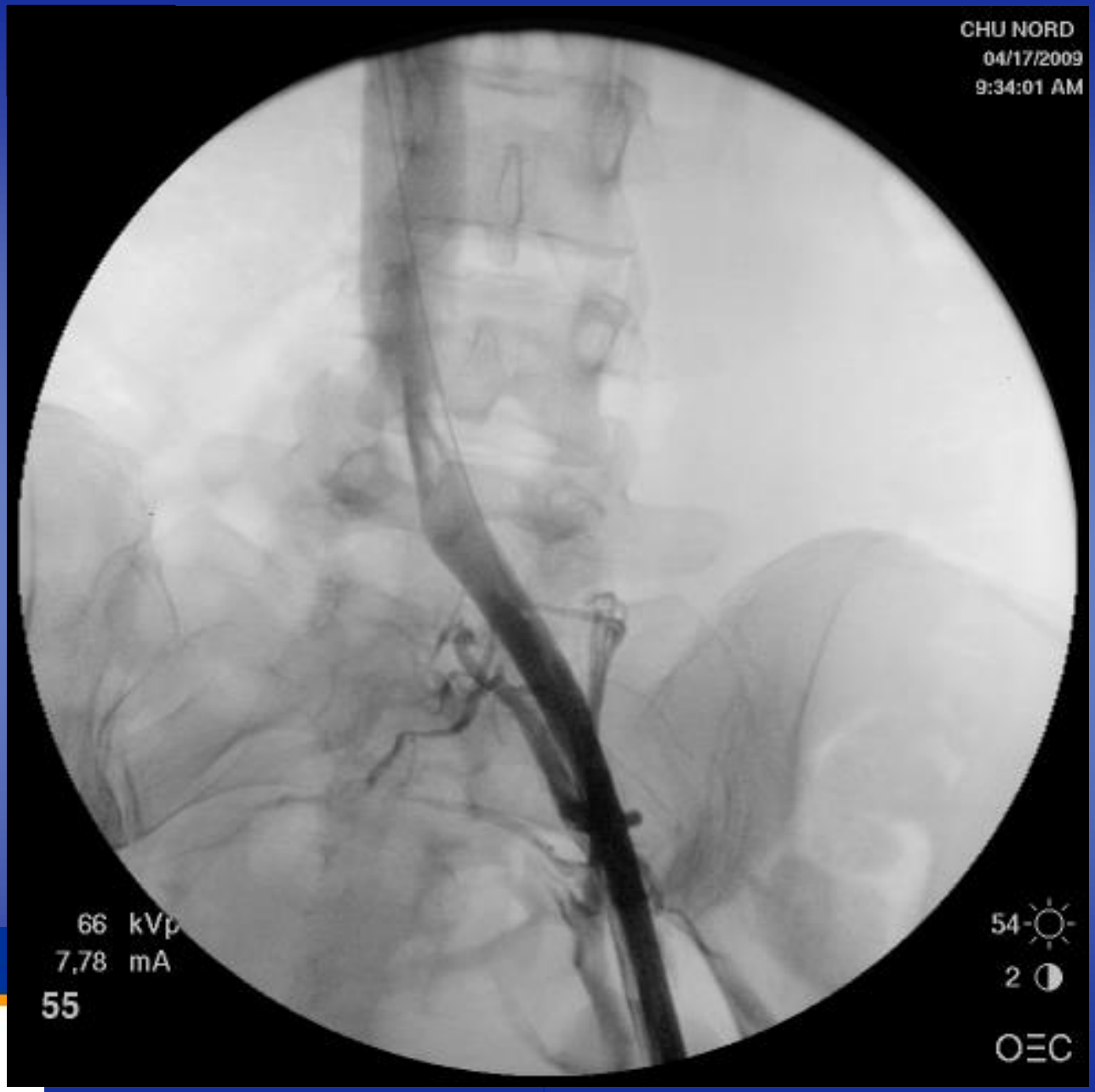


Service de Chirurgie Vasculaire, CHU Nord, Marseille

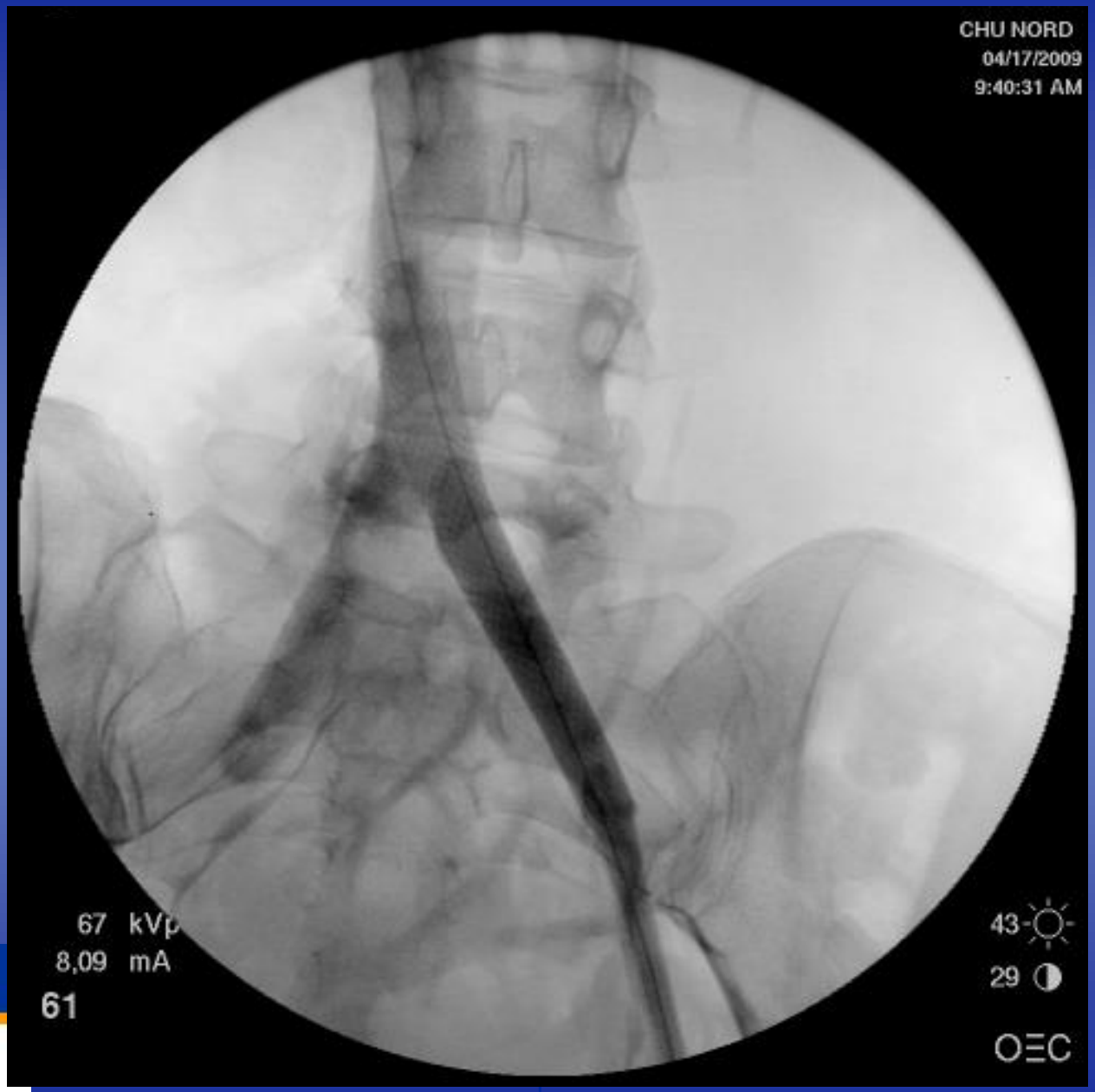


Service de Chirurgie Vasculaire, CHU Nord, Marseille

# Treatment

- **Left common iliac vein stenting**
  - Local anesthesia + sedation
  - Echo-guided femoral vein approach
  - Self-expanding stent
- **Postoperative treatment**
  - LWMH for 3 weeks
  - Plavix for 12 months

# Results

- **No perioperative complications**
  - LOS : 1 day
- **Follow-up : median 13 months (2-112)**
  - Primary patency rate : 100%

# Clinical results

- **Persistence of disabling lumbar pain : 3**
  - NCS treated at 1M, 2M and 5M
- **Improvement : 15 (83%)**
  - 2 late recurrence (44M, 60M) => NCS treated
  - 13 improved including 6 asymptomatic

# Discussion

- **NCS collateral pathways**
  - Left gonadic vein
  - Left ascending lumbar vein
  - Adrenal vein
  - Hemiazygos vein

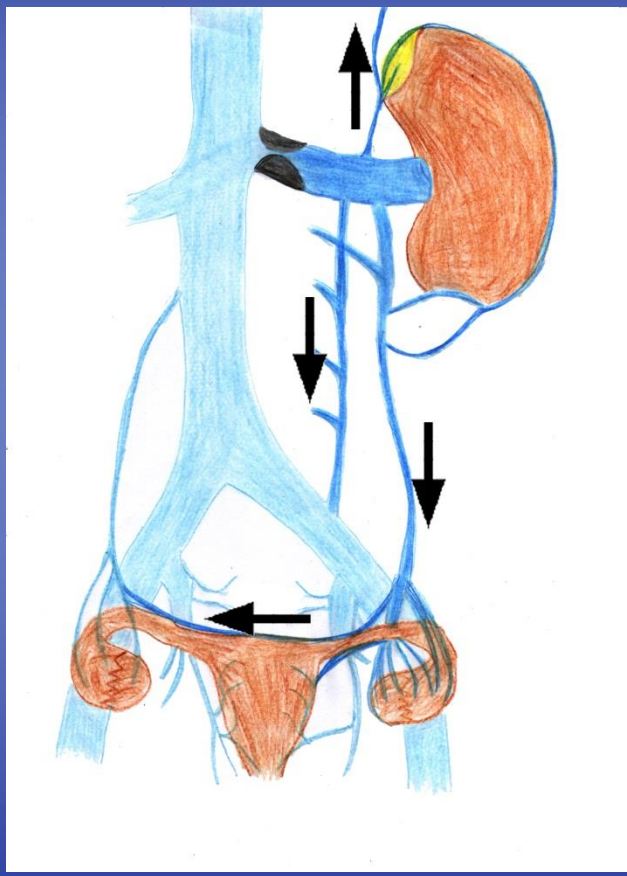

# Discussion

- **NCS + MTS**
  - Reduction of flow in collateral pathways
    - Left gonadic vein
    - Left ascending lumbar vein

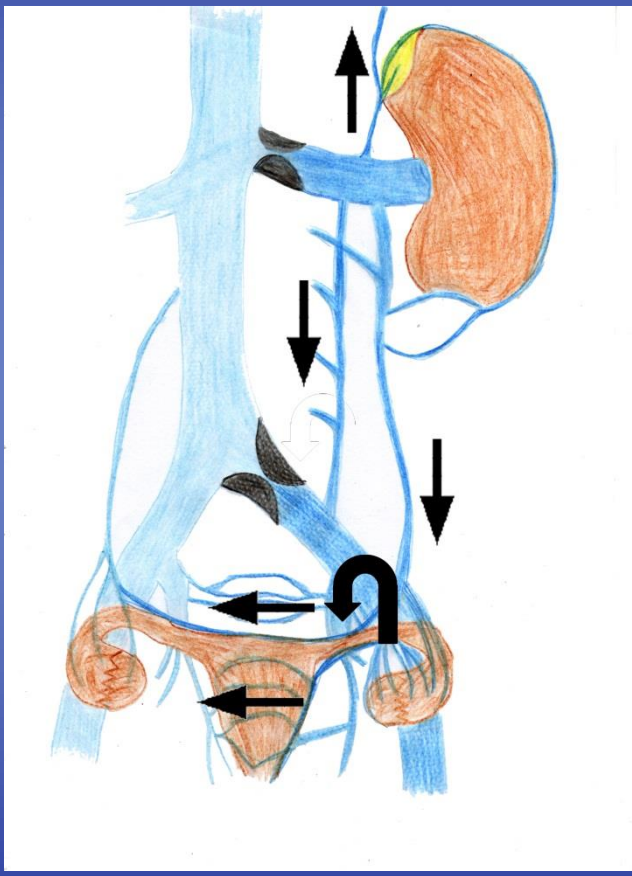

**=> MTS treatment should improve renal drainage and NCS symptoms**

# Discussion

- **Stenting for MTS => excellent results**
  - PP >95% at 10 years
- **Stenting for MTS with NCS**
  - 83% improvement of PCS and NCS
    - 2 late recurrences
  - Continent LOV : 50% improvement

# Conclusion

- **Association of MTS and NCS is rare**

- **Left CIV stenting**
  - Can improve pelvic and renal symptoms mainly when LOV is incompetent
  - Can avoid, at least for a few years, direct treatment of the NCS