

# Obstructive Lymphedema of Limbs can be successfully controlled by Silicone Tube Implants replacing Obliterated Lymphatics-Four years follow-up

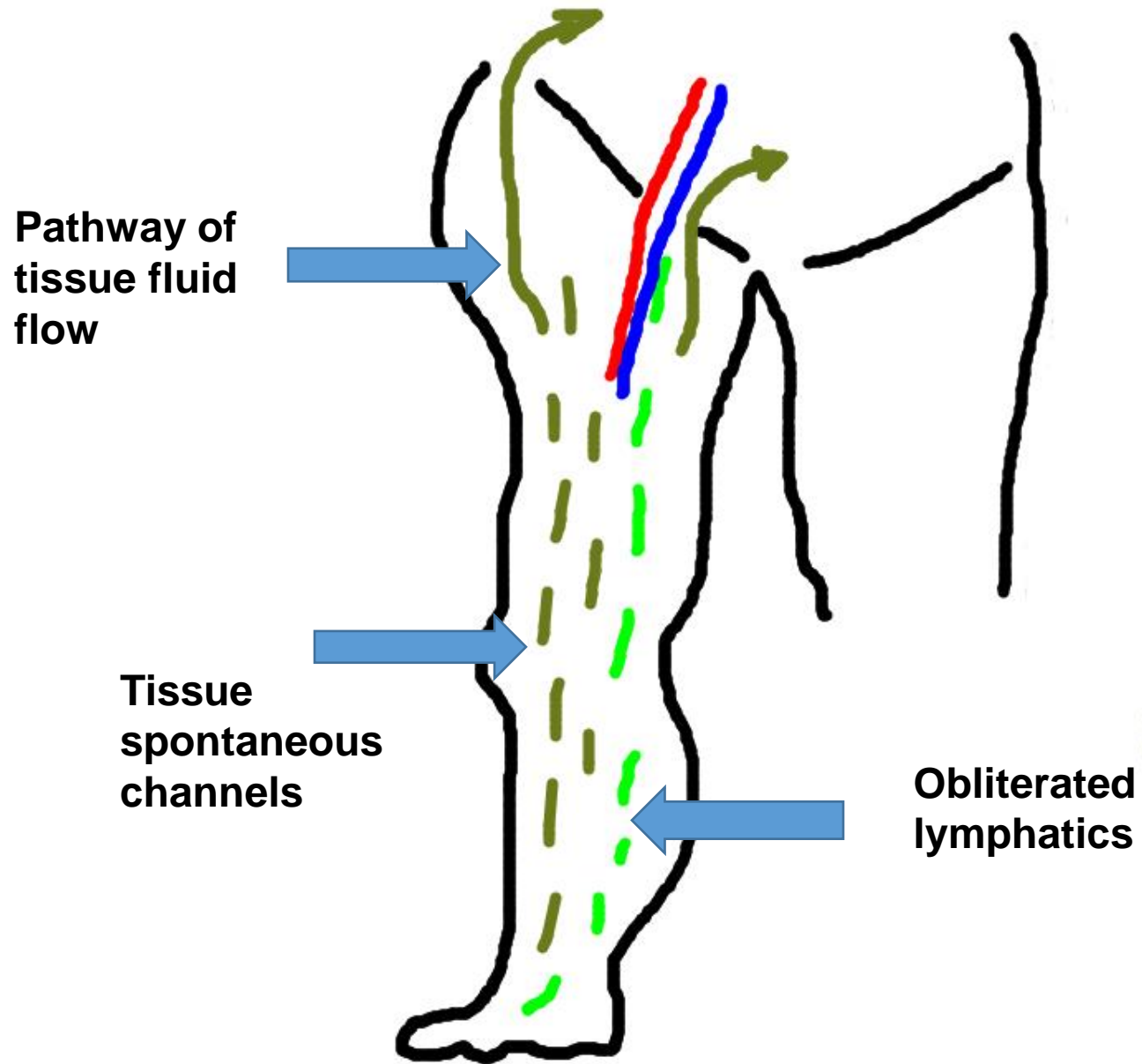
Waldemar L Olszewski, Marzanna Zaleska

Central Clinical Hospital

Medical Research Center

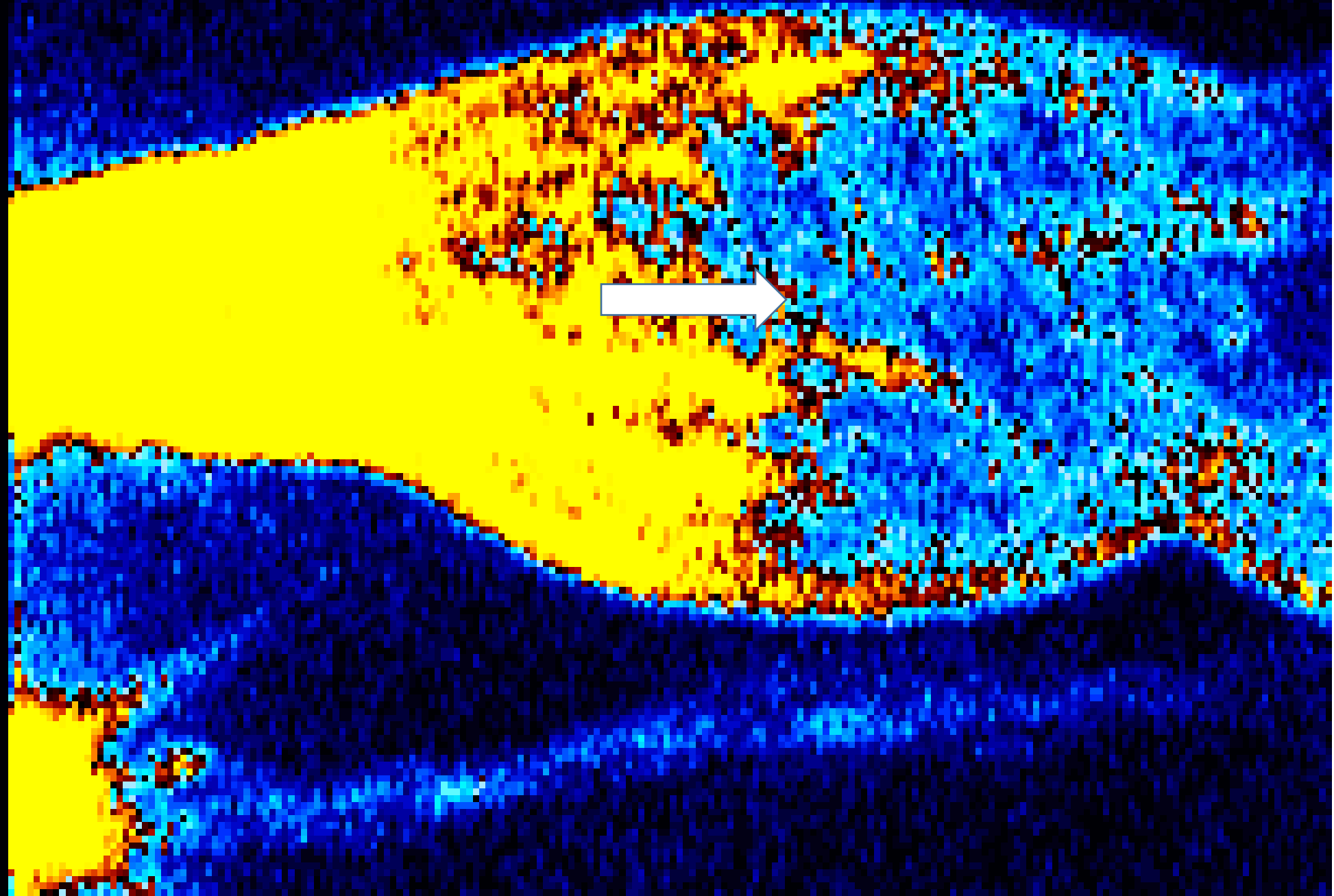
Warsaw, Poland

[waldemar.l.olszewski@gmail.com](mailto:waldemar.l.olszewski@gmail.com)

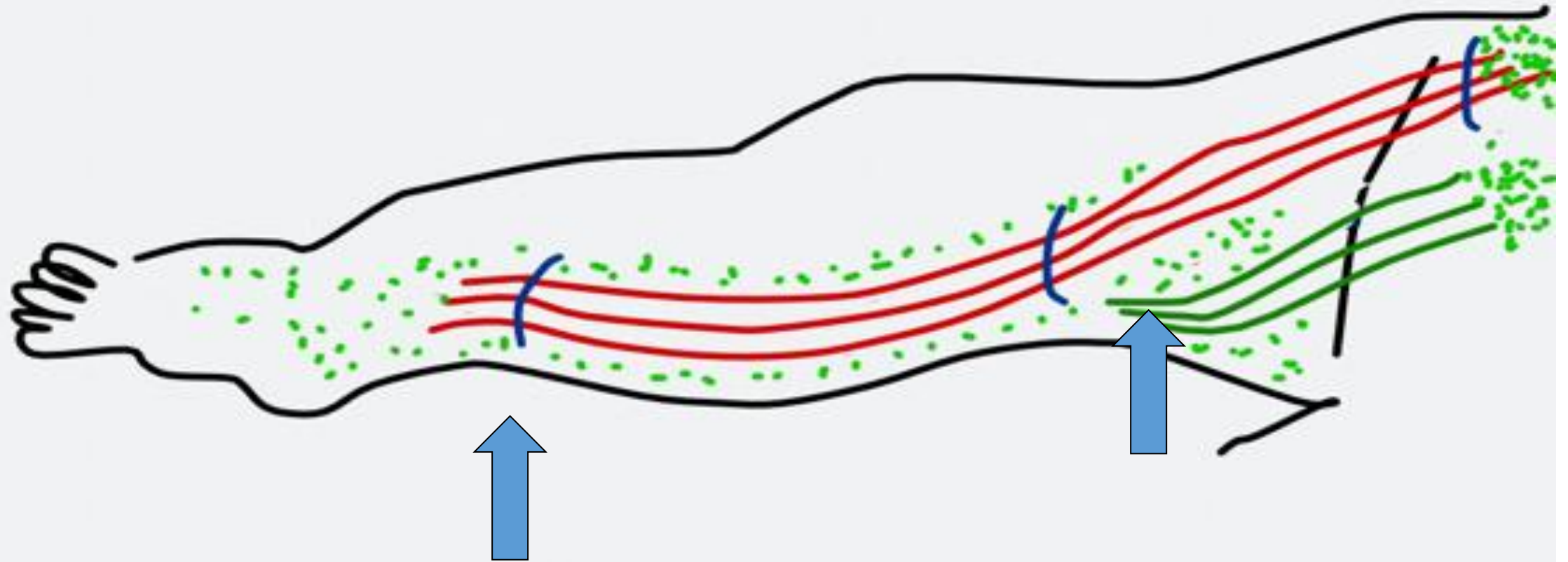


**IMPLANTED TUBINGS FACILITATE FLUID ACCUMULATION AROUND AND BYPASSING INGUINAL CREASE**

# Tissue channels on lymphoscintigraphy



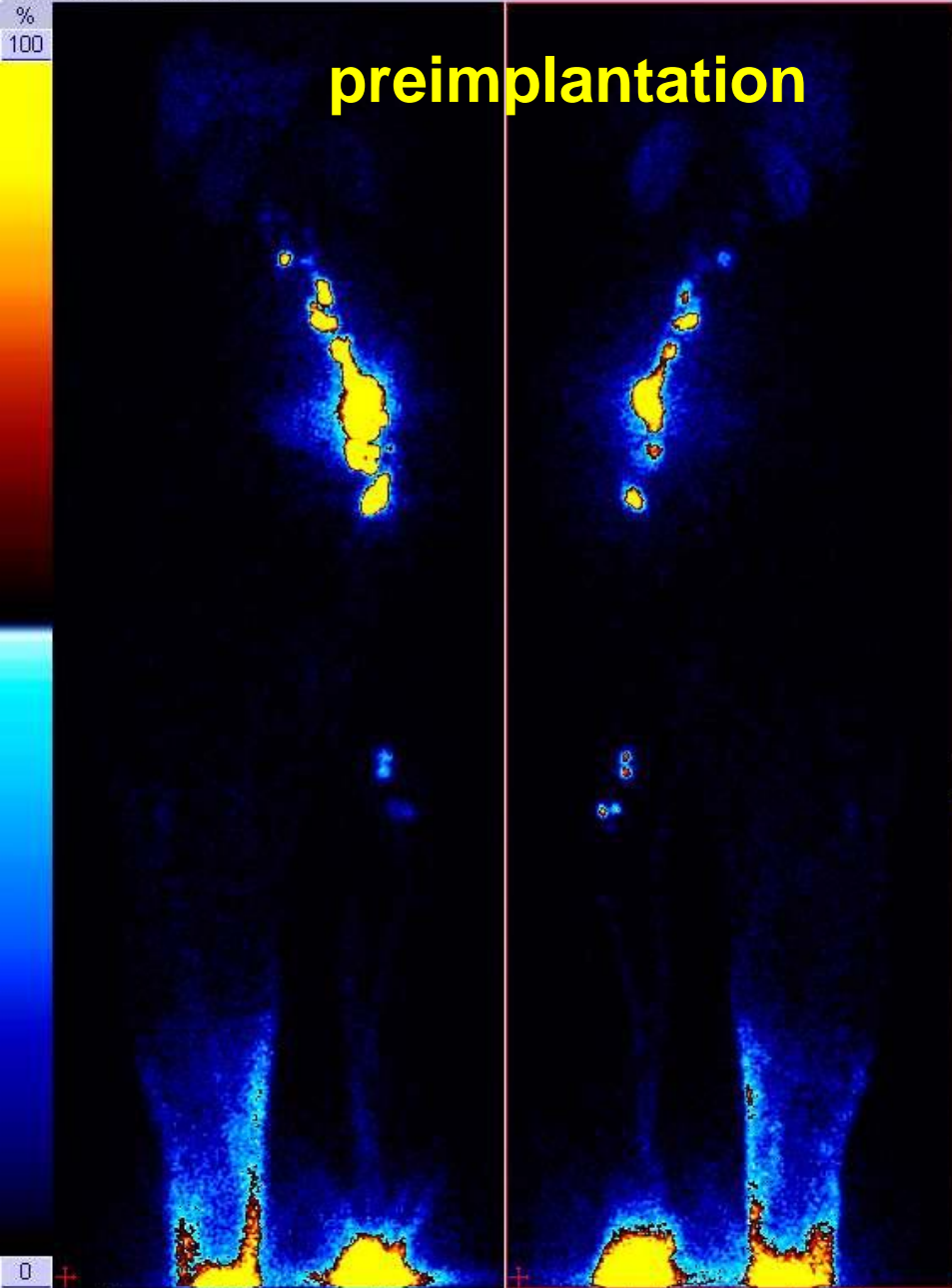
# LOWER LIMB IMPLANTATION SITE



Lymphatic 19/07/12

%  
100

**preimplantation**



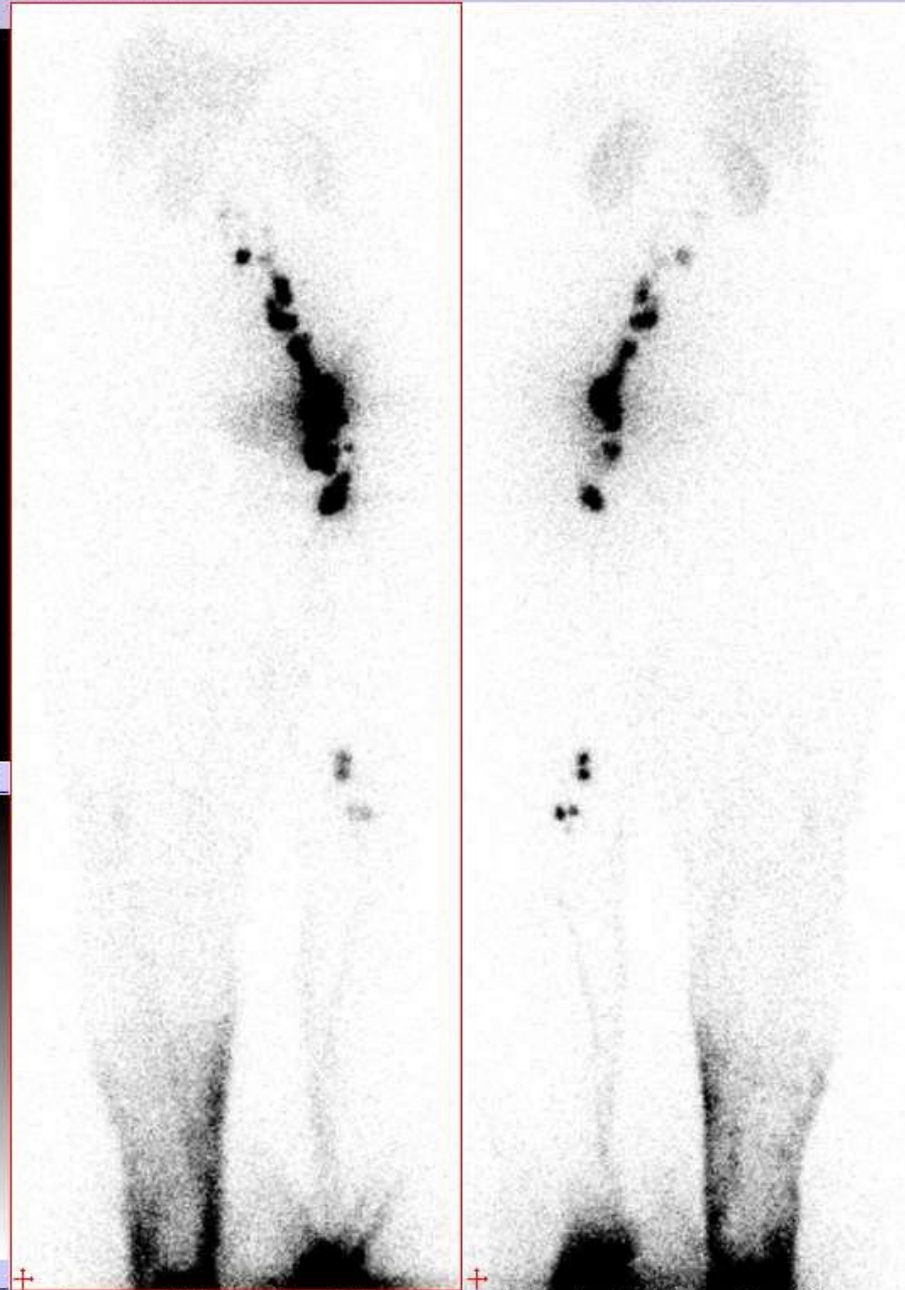
Anterior 922K Duration:637sec

Posterior 570K Duration:637sec

Lymphatic 19/07/12

%

39



Anterior 922K Duration:637sec

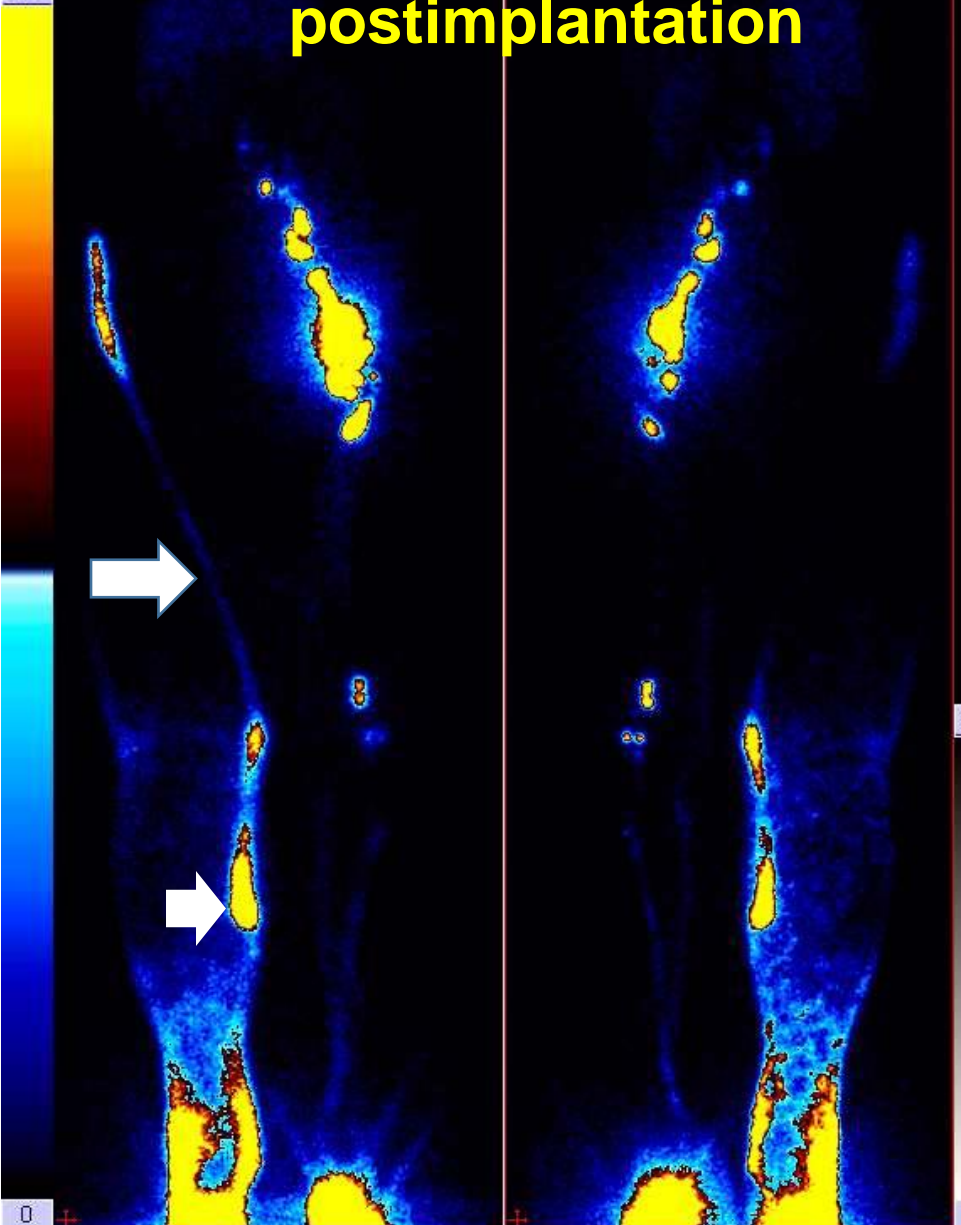
Posterior 570K Duration:637sec

Lymphatic 14/04/14

%

100

**postimplantation**



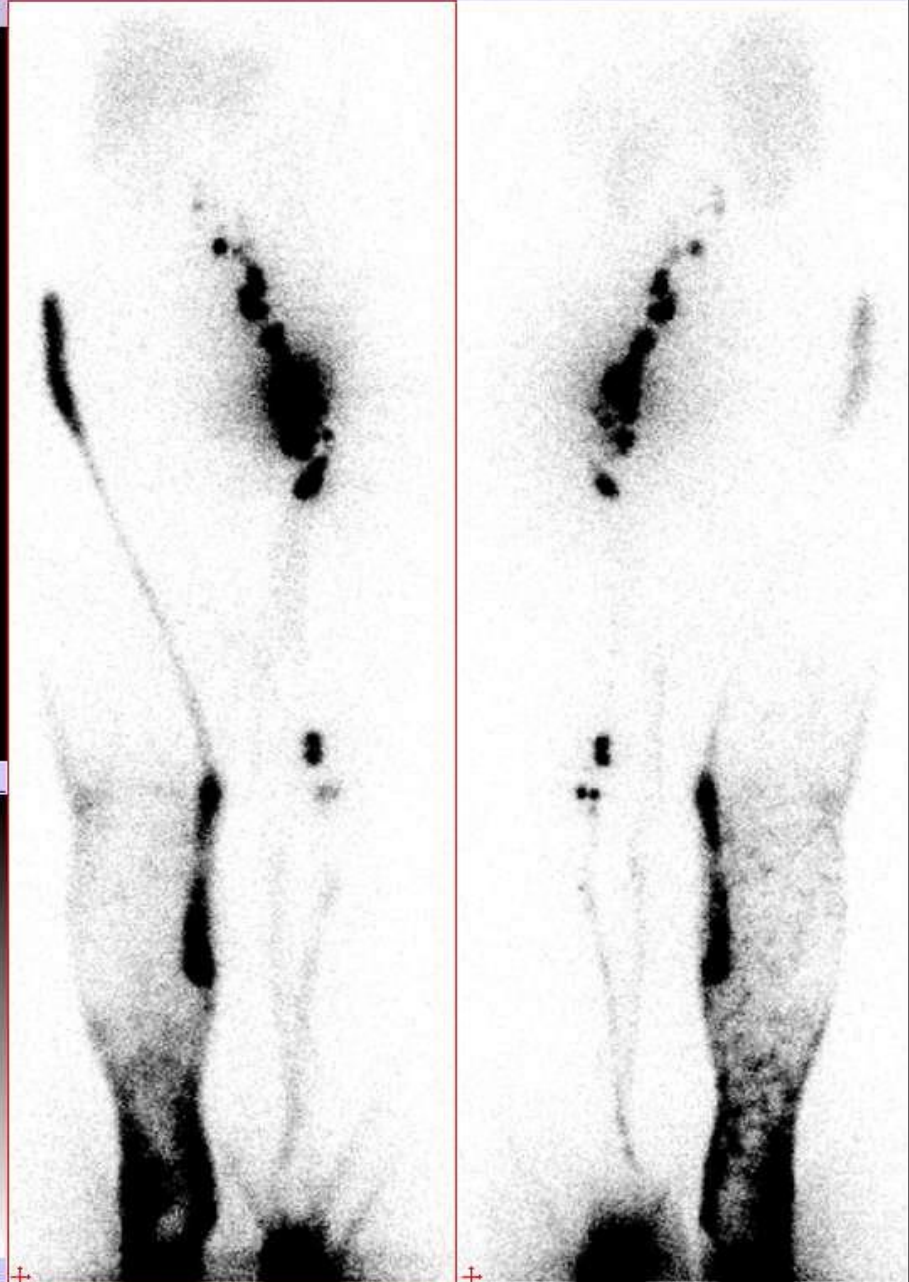Anterior 1130K Duration:656sec

Posterior 843K Duration:656sec

Lymphatic 14/04/14

%

39

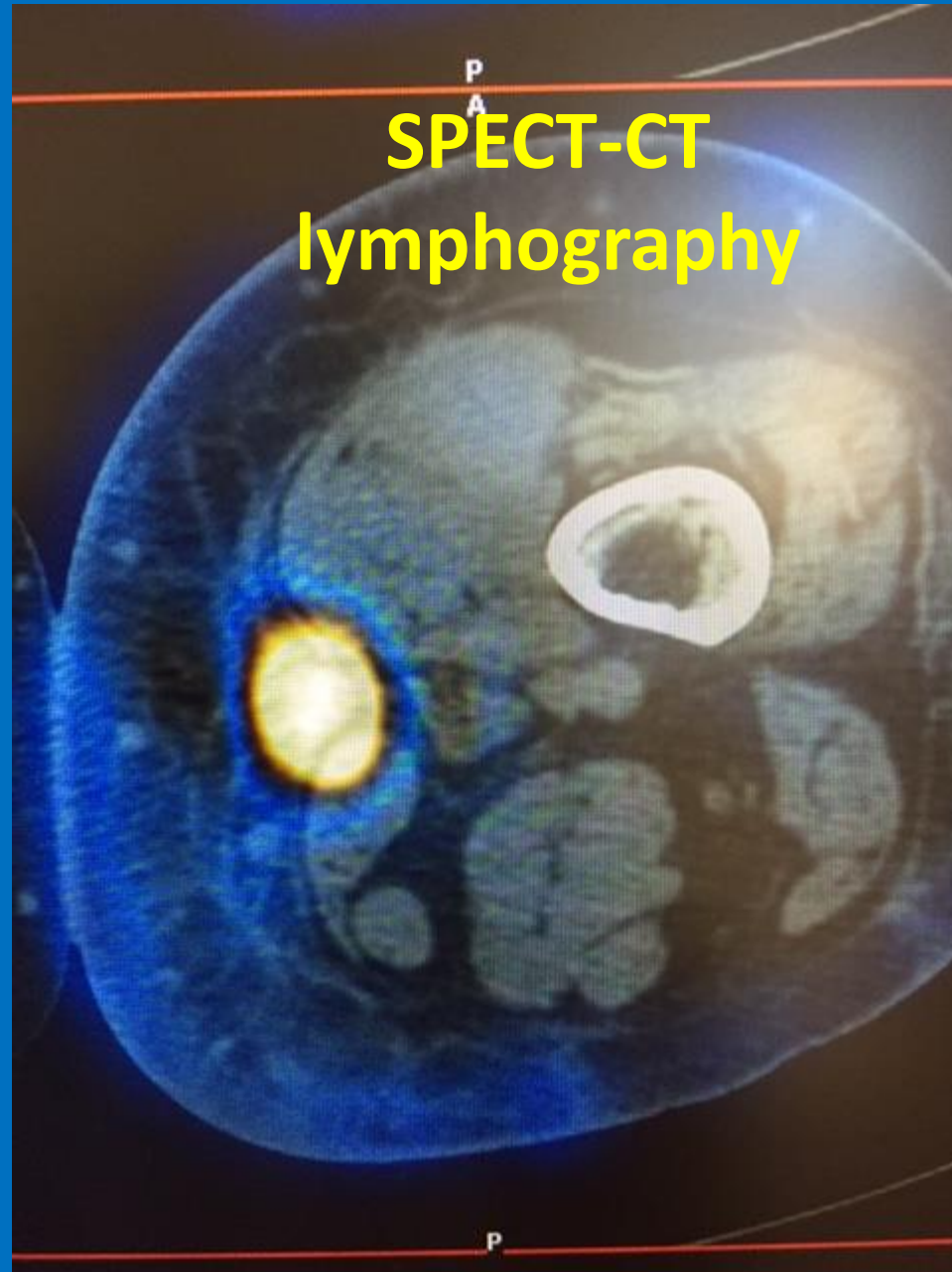


Anterior 1130K Duration:656sec

Posterior 843K Duration:656sec

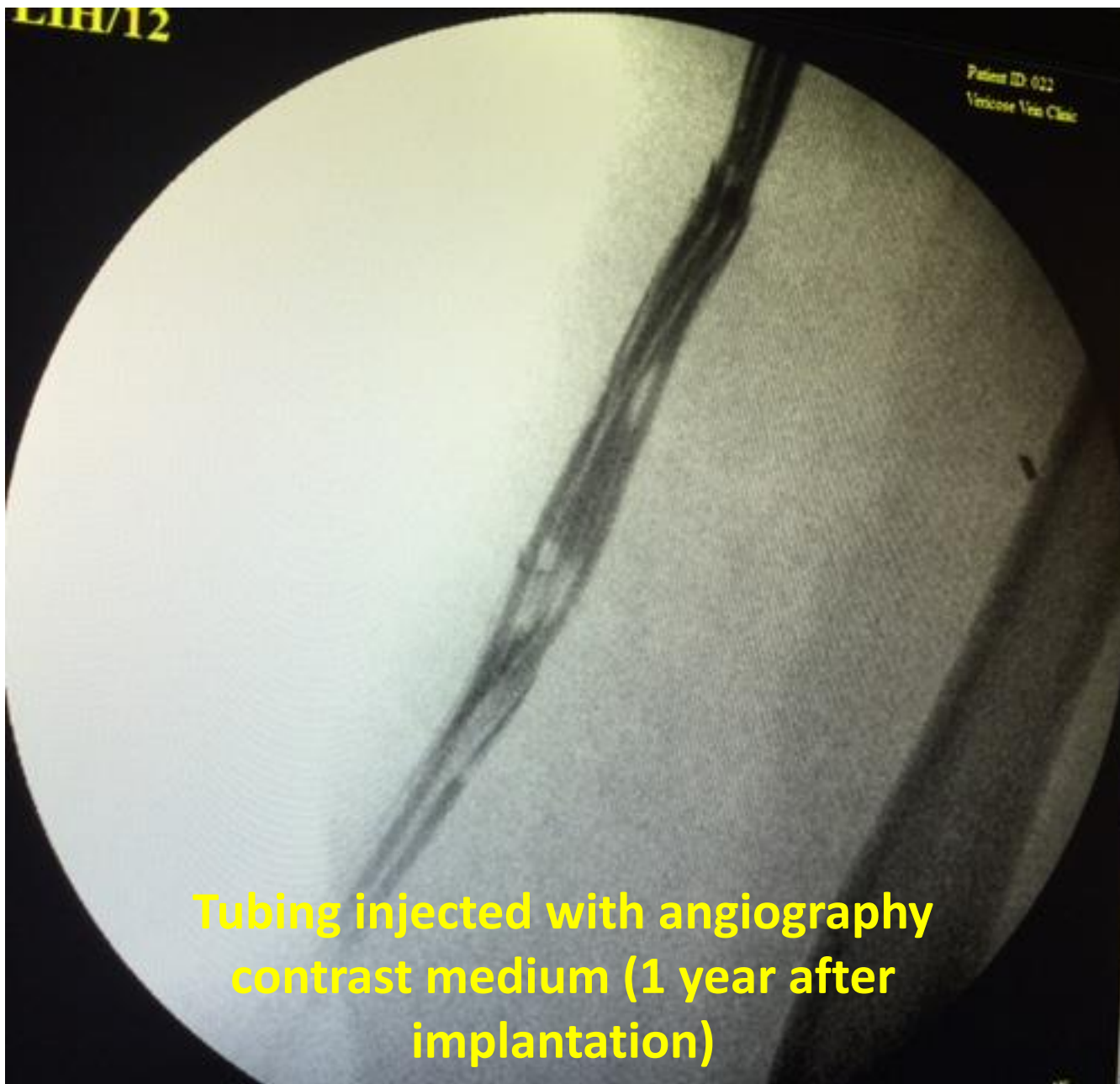
P  
A

# SPECT-CT lymphography

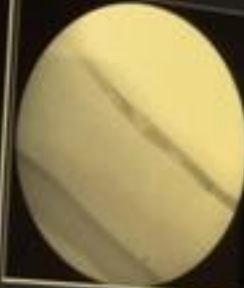

L1H/12

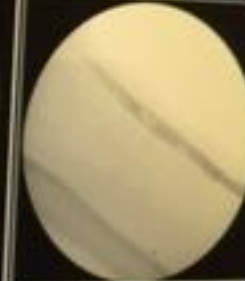Patient ID: 021  
Vascular Visc Clinic



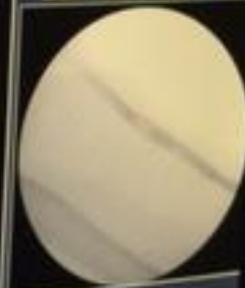FIRST FRAME



LAST FRAME



LAST FRAME (Previous Series)



**Tubing injected with angiography  
contrast medium (1 year after  
implantation)**





mrs sharma  
15397-14-04-29-26

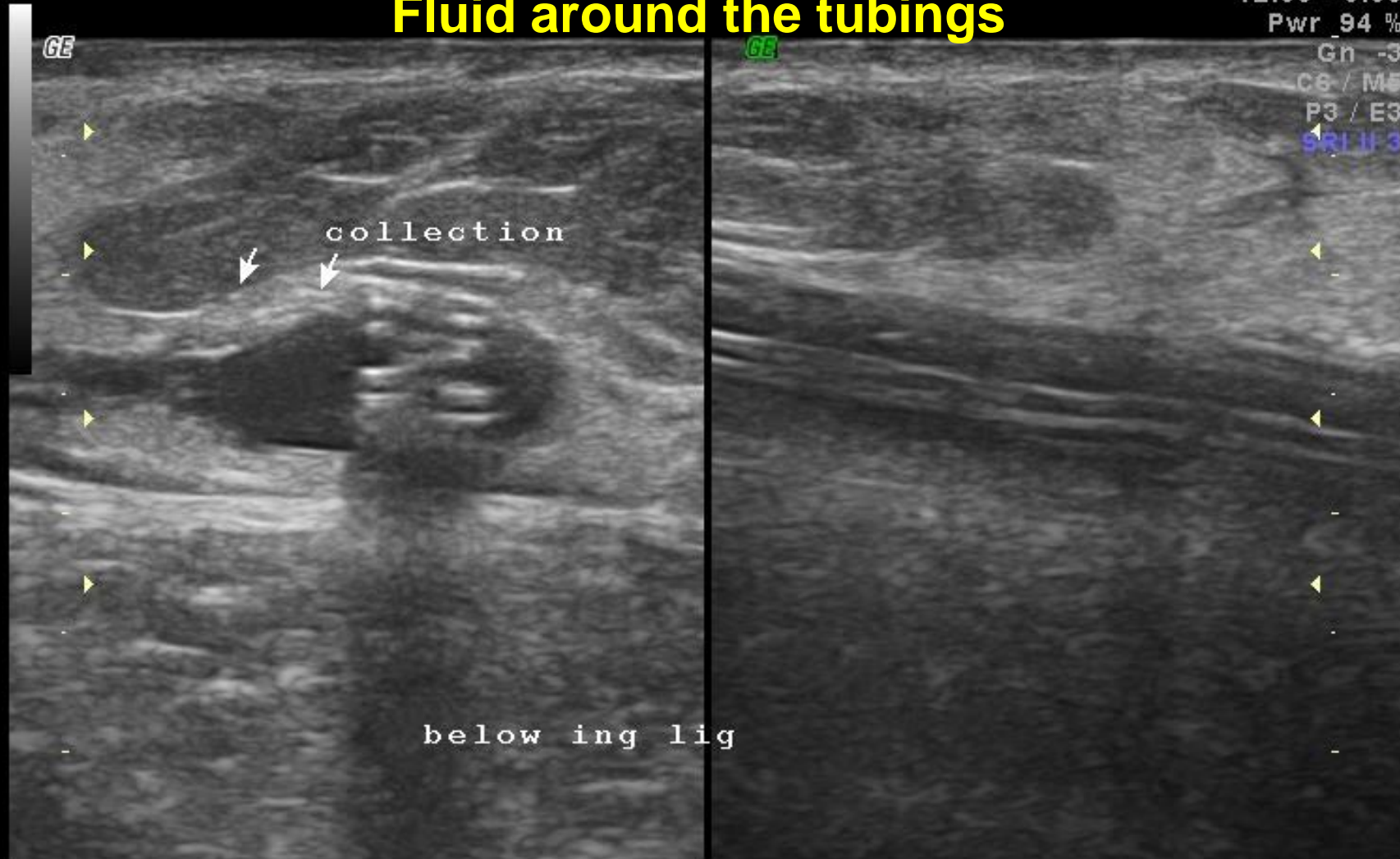
SP 6-12/SM P  
3.5cm / 19Hz

MI 1.0  
TIs 0.1

KARAN X-RAY & SONOGRAPH  
29.04.2014 07:31:11 PM

Small Parts  
12.00 - 3.00  
Pwr 94 %  
Gn -3  
CG / ME  
P3 / E3  
SRI II 3

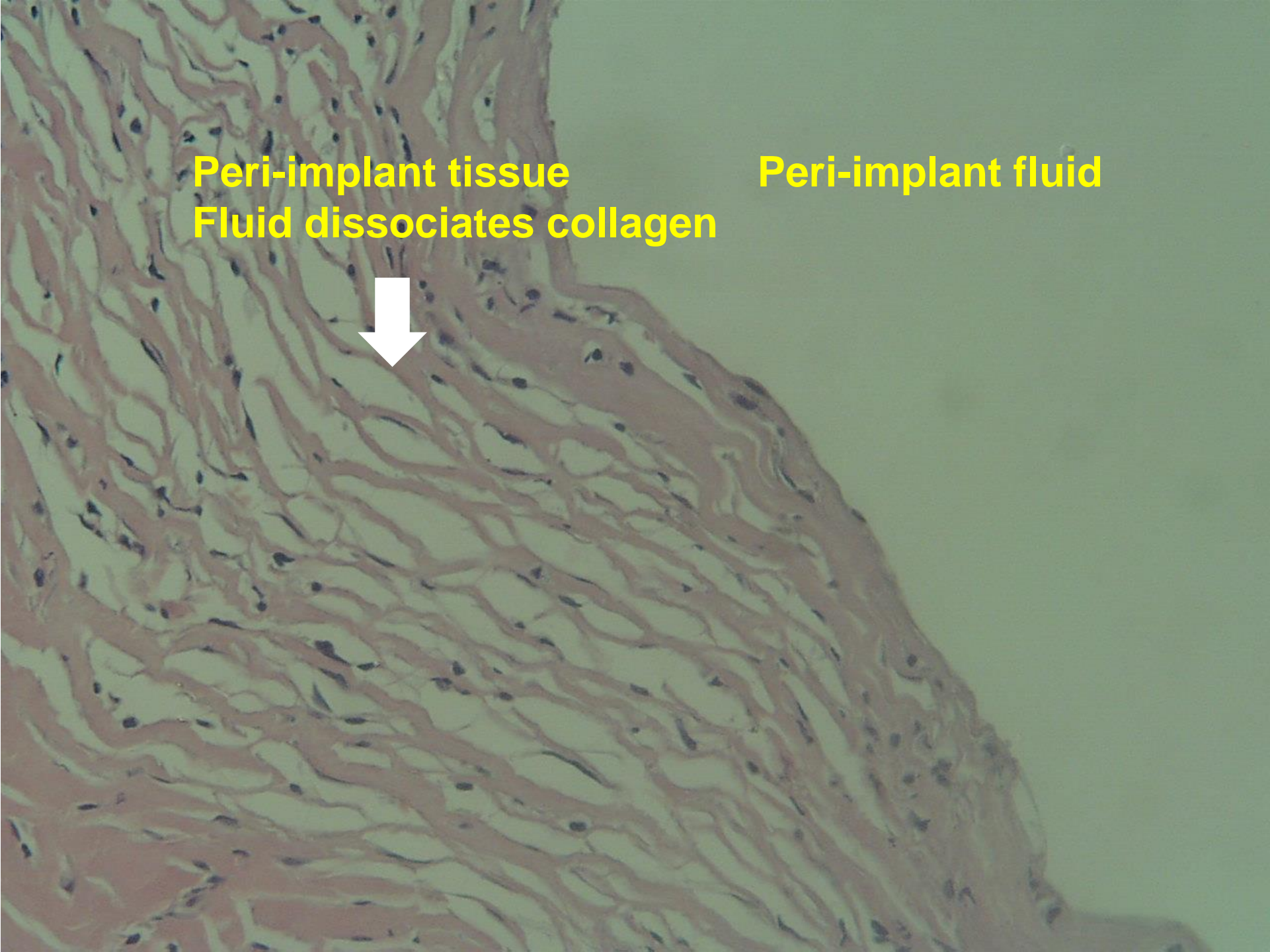
# Fluid around the tubings



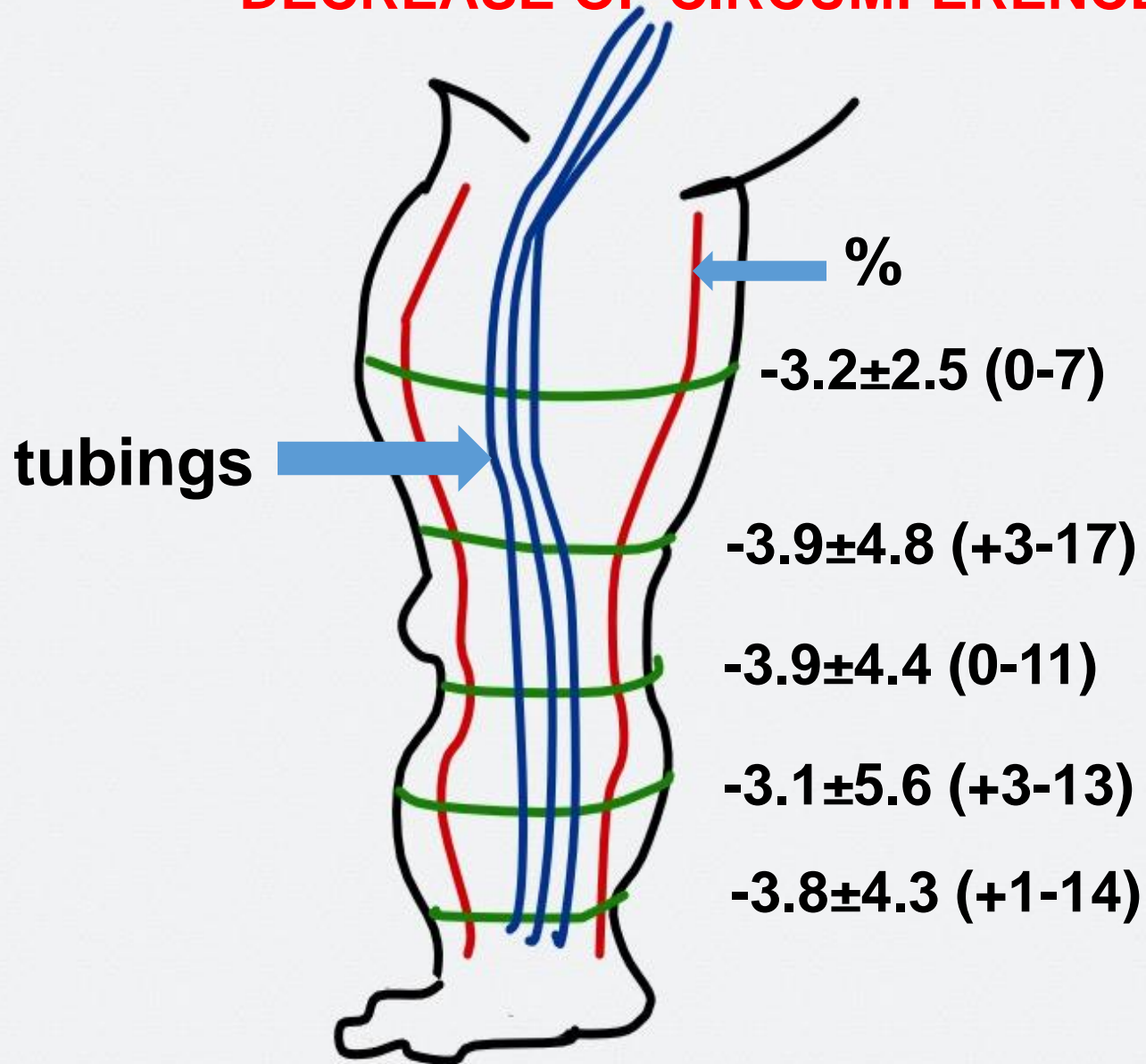
9.6 sec

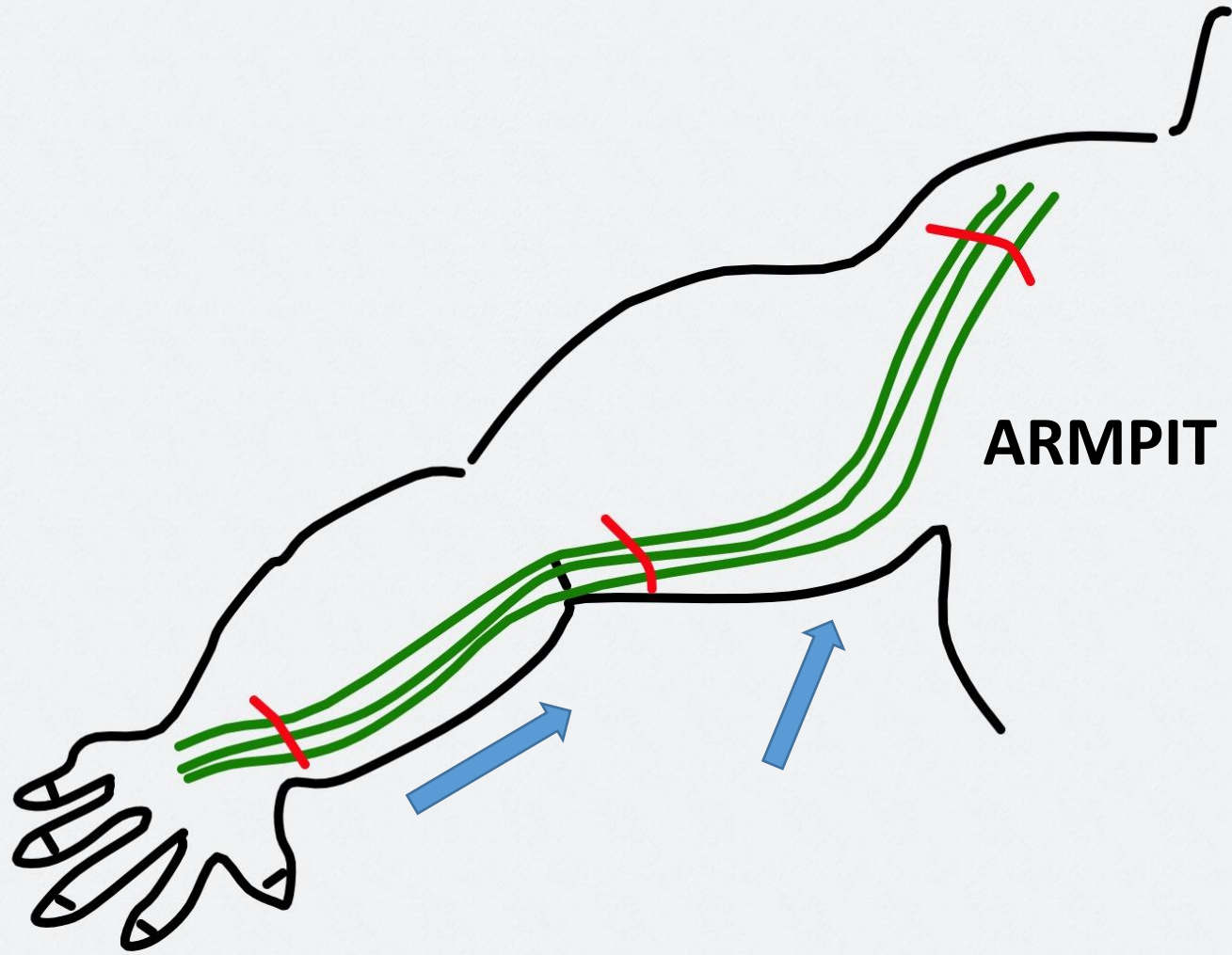
**Peri-implant tissue**  
**Fluid dissociates collagen**

**Peri-implant fluid**



**Follow up 25 pts 12->24 months (mean±SD, range)  
DECREASE OF CIRCUMFERENCE**

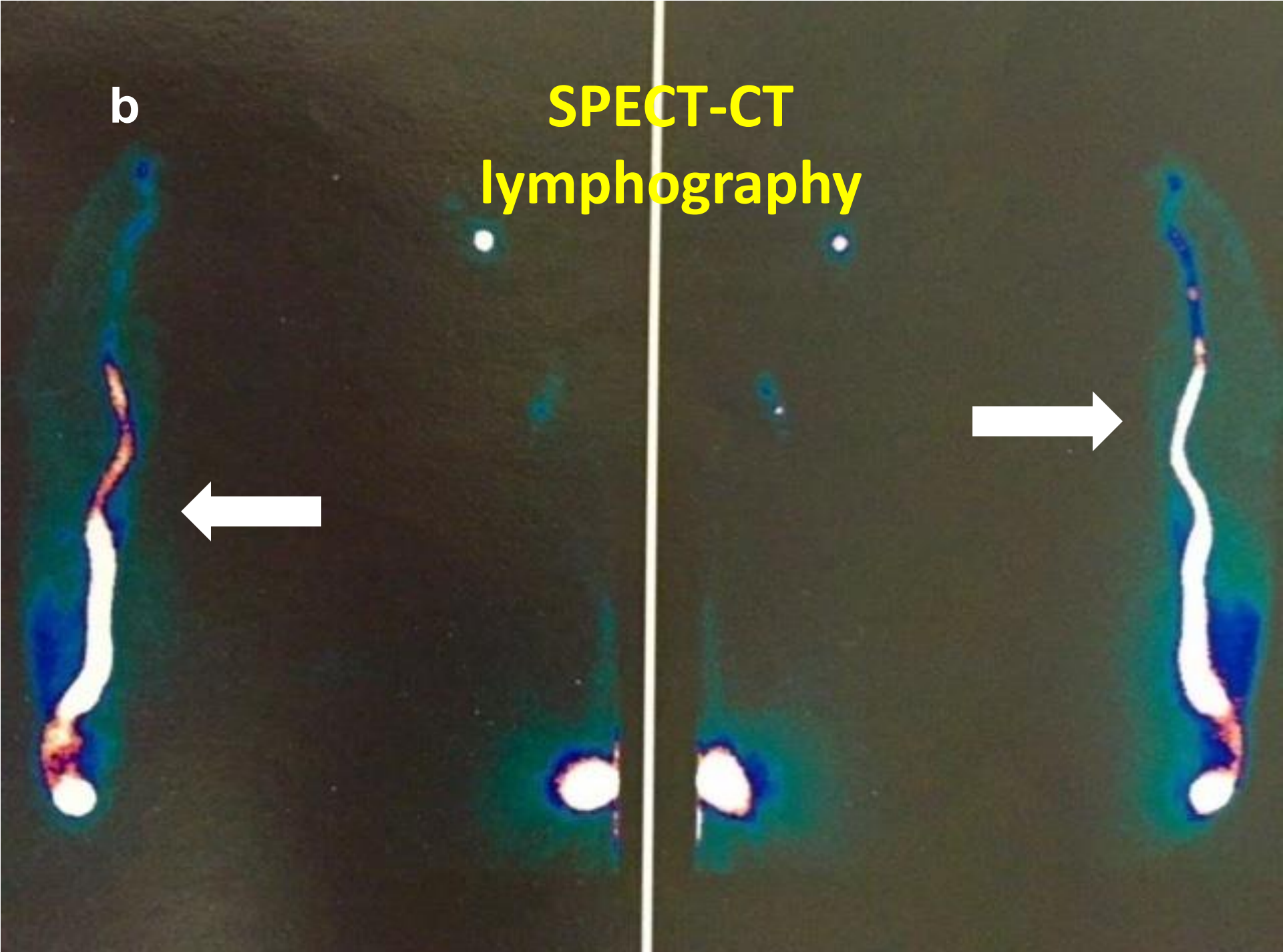




ARMPIT

**b**

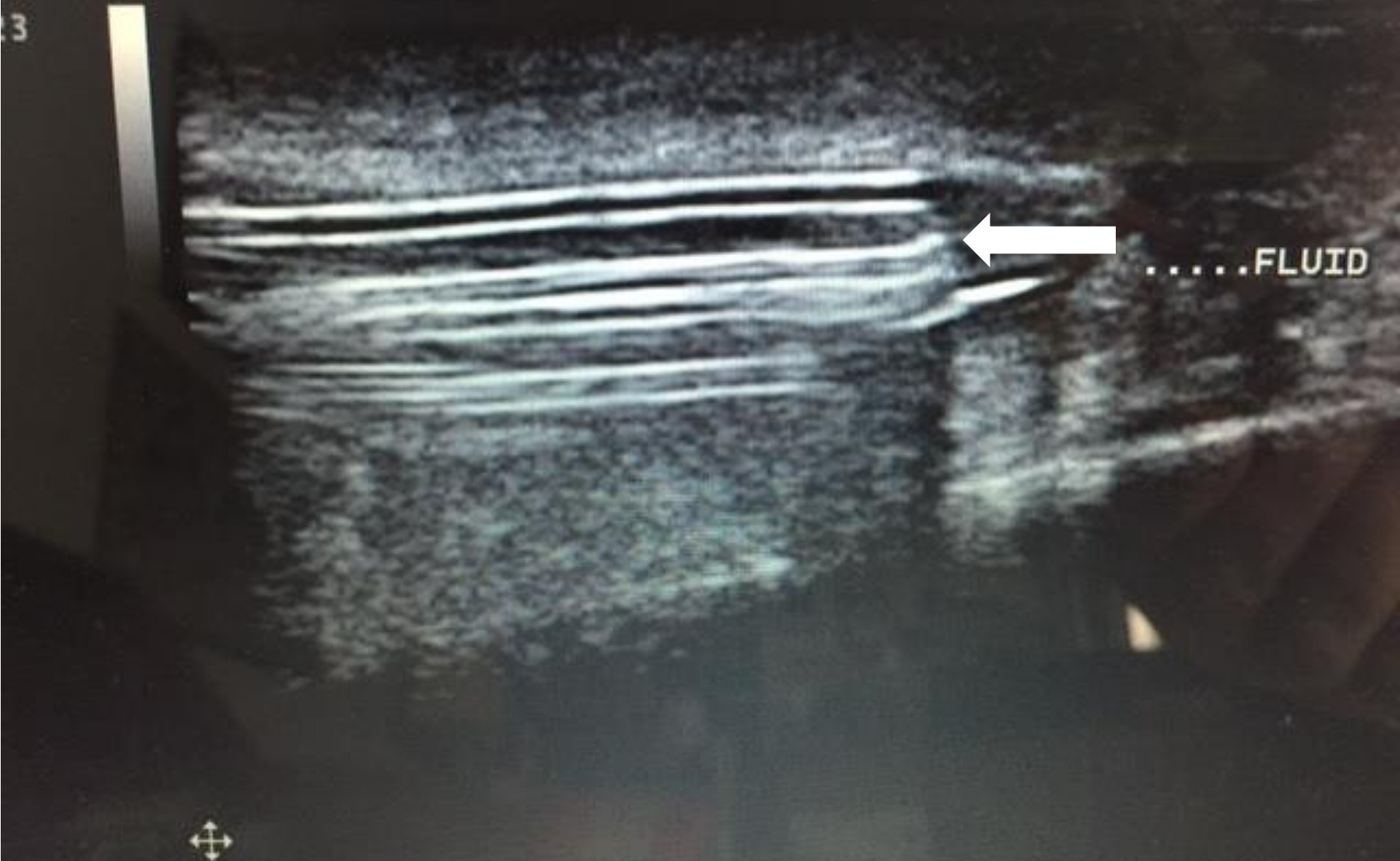**SPECT-CT  
lymphography**



PRE 11 2 PRE 11 2  
PST 4

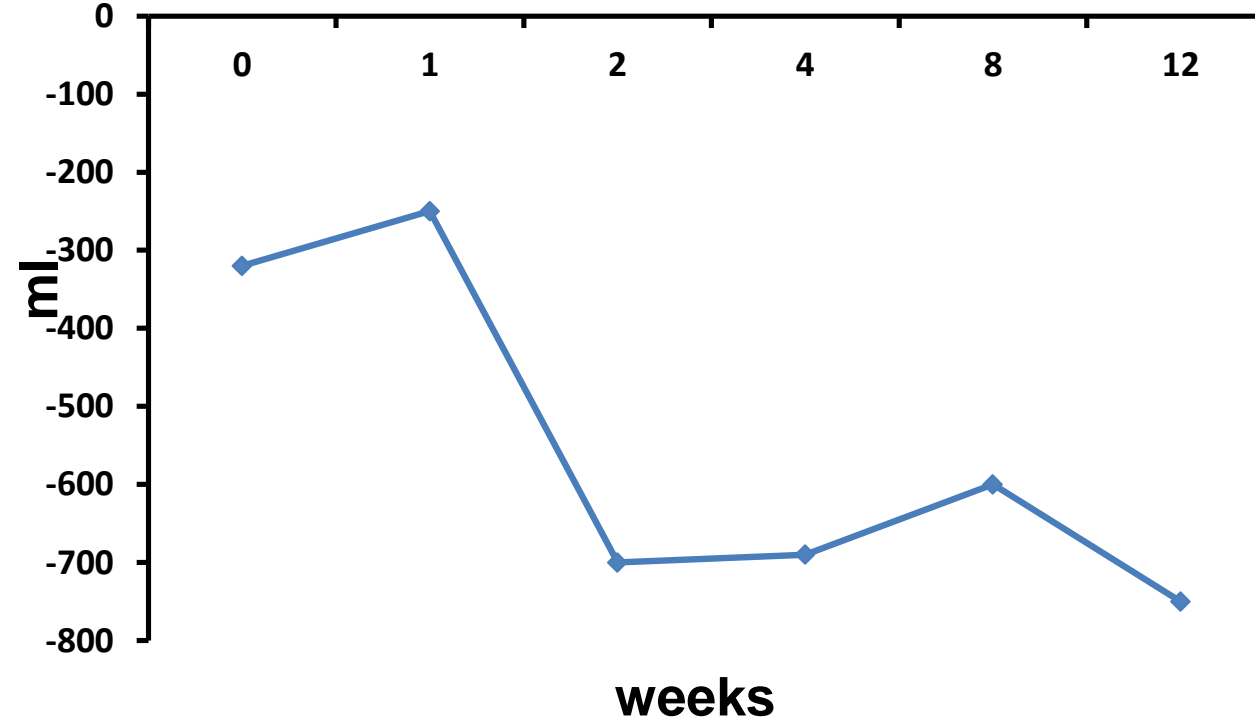
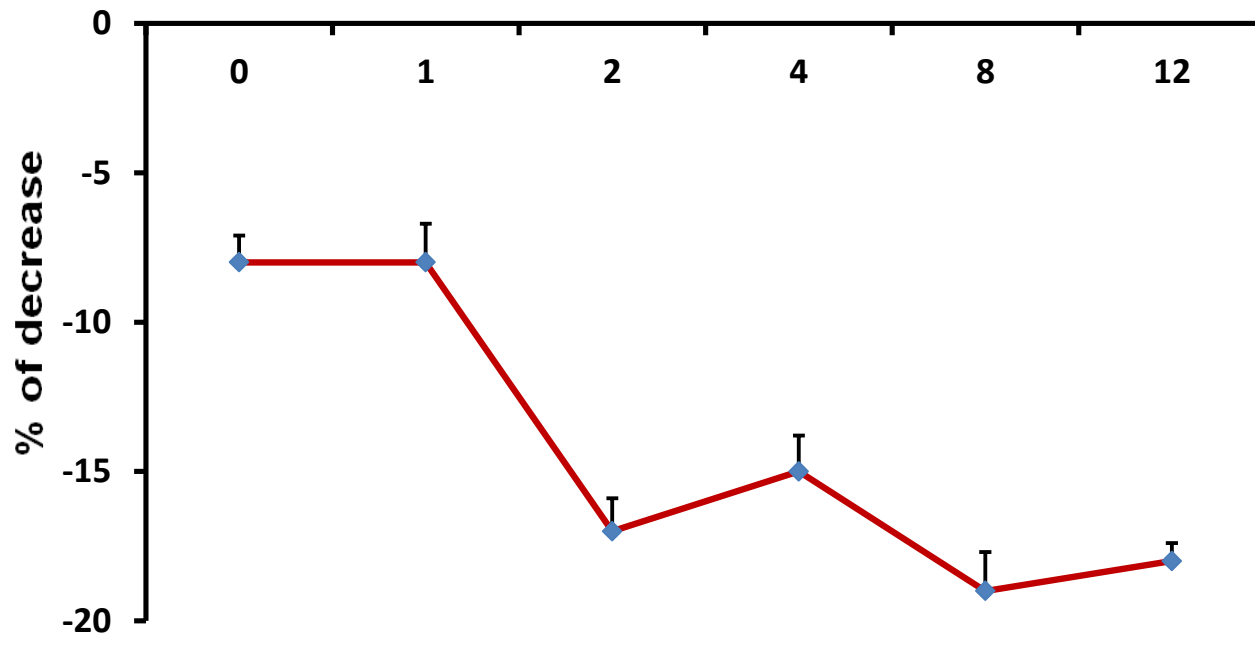
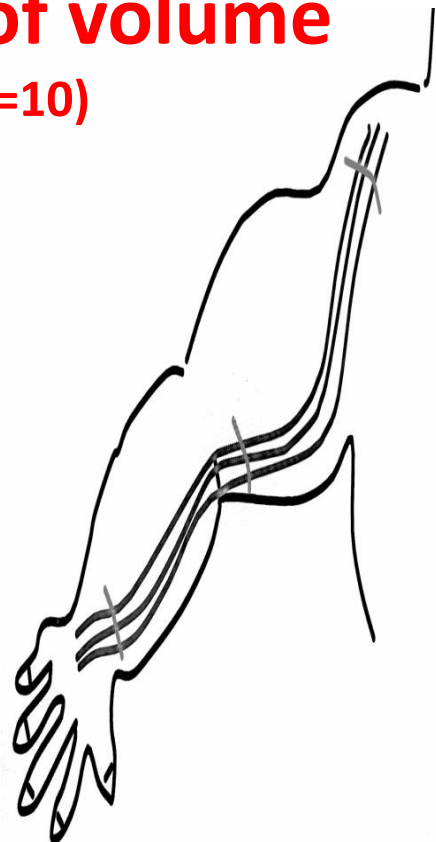
a

3



DISTAL END

# ONE-year results, change of volume (n=10)



## CONCLUSIONS

Silicone tubing implants in lymphedematous is a new low-invasive effective method for decompression of obstructive lymphedema.