

1408

CONTROVERSES ET ACTUALITÉS EN CHIRURGIE VASCULAIRE
CONTROVERSIES & UPDATES IN VASCULAR SURGERY

JANUARY 19-21 2017

MARRIOTT RIVE GAUCHE & CONFERENCE CENTER
PARIS, FRANCE



Treatment of telangiectasias by microsurgery

Traitement des télangiectasies par microchirurgie

Albert-Adrien Ramelet
Inselspital, Bern (Switzerland)



Disclosure

I do not have any potential conflict of interest

Dr Dr hc Albert-Adrien Ramelet
Inselspital, Bern (Switzerland)

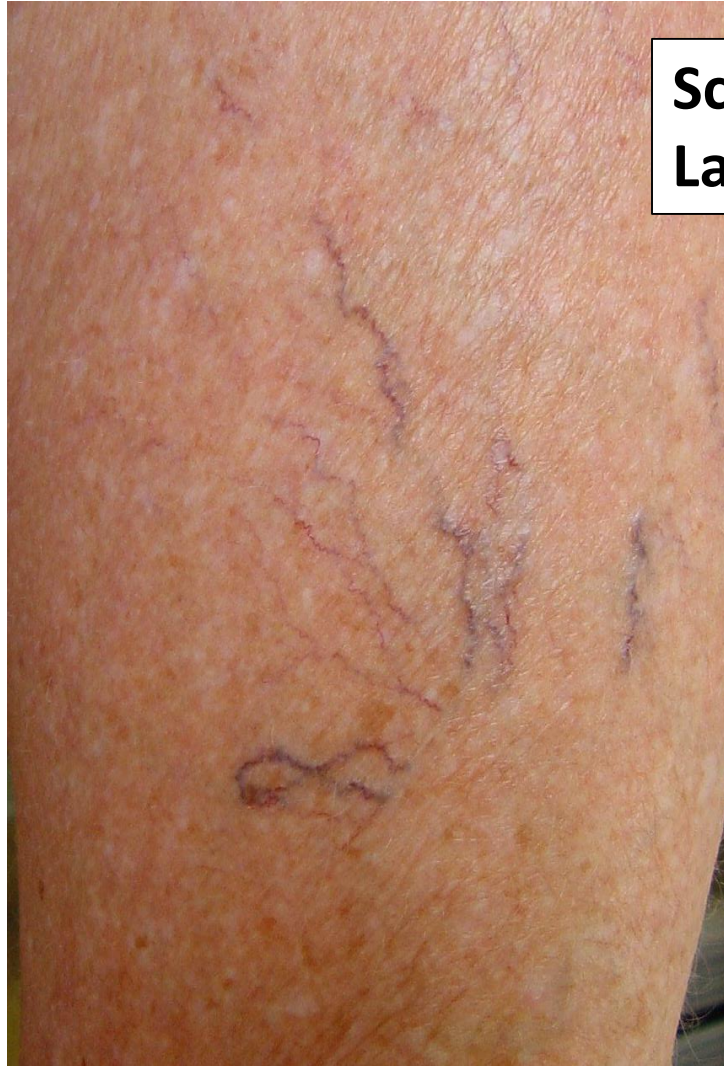

Telangiectasias

- **Definition:** intra-dermal dilatations of the sub-papillary venous plexus
- **Badly defined entity (clinic and physiopathology)**
- **Large differential diagnosis**
- **Not strictly varicose veins**
- **Frequently reveal CVD of which they are one of the clinical signs (class C1 of the CEAP classification)**

Telangiectasias

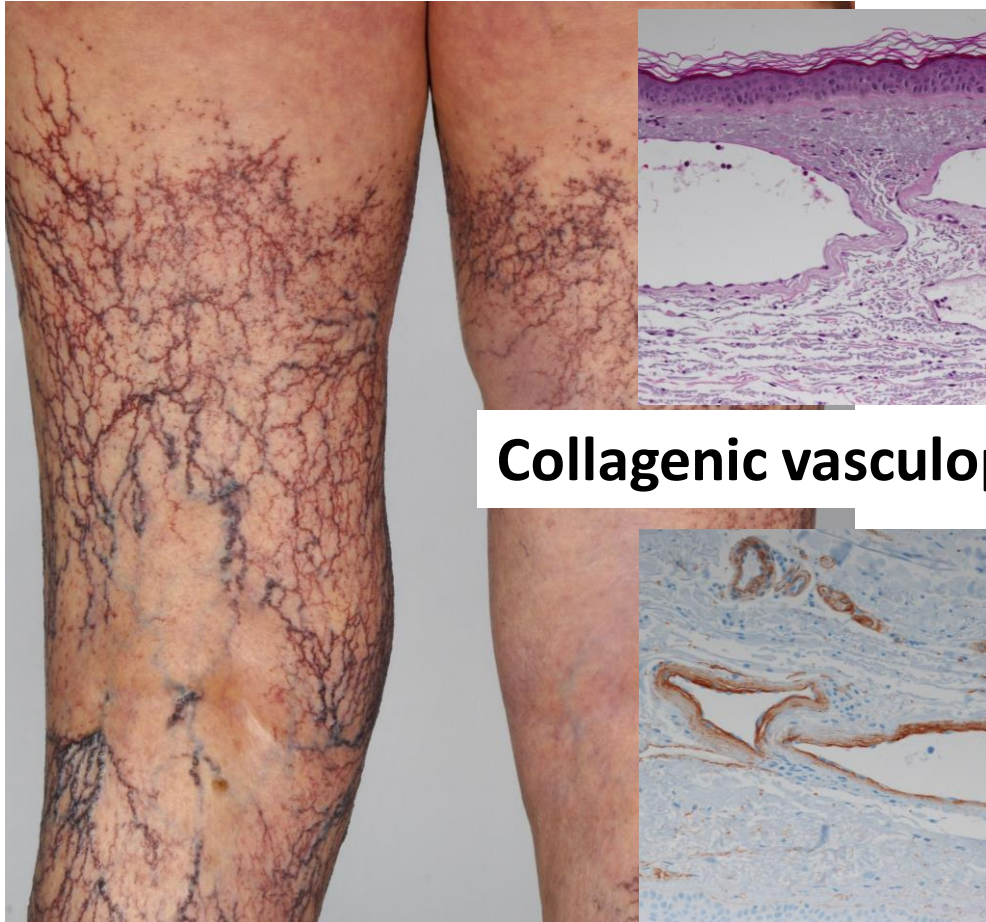- **Isolated**
- **Diffuse**
- **Consecutive to venous reflux**



**Sclerotherapy
Laser**

Telangiectasias

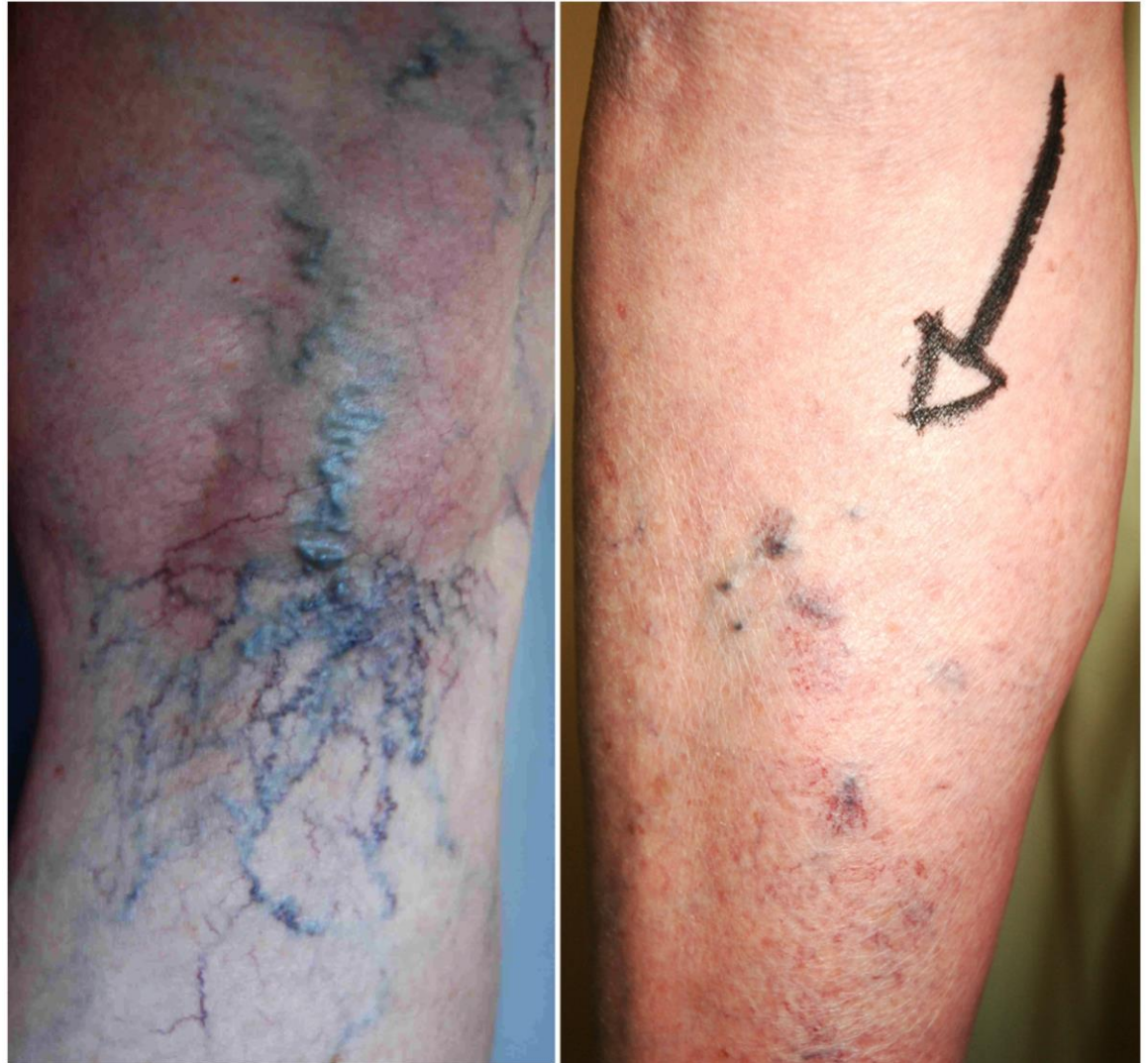- Isolated
- **Diffuse**
- Consecutive to venous reflux



Collagenic vasculopathy

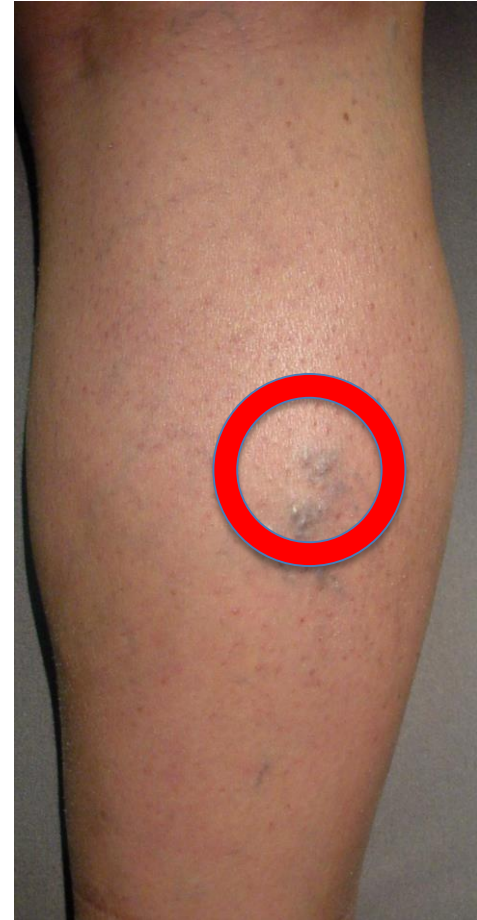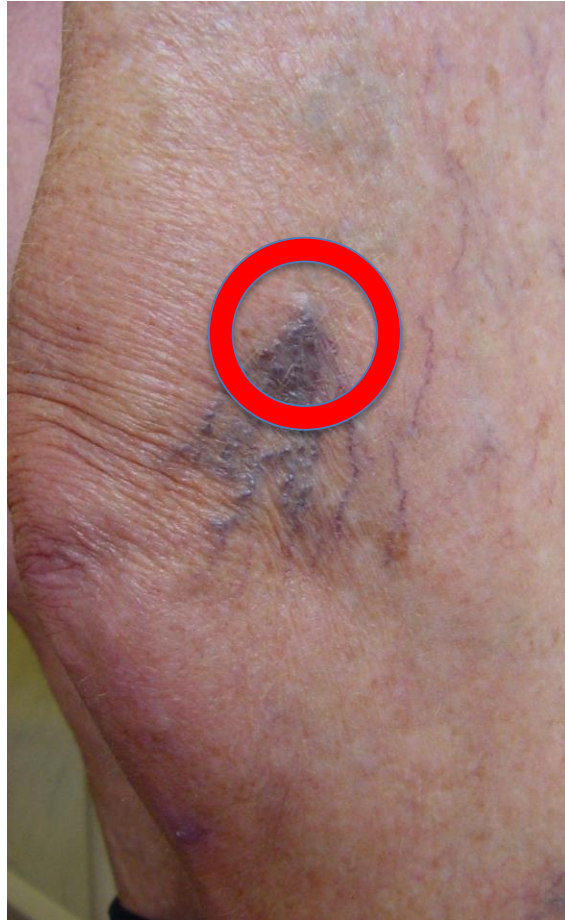Telangiectasias

- Isolated
- Diffuse
- **Consecutive to venous reflux**



Telangiectasias

- Isolated
- Diffuse
- **Consecutive
to venous
reflux**



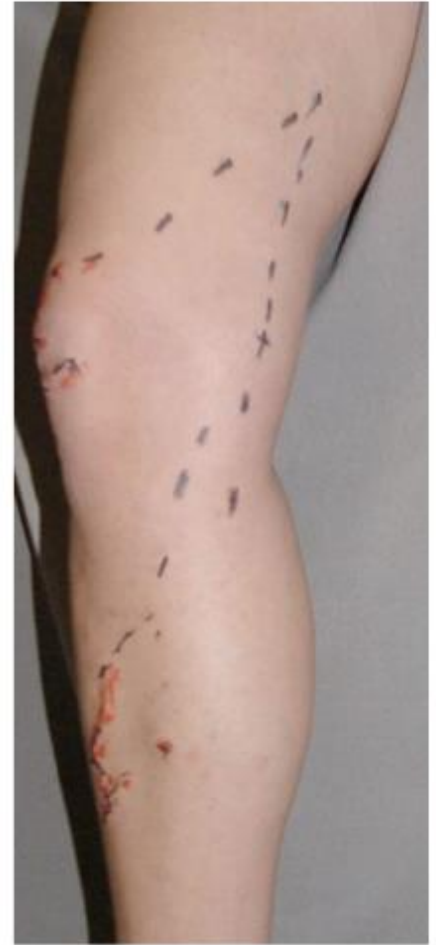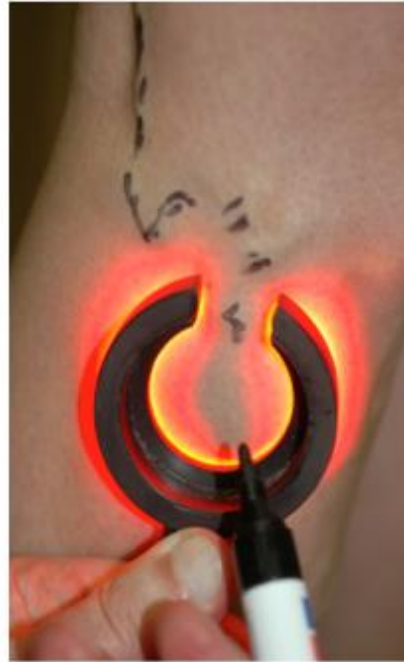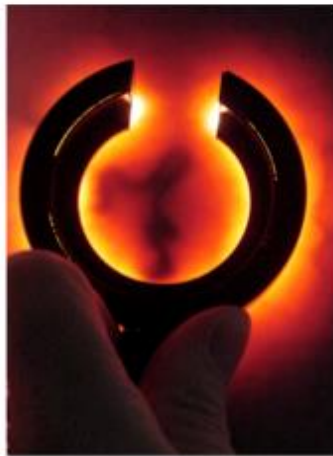Investigations

- **Mandatory**
 - Feeding veins' or perforator reflux ?
- **Clinical examination**
 - Standing
 - Lying
 - Side-illumination
- **Duplex**

Side-illumination (épiscopie, lumière froide)

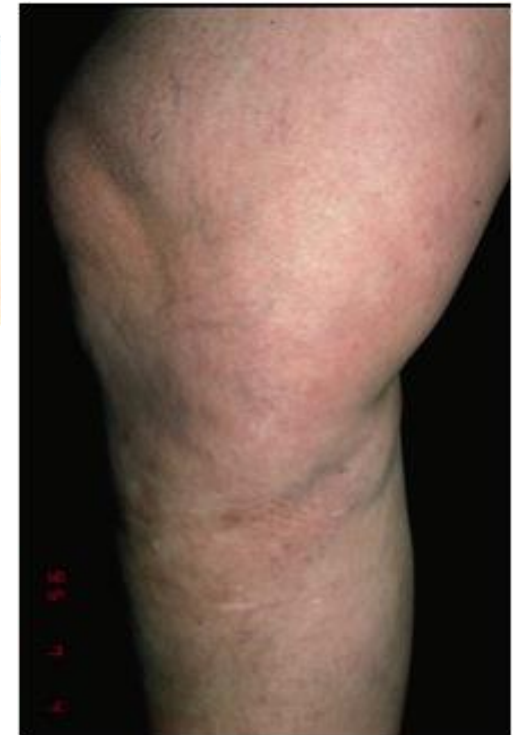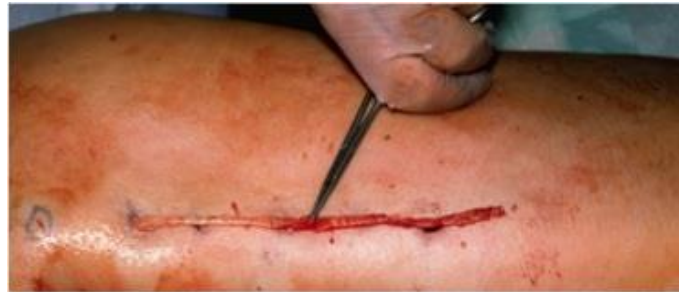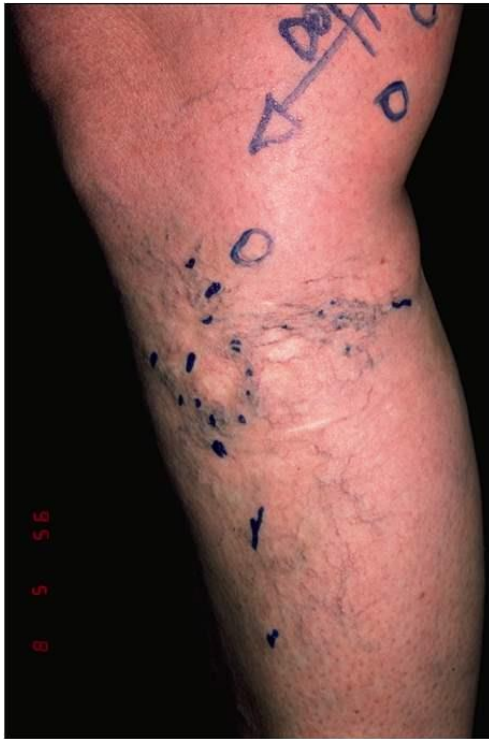Diagnostic
Preoperative marking
Easy – Simple - Effective
Economic

Sclerotherapy of feeder vein



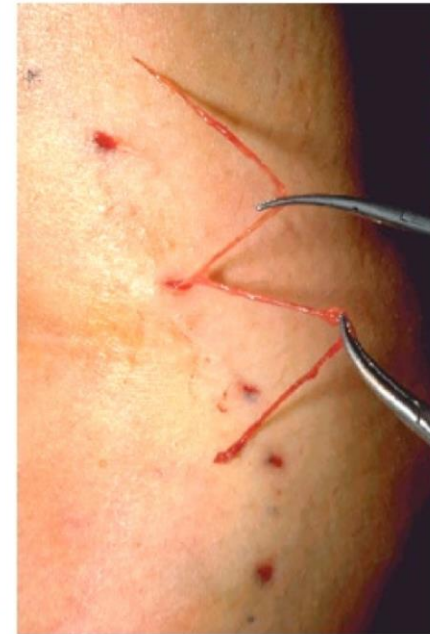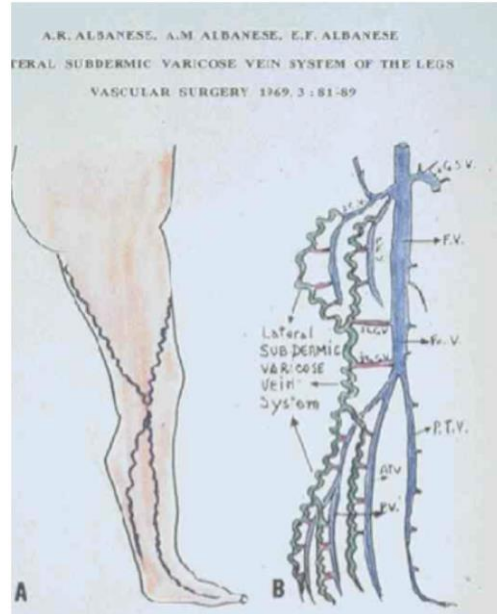
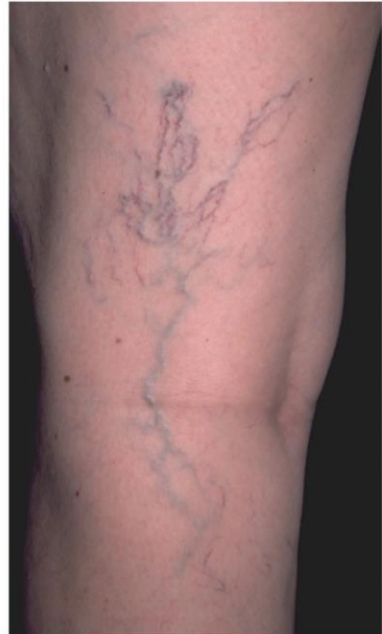Surgery - Phlebectomy - EVT

- Saphenous or tributaries' insufficiency



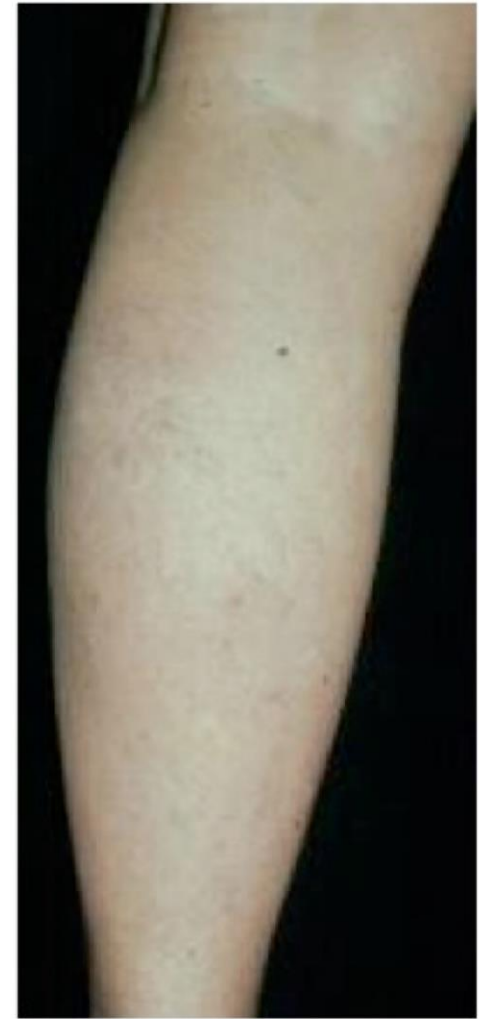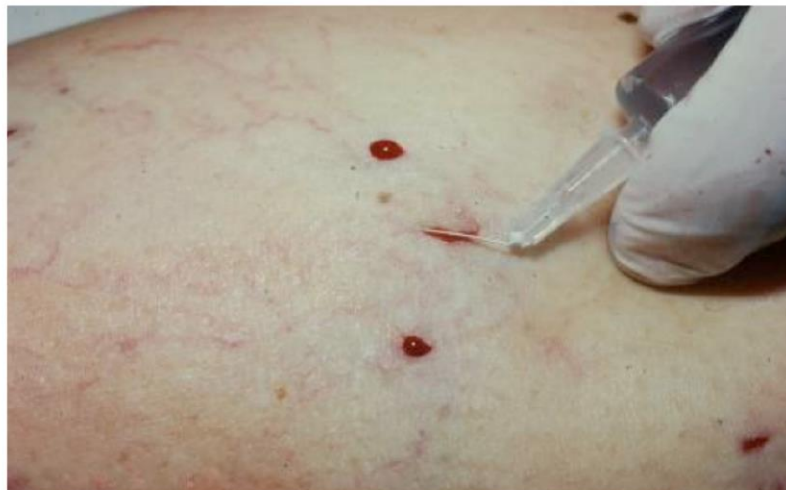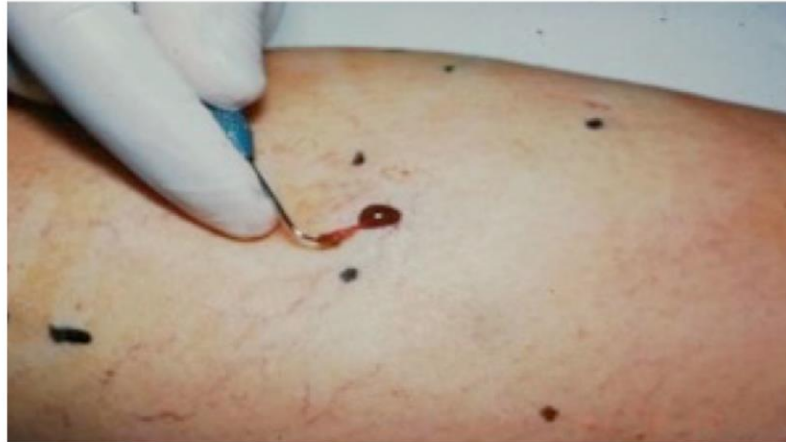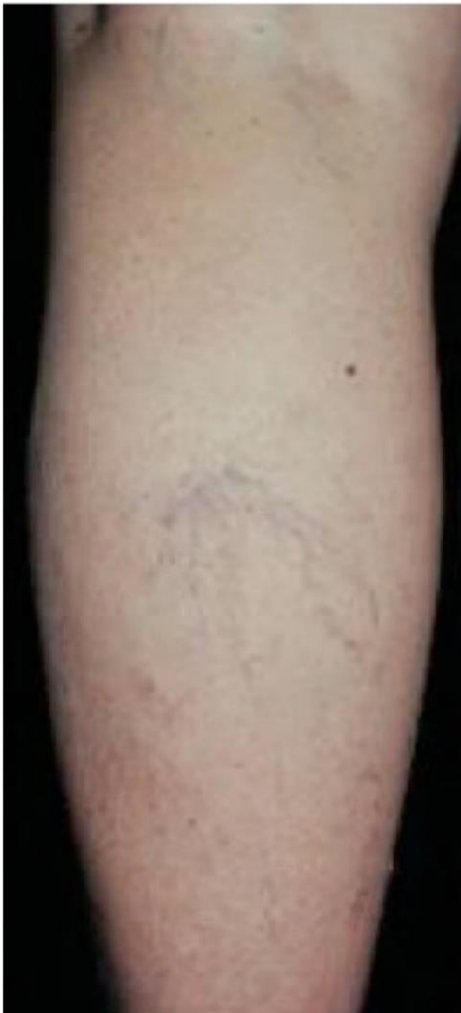Microsurgery - Phlebectomy

Reticular veins

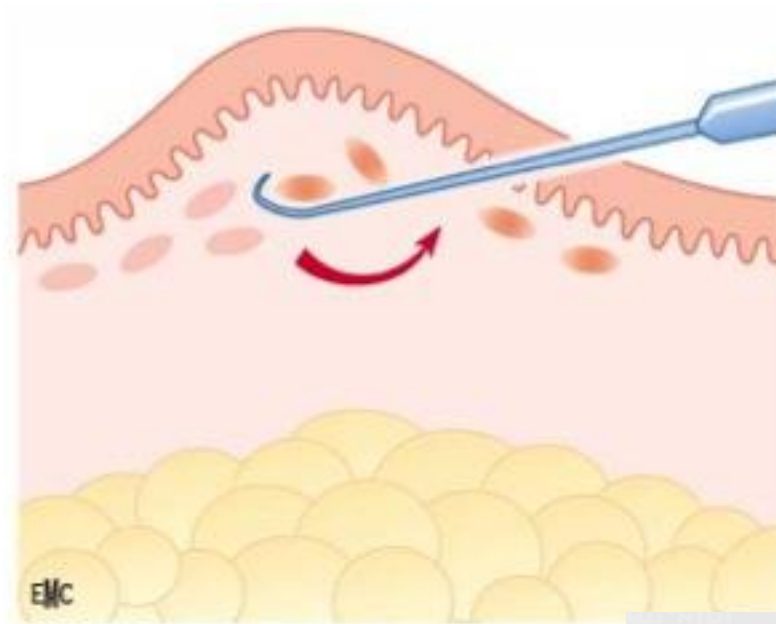
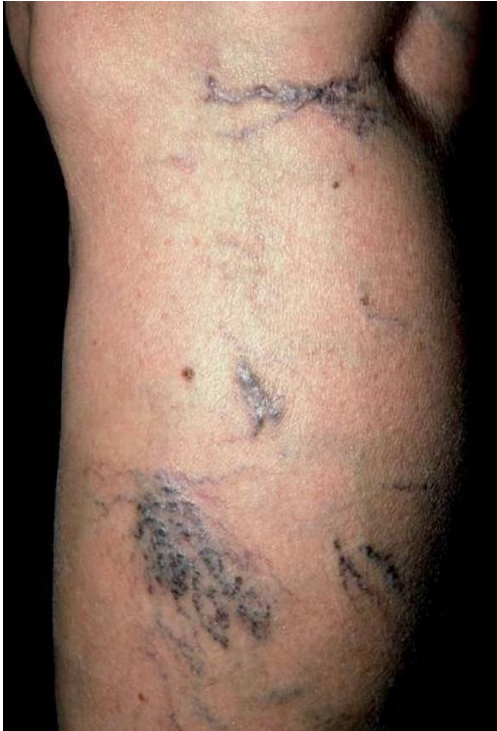

Microsurgery - Phlebectomy


Small perforators



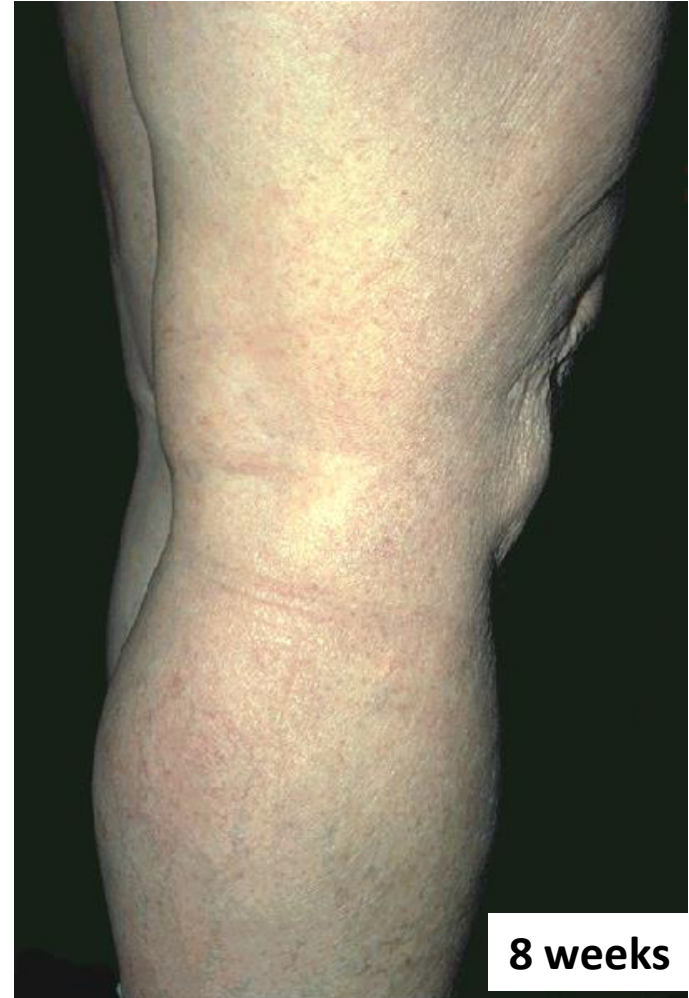
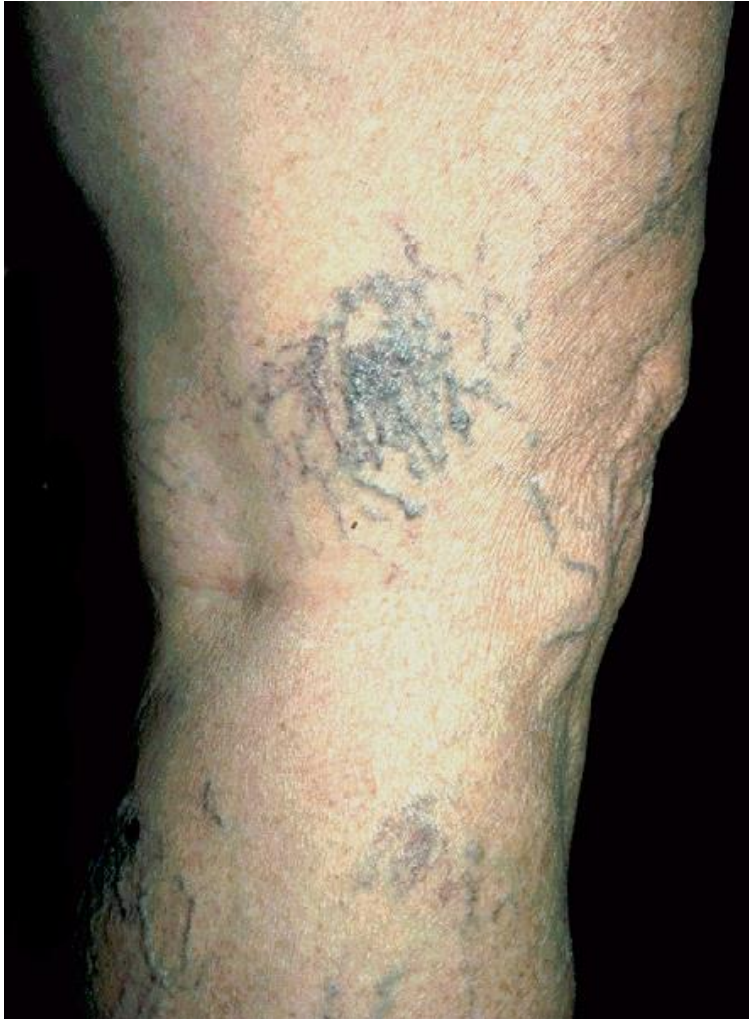Microsurgery - Curettage



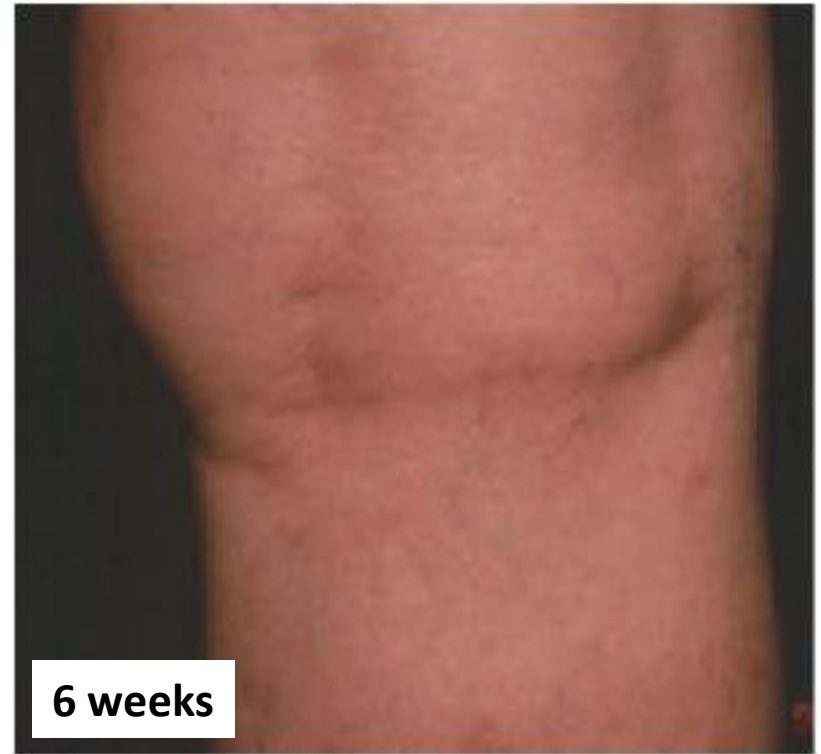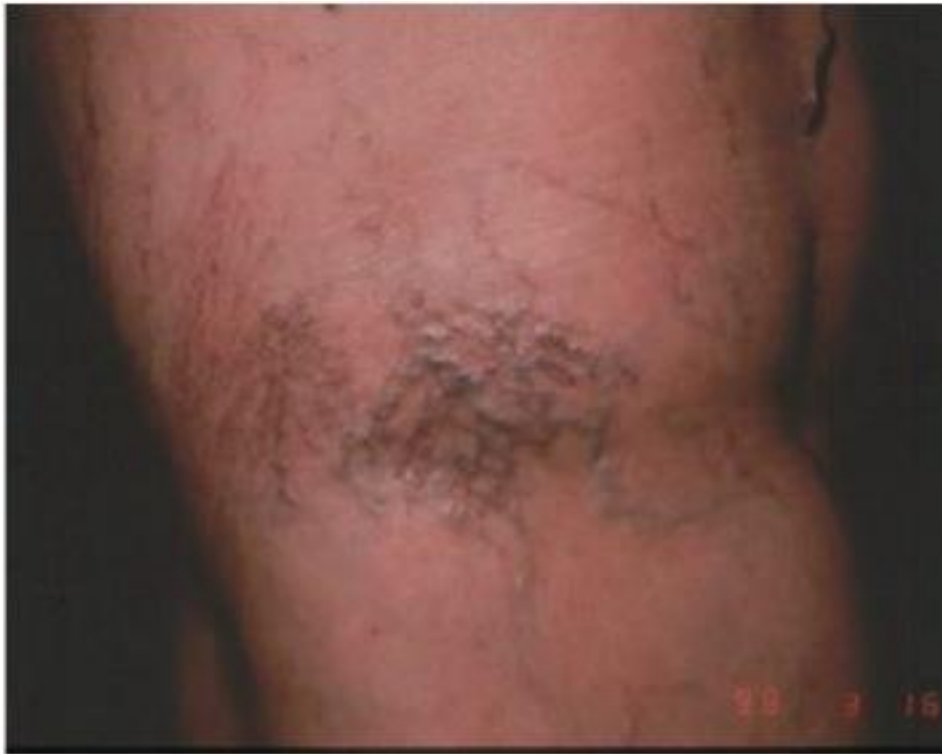Peroperative sclerotherapy



Curettage – peroperative sclerotherapy



Curettage – peroperative sclerotherapy



Peroperative sclerotherapy - START

Sclerotherapy

in

Tumescent

Anaesthesia

of

Reticular veins

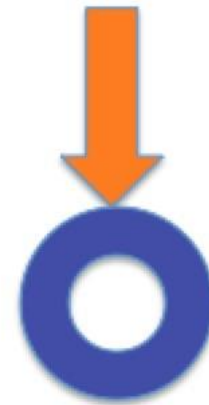and

Telangiectasias

Ramelet A.-A.

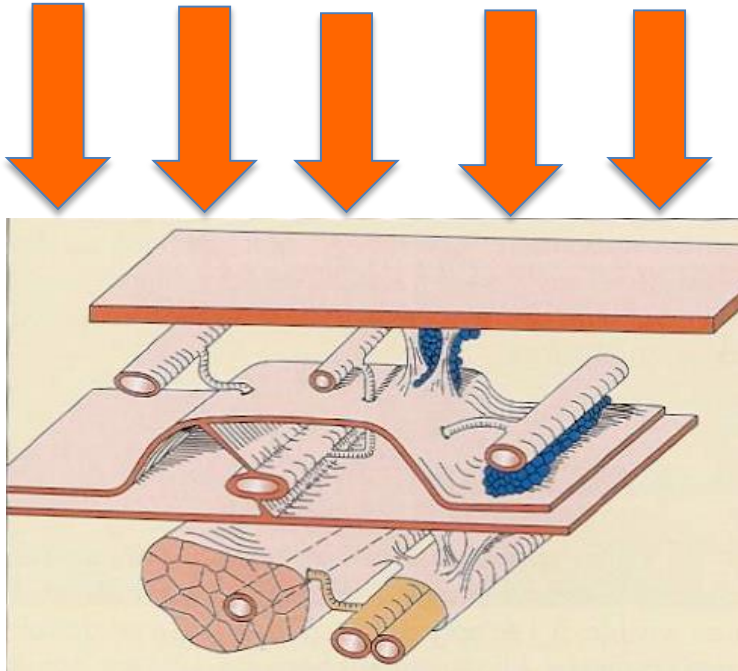
Dermatol Surg. 2012;38(5):748-51

Concept: Compression !

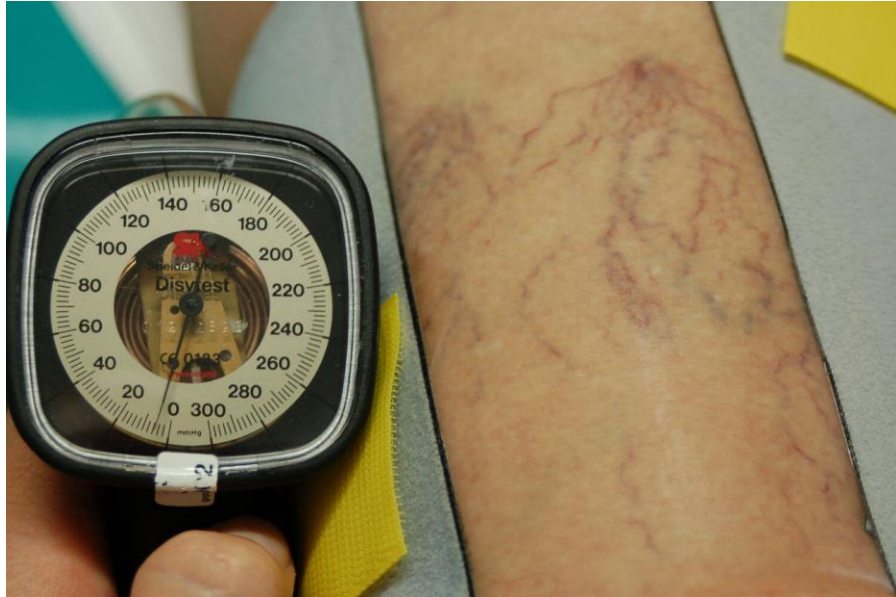

Compression ?

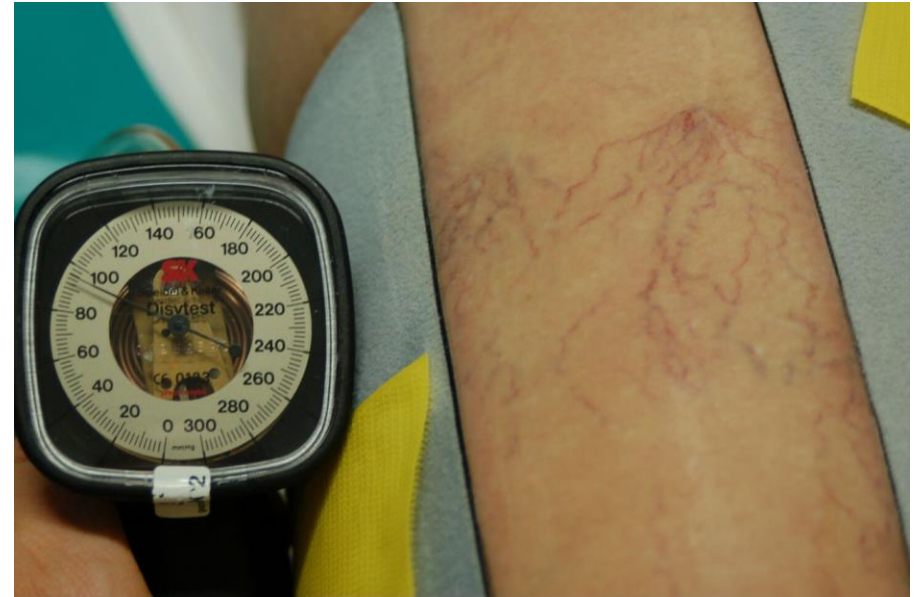
Stockings



Spider veins cannot be compressed



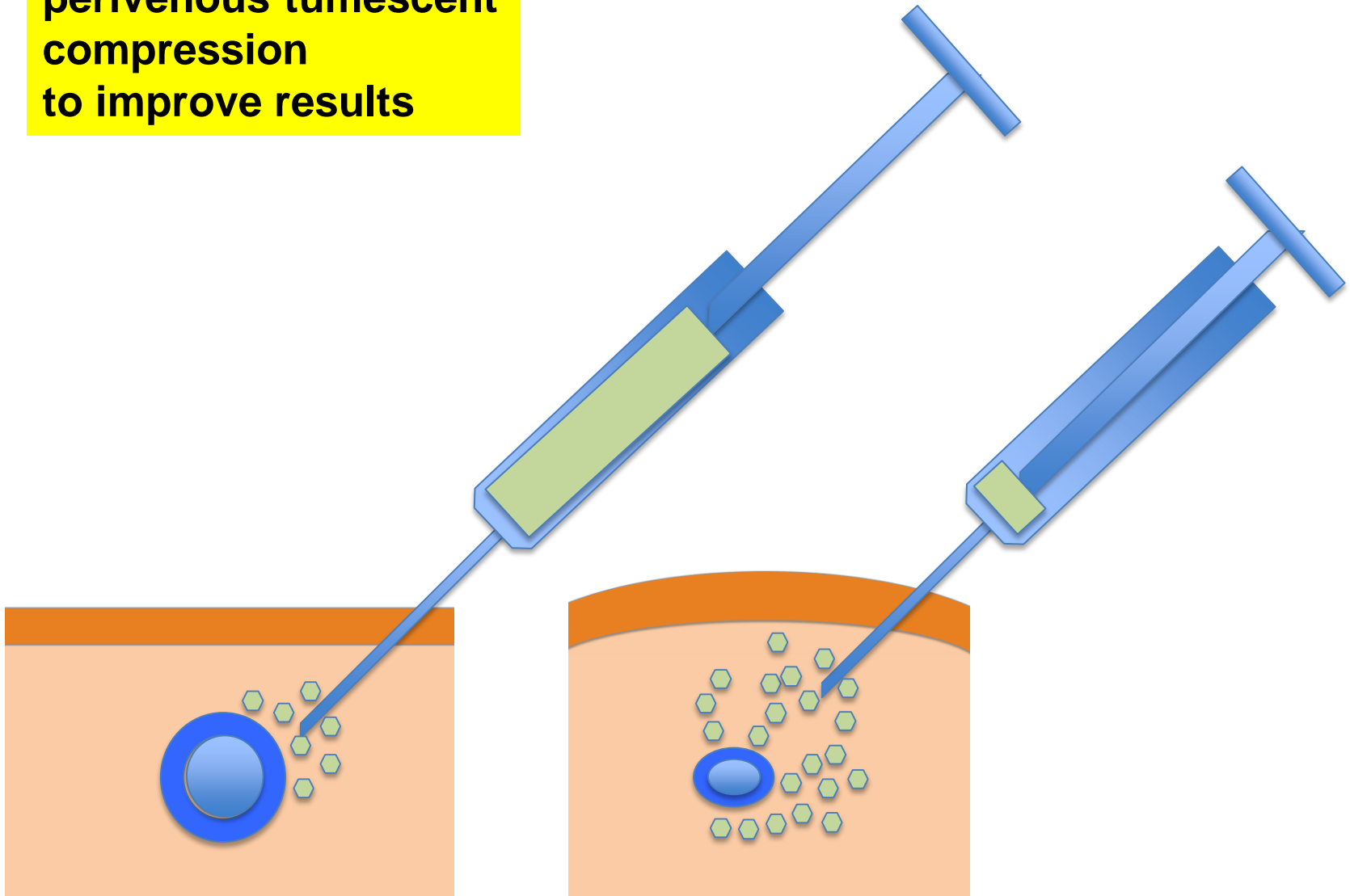
6 mm Hg



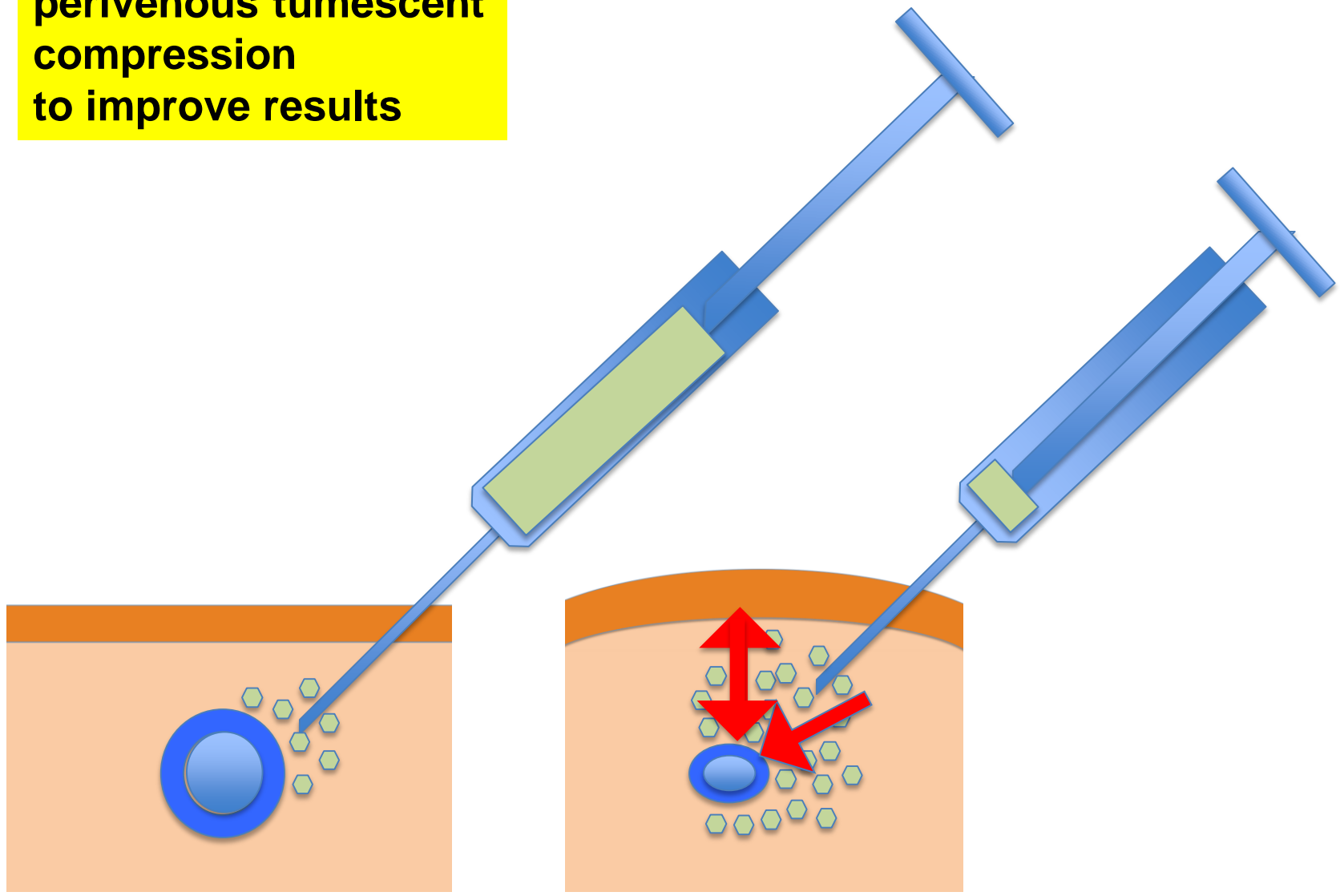
100 mm Hg

Collection H. Partsch

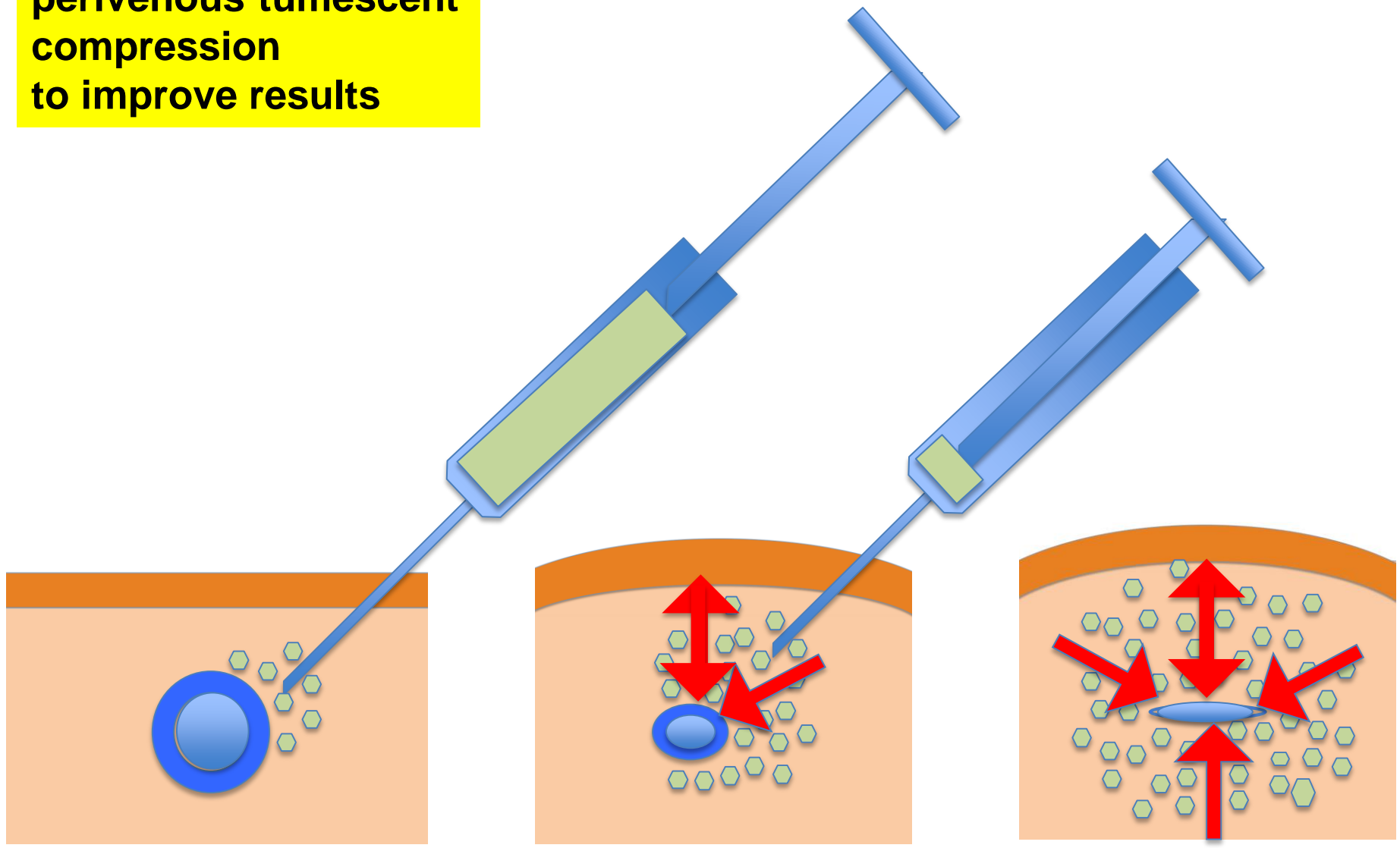
**Post-sclerotherapy
perivenous tumescent
compression
to improve results**



**Post-sclerotherapy
perivenous tumescent
compression
to improve results**

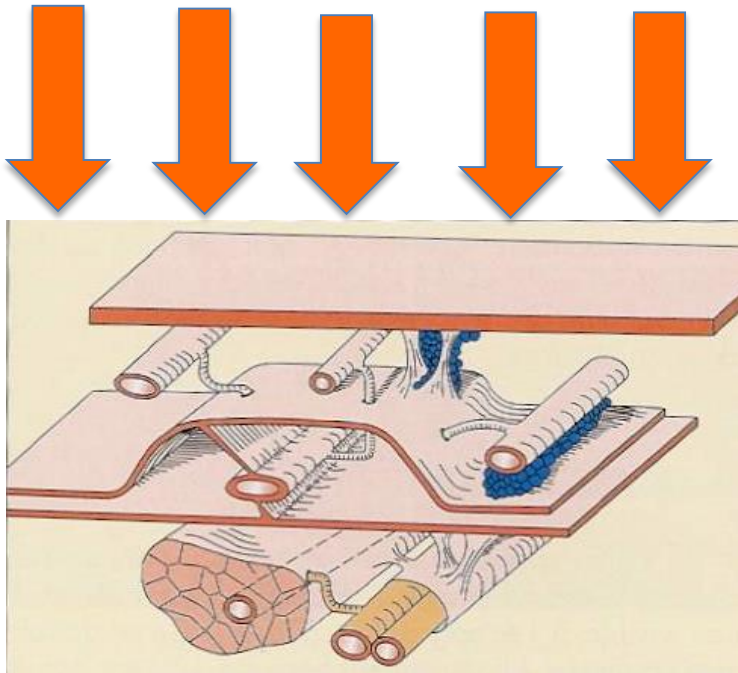


**Post-sclerotherapy
perivenous tumescent
compression
to improve results**

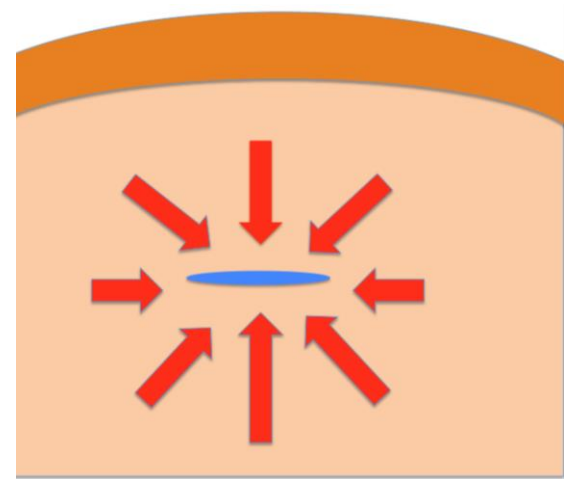


Compression ?

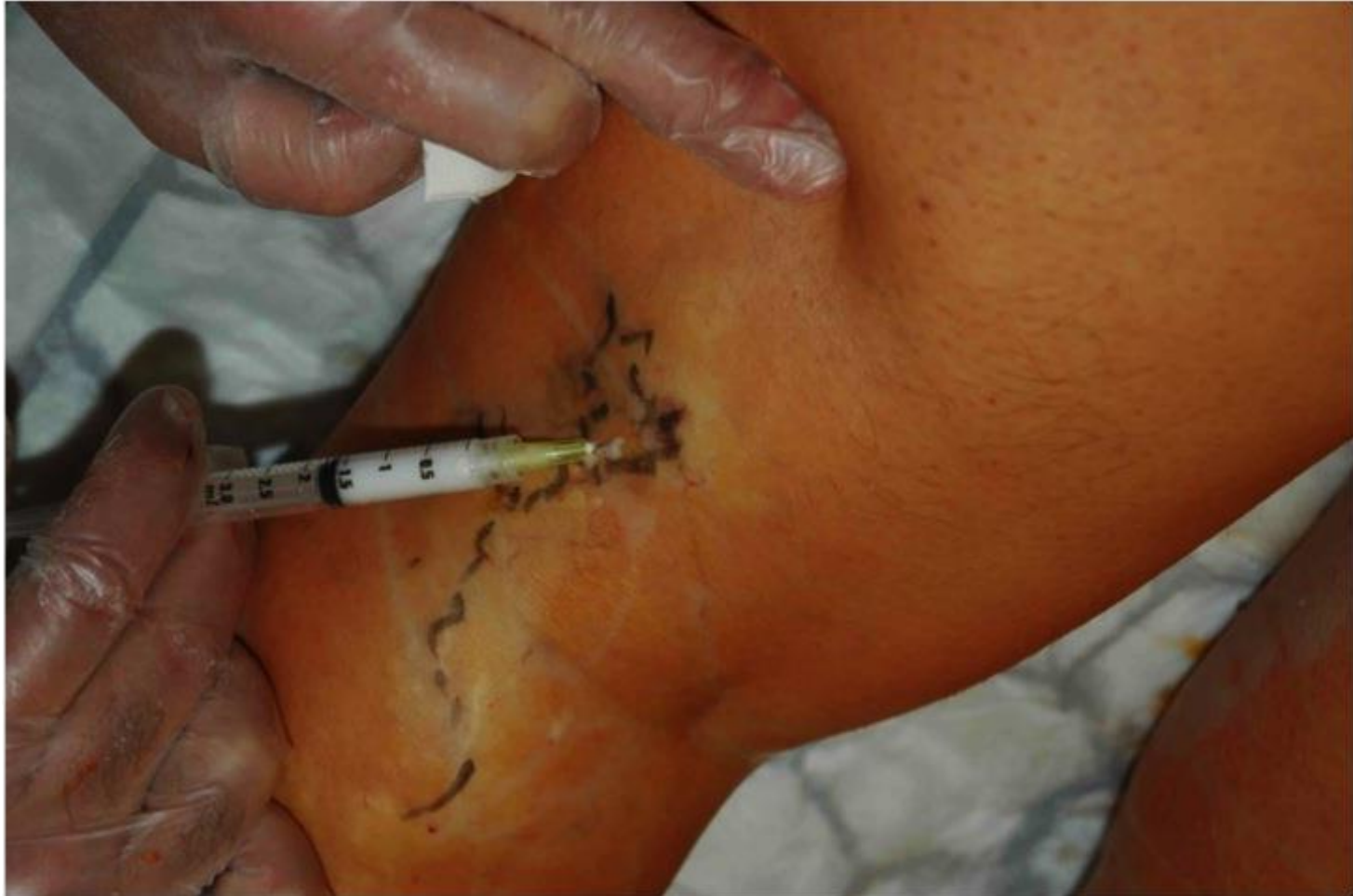Stockings



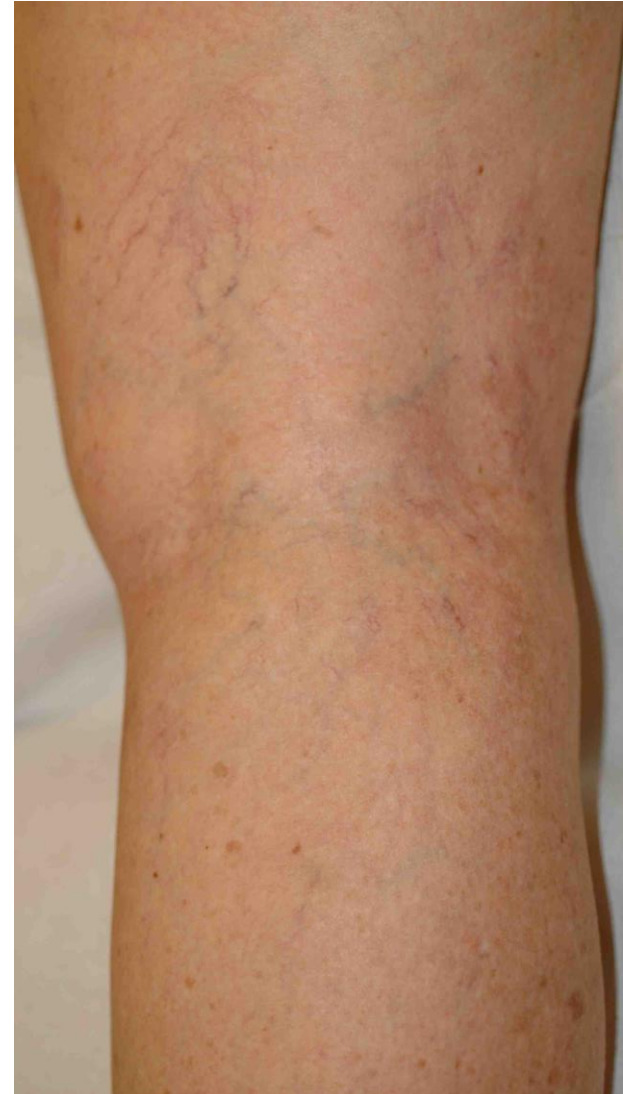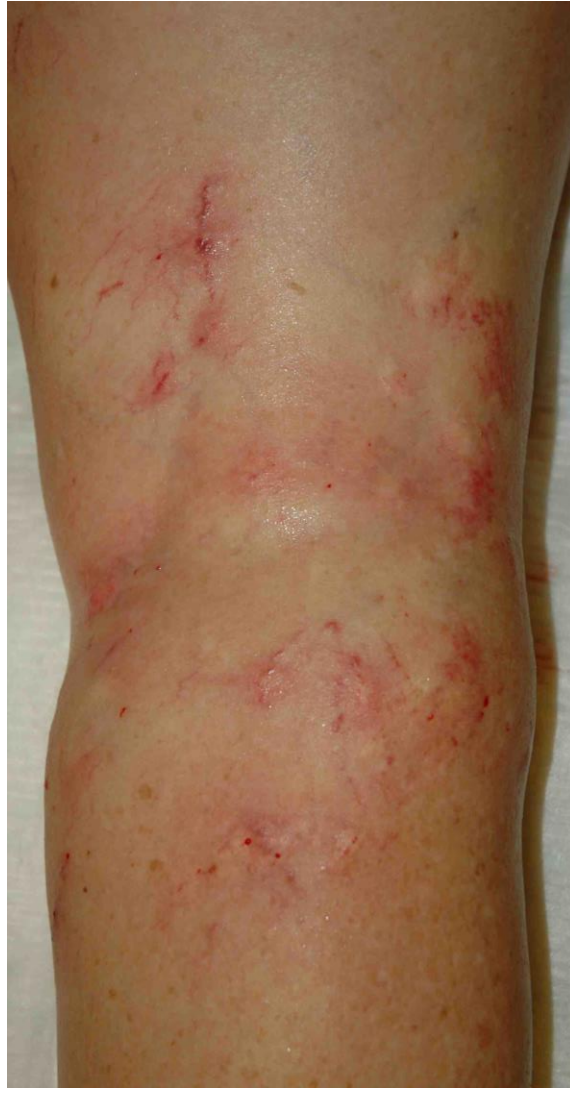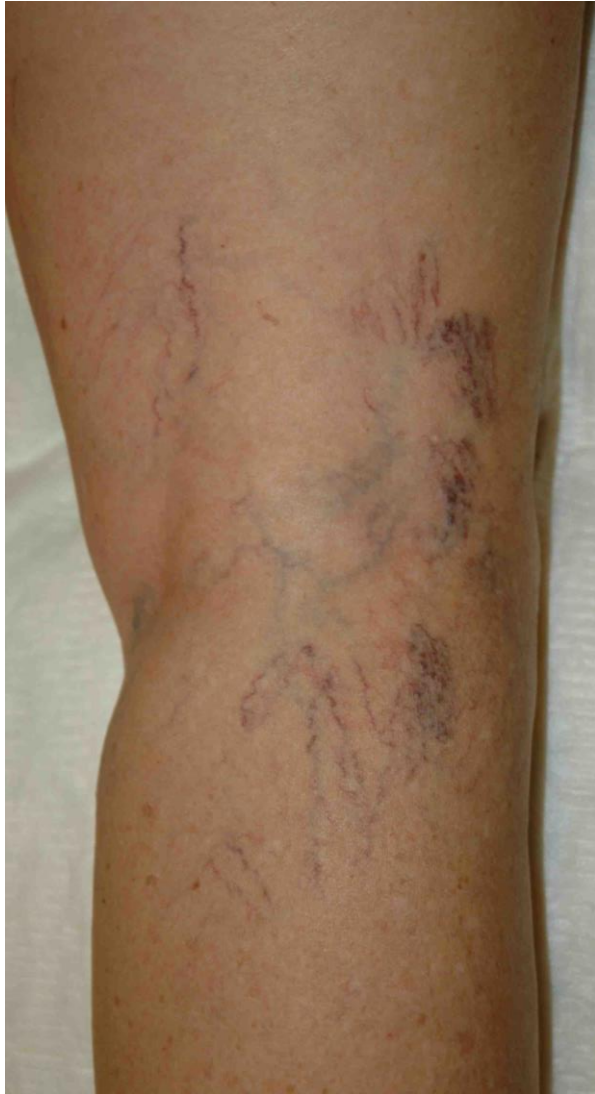Perivenous compression



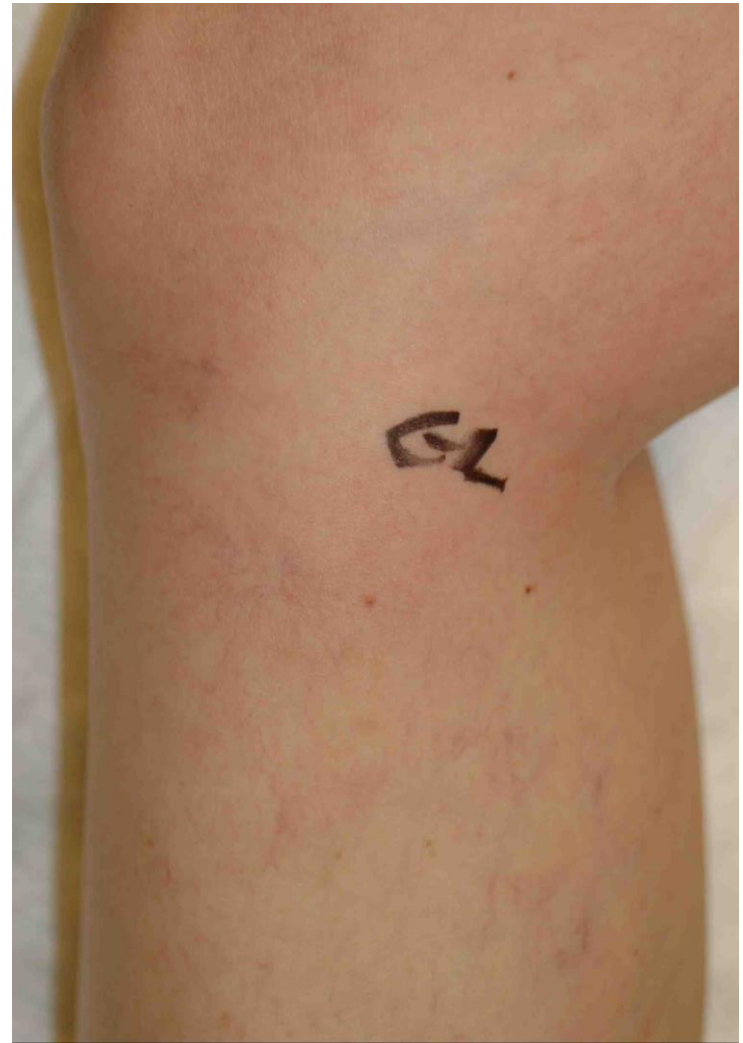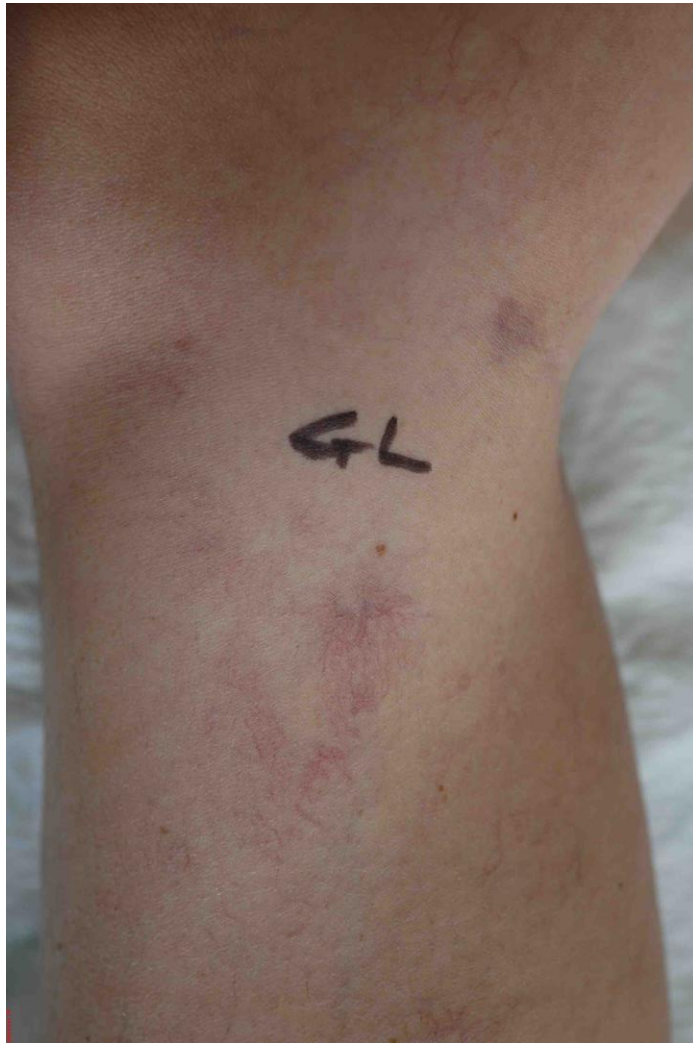START



START



START



Take home message

- **Diagnosis of Telangiectasias**
 - They are not all venous
 - Investigations (reflux?)
- **Surgery (mostly Phlebectomy)**
 - Feeder vein/perforator (any size)
 - Curettage
 - Association to sclerotherapy (START)



Thank you